

## LETTERS TO THE EDITOR

### Mediastinitis and Thoracic Empyema Caused by *Streptococcus constellatus*

**To the editor:** Streptococci that colonize the mouth and upper airways are generally considered to be commensal rather than pathogenic. In combination with anaerobics, they can be responsible for pneumonia and empyema in patients with certain predisposing factors. Mortality in such cases is high and complications frequent. We present a case of mediastinitis and thoracic empyema secondary to *Streptococcus constellatus*.

A 63-year-old man who was a moderate drinker with a history of chronic obstructive pulmonary disease and gastroesophageal reflux disease reported cough, dyspnea, odynophagia, and 39°C fever starting 6 days earlier. Physical examination revealed general malaise and crackles at the base of the right lung. Analysis revealed leukocytosis (13 500  $\mu$ L) with a left shift, a biochemical profile of cholestasis, and glycemia of 376 mg/dL. Arterial blood gas analysis showed moderate hypoxemia. Chest x-ray showed mediastinal widening with slight cardiomegaly and blunting of the right costophrenic angle. A thoracic computed tomography scan revealed right pleural effusion with perihilar alveolar infiltrates and increased upper mediastinal fat, consistent with mediastinitis (Figure). Thoracentesis revealed a purulent liquid in which *S constellatus* was isolated. A pleural drainage tube was inserted and high doses of penicillin G were administered. Clinical course was good, as the pleural effusion resolved and the mediastinal involvement disappeared.

*Streptococcus milleri* bacteria, which include *S constellatus*, play a greater role in respiratory infections than was once thought.<sup>1</sup> *S constellatus* is an oropharyngeal commensal which does not cause illness under normal conditions but can do so after intubation (endoscopy, bronchoscopy), surgery, or infection. *S milleri* can cause acute pneumonia, abscesses, and empyema.<sup>2,3</sup> Their isolation in combination with oral anaerobic bacteria indicate a synergy between these 2 groups. Mortality is then higher, with severe complications such as pulmonary abscesses, empyema, or, as in the case of our patient,

mediastinitis. Mediastinitis caused by *S milleri* without prior intubation or surgery is rare.<sup>4</sup> Esophageal perforation, cardiothoracic surgery, and head and neck infections are common causes.<sup>4,6</sup> The clinical picture includes sudden onset fever and chills followed by chest pain and dysphagia. Examination can reveal crackles and edema in the neck and chest. A chest x-ray reveals mediastinal widening, air-fluid levels, and subcutaneous emphysema. Computed tomography permits a more accurate diagnosis. If esophageal perforation is suspected, an esophagogram must be performed with an iodine contrast, which can be administered parenterally. Penicillin G is the treatment of choice given its effectiveness against anaerobic bacteria in the oral cavity. If the patient is allergic to penicillin G, vancomycin and clindamycin can be used, as can third and fourth generation quinolones. Duration of treatment depends on the virulence of the bacteria and factors concerning the host, and varies from weeks to months. Some cases of mediastinitis may need additional surgical drainage. Medical records revealed our patient had undergone an endoscopic examination several weeks before the appearance of the clinical symptoms and the mediastinal involvement and associated pleural empyema probably developed as consequences of that procedure. Thoracic drainage and penicillin G treatment cured the condition.

In conclusion, prior intubation or surgery of the airways and esophagus together with the possible oropharyngeal origin of the bacteria pathogen must be taken into account in respiratory infections in the presence of mediastinitis, pulmonary infiltrates, and pleural effusion, in order for appropriate treatment to be prescribed.

J. Ortiz de Saracho,<sup>a</sup> S. Barbancho,<sup>b</sup>  
and J.L. Mostaza<sup>c</sup>

<sup>a</sup>Unidad de Neumología, Hospital El Bierzo, Ponferrada, León, Spain.

<sup>b</sup>Medicina Familiar y Comunitaria, Hospital El Bierzo, Ponferrada, León, Spain.

<sup>c</sup>Servicio de Medicina Interna, Hospital de León, León, Spain.

1. Porta G, Rodríguez-Carballeira M, Gómez L, Salavert M, Freixas N, Xercavins M, et al. Thoracic infection caused by *Streptococcus milleri*. Eur Respir J 1998;12:357-62.

2. Shinzato T, Uema H, Inadome J, Shimoji K, Kusano N, Fukuhara H, et al. Bacteriological and clinical studies in 23 cases of thoracic empyema: the role of oral streptococci and anaerobes. Nihon Kyobu Shikkan Gakkai Zasshi 1993;31:486-91.
3. Shinzato T, Saito A. The *Streptococcus milleri* group as a cause of pulmonary infections. Clin Infect Dis 1995;21(Suppl 3):238-43.
4. Shishido H, Watanabe K, Matsumoto K, Murakami K, Sato K. Primary purulent mediastinitis due to *Streptococcus milleri*. Respiration 1997;64:313-5.
5. Chow AW. Life-threatening infections of the head and neck. Clin Infect Dis 1992;14: 991-1004.
6. Moghissi K, Pender D. Instrumental perforations of the oesophagus and their management. Thorax 1988;43:642-6.

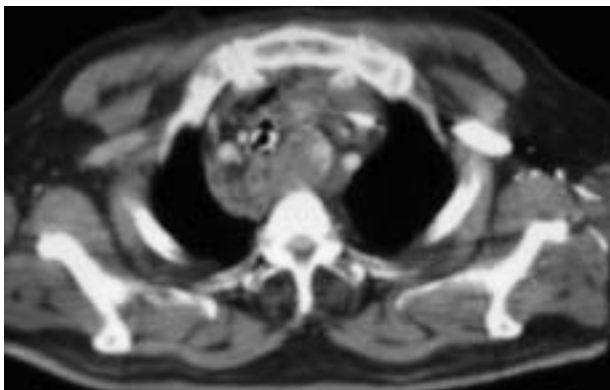


Figure. Thoracic computed tomography scan revealing mediastinal involvement.