

Utility of Bronchoalveolar Lavage in Immunocompromised Children: Diagnostic Yield and Complications

L.E. Vega-Briceño,^a N.L. Holmgren,^a P. Bertrand,^a J.I. Rodríguez,^b F. Barriga,^c I. Contreras,^a and I. Sánchez^a

^aSección de Respiratorio Pediátrico, Departamento de Pediatría, Pontificia Universidad Católica de Chile, Santiago de Chile, Chile.

^bUnidad de Cuidados Intensivos Pediátricos, Departamento de Pediatría, Pontificia Universidad Católica de Chile, Santiago de Chile, Chile.

^cSección de Oncología Pediátrica, Departamento de Pediatría, Pontificia Universidad Católica de Chile, Santiago de Chile, Chile.

OBJECTIVE: Immunocompromised children are at high risk for developing pneumonia due to opportunistic pathogens. The role of bronchoalveolar lavage (BAL) in the evaluation of such patients is still controversial.

MATERIAL AND METHOD: We reviewed the hospital records of immunosuppressed patients with respiratory symptoms who had undergone BAL in the pediatric department of the Hospital Clínico de la Pontificia Universidad Católica of Chile.

RESULTS: Sixty-eight BAL were performed on 54 children (mean age: 7.5 years) receiving wide-spectrum antibiotic treatment. The most frequent respiratory signs and symptoms were fever (90%) and cough and respiratory distress (81%); 18% had neutropenia and 43% thrombocytopenia. A specific pathogen was identified in BAL samples for 25 patients (37%). The pathogens isolated were bacteria in 21 cases, viruses in 6, *Pneumocystis carinii* in 5, fungi in 4, and *Mycobacterium tuberculosis* in one. Fourteen (19%) of the children who underwent BAL were on mechanical ventilation. Outcome was satisfactory in all cases. Twenty-one complications were recorded, 17 of which were minor (mild hypoxemia or fever) and 4 major, requiring tracheal intubation. No deaths were recorded.

CONCLUSIONS: Evaluation by fiberoptic bronchoscopy together with BAL proved to be a safe procedure with an adequate diagnostic yield that made it possible to determine the etiology of the pulmonary infiltrates seen in chest x-rays. Both positive and negative results of BAL were useful for treating the patients.

Key words: Bronchoalveolar lavage. Fiberoptic bronchoscopy. Children. Immunodeficiency.

Utilidad del lavado broncoalveolar en niños inmunodeprimidos: rendimiento y complicaciones

OBJETIVO: Los niños inmunodeprimidos presentan el riesgo de desarrollar neumonía por gérmenes oportunistas. El papel del lavado broncoalveolar (LBA) en la evaluación de estos pacientes es aún controvertido.

MATERIAL Y MÉTODO: Se revisaron las fichas de pacientes con inmunodepresión y síntomas respiratorios a los que se les había practicado un LBA en el Servicio de Pediatría del Hospital Clínico de la Pontificia Universidad Católica de Chile.

RESULTADOS: Se practicaron 68 LBA en 54 niños inmunodeprimidos (edad media: 7,5 años). Los síntomas respiratorios más frecuentes fueron fiebre (90%) y tos y dificultad respiratoria (81%); el 18% tenía neutropenia y el 43%, trombocitopenia. Todos los pacientes estaban en tratamiento antibiótico de amplio espectro. Las muestras del LBA proporcionaron un germen específico en 25 pacientes (37%). Los patógenos aislados fueron: bacterias en 21 casos, virus en 6, *Pneumocystis carinii* en 5, hongos en 4 y *Mycobacterium tuberculosis* en uno. Catorce (19%) LBA se realizaron a niños que recibían ventilación mecánica. La evolución fue satisfactoria en todos los casos. Se registraron 21 complicaciones, 17 menores (hipoxemia leve o fiebre) y 4 mayores que requirieron intubación traqueal. No se registraron muertes.

CONCLUSIONES: La evaluación fibrobronoscópica asociada a un LBA fue un método seguro, con un adecuado rendimiento, que permitió evaluar la etiología de los infiltrados pulmonares en la radiografía de tórax. Tanto los resultados positivos como los negativos del LBA contribuyeron al tratamiento de estos pacientes.

Palabras clave: Lavado broncoalveolar. Fibrobronoscopia. Niños.

Introduction

Pulmonary infections are among the most frequent causes of complications in immunocompromised patients, often presenting with atypical and nonspecific clinical and

radiographic manifestations.^{1,2} Furthermore, patients receiving immunosuppressive treatment are at greater risk for developing opportunistic infections due to pathogens such as *Pneumocystis carinii*, cytomegalovirus, *Aspergillus fumigatus*, and *Candida albicans*, among others.^{3,4}

The diagnosis of pulmonary infiltrates in immunocompromised patients remains a critical problem, as the diagnosis is often undetermined or nonspecific.^{5,6} Open lung biopsy has been established as an effective technique for diagnosing the cause of such

Correspondence: Dr. L.E. Vega-Briceño.

Sección de Respiratorio Pediátrico, Departamento de Pediatría, Pontificia Universidad Católica de Chile.

Lira, 85, 5.º piso. Laboratorio de Respiratorio. Santiago de Chile, Chile.
E-mail: LEvega@puc.cl

Manuscript received January 27, 2003. Accepted for publication March 9, 2004.

infiltrates in children, especially when they develop acute respiratory distress syndrome.⁷ However, the procedure is invasive, as it requires anesthesia, thoracotomy, and pneumotomy and is associated with significant morbidity and mortality.^{8,9}

During the last 3 decades, fiberoptic bronchoscopy (FB) has been shown to be a powerful tool for diagnosing respiratory diseases in pediatric patients.¹⁰ Bronchoalveolar lavage (BAL) is a simple technique that allows a specific diagnosis to be made, but by which samples are obtained less invasively than by biopsy.¹¹ The role of this technique, however, remains controversial for some researchers who argue that the results obtained for children do not lead to a change in their specific treatment.¹²⁻¹⁴ The objective of our study was to determine the diagnostic yield of BAL in immunocompromised children who develop respiratory symptoms and pulmonary infiltrates during hospitalization.

Material and Methods

We carried out a retrospective review of the data from all BAL procedures performed on immunocompromised patients who developed respiratory symptoms in the Pediatric Service of the Hospital Clínico of the Pontificia Universidad Católica, Santiago de Chile, Chile, between January 1993 and July 2003. In all cases there was suspicion of lung infection with chest x-rays showing the presence of some type of lung infiltrate.

The informed consent of parents was obtained for all patients. The BAL were performed either in a specially-equipped procedure room or in the pediatric intensive care unit (ICU), depending on the patient's condition. The fiberoptic bronchoscope used was an Olympus BF3C20 (Hamburg, Germany) with no suction channel. The outside diameter was 3.6 mm or larger (depending on the patient's age) to allow proper wedging. The bronchoscope was used together with a Sony DXC-C1 (Tokyo, Japan) video camera. The sedation protocol included midazolam (0.15 mg/kg/dose), morphine (0.1 mg/kg/dose), or ketamine (0.20-0.5 mg/kg/dose) and was left to the discretion of the ICU physician. Recently, propofol has been used alone, at a loading dose of 2 mg/kg followed by maintenance doses of 1 mg/kg.¹⁵ In some cases atropine (0.2 mg/kg) was used as premedication. Heart rate, respiratory rate, and arterial oxygen saturation were monitored continuously throughout this procedure. In addition, blood pressure measured noninvasively (Dinamap, Critikon Inc. Tampa, Florida, USA) was recorded every 5 minutes and immediately following each dose of propofol. A suction catheter, a self-inflating bag to help with ventilation, an endotracheal tube, and medication in the event intubation should be required were kept on hand. During bronchoscopy, heart rate, breathing rate, oxygenation level, and blood pressure were recorded. All patients received supplemental oxygen during the examination.

After intranasal administration of lidocaine 2%, the fiberoptic bronchoscope was inserted either through the nose or the endotracheal tube, depending on the patient's clinical situation. BAL was performed by instilling a volume of 1 mg/kg/aliquot of 0.9% saline solution a minimum of 3 times, with a maximum volume of 15 mL instilled each time. After bronchoscopic inspection of the site a lavage was performed either in the most affected lung segment or in the middle lobe

TABLE 1
Characteristics of the Patients Studied (n=54)*

Characteristic	No. (%) of BAL (n=68)
Sex	
Male	45 (66)
Female	23 (34)
Age, years	
<1	4 (6)
1-5	25 (37)
5-14	27 (40)
>14	10 (15)
Source	
Transferred, other hospitals	7 (10)
Same hospital	61 (90)
Clinical situation	
Respiratory distress	52 (76)
Hypoxemia	55 (81)
Mechanical ventilation	13 (19)
Previous transfusion	20 (29)
Diagnosis	
Leukemia	25 (38)
BMT	10 (16)
Primary immunodeficiency	9 (13)
Sarcoma	7 (10)
PNT	6 (9)
SLE	4 (6)
AIDS	4 (6)
Astrocytoma	2 (3)
Heart transplant	1 (1)

*BAL indicates bronchoalveolar lavage; BMT, bone marrow transplantation; PNT, primitive neuroectodermal tumor; SLE, systemic lupus erythematosus; AIDS, acquired immunodeficiency syndrome.

or lingula.¹⁰ The bronchoscope was wedged into the third or fourth generation bronchi depending on the patient's age. A sample was considered adequate when at least 30% of the instilled volume was recovered.

The samples obtained were sent immediately to the laboratory for virus culture, direct immunofluorescence, direct observation of cytomegalovirus inclusions, and immunohistochemistry; bacteriological study using quantitative cultures on chocolate agar, blood, or tryptose broth; specific testing for tuberculosis using Löwenstein-Jensen culture medium or highly-enriched Middlebrook medium, Ziehl-Neelsen staining to detect acid-fast bacilli, and polymerase chain reaction in selected cases; direct inspection for fungal infection, or by applying hematoxylin-eosin or Gomori-Grocott staining, or conventional or specific culture (agar, Sabouraud); testing for *P carinii* by direct observation with Giemsa staining, Gomori-Grocott methenamine silver staining, and/or polymerase chain reaction.

Statistical Analysis

For the statistical analysis the following were included: age, sex, underlying disease and treatment, and results of and complications arising from each BAL. When necessary, the χ^2 test was used to look for statistical associations, and a *P* value less than .05 was considered significant for establishing differences between groups.

Results

During the period from January 1993 to July 2003, a total of 806 fiberoptic bronchoscopies were performed on pediatric patients. Of these, 68 (8%) were performed

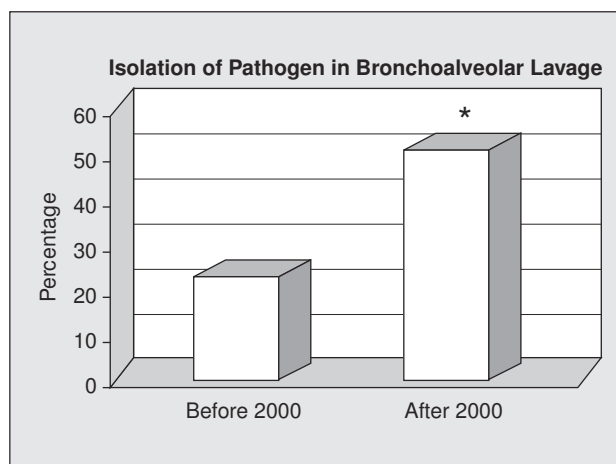


Figure. Diagnostic yield of bronchoalveolar lavage in immunocompromised children, before and after 2000. * $P < .05$.

on 54 immunocompromised patients between the ages of 1 month and 21 years (mean age, 7.5 years), with a male-to-female ratio of 2:1. In 38% of the procedures, the patient had leukemia and in 16% the patient had received some type of transplant (10 bone marrow transplants and 1 heart transplant). Table 1 shows the clinical characteristics of the children evaluated. The most frequent respiratory signs and symptoms were fever (90%), cough and respiratory distress (81%), and hypoxemia (76%). Chest x-rays, which were abnormal in all cases, showed pulmonary consolidation in 33% of

cases, interstitial infiltrates in 28%, pulmonary nodules in 4%, and other images in the rest.

Tests done before BAL showed neutropenia in 18% of cases, thrombocytopenia in 43%, and anemia in 78%. Platelet transfusion was ordered for patients whose platelet counts before the procedure were less than 50 000/ μ L. A specific pathogen was identified in BAL fluid for 25 patients (37%). The diagnostic yield (Figure) was better after the year 2000—51% compared to 21% before that year—and the difference was statistically significant ($P < .05$). Table 2 shows the clinical characteristics of those patients for whom a specific pathogen was identified. In 1 case, syncytial respiratory virus was isolated in the bronchial sample, although the nasal aspirate sample was negative.

All the patients who underwent BAL had been receiving empirical wide-spectrum antibiotic treatment since admission to our hospital. The antibiotics or other drugs most frequently used were ceftazidime/ceftriaxone, amikacin, imipenem/vancomycin, co-trimoxazole, ganciclovir, and amphotericin B (in 3 patients), and the average number of drugs used for each child was 3 (range: 2-6). Before the year 2000, 38% of the BAL were performed in the pediatric ICU because of the serious condition of the patients, 30% of whom were on mechanical ventilation. After the year 2000, however, only 14% were on mechanical ventilation.

Twenty-one (31%) complications were recorded, 17 (25%) of which were minor (moderate and/or transient hypoxemia, fever, or paradoxical agitation). A total of 4

TABLE 2
Characteristics of Patients With Positive Bronchoalveolar Lavages*

Patient	Age (Years)	Sex	Pathogen/Culture	Underlying Disease
1	16.3	M	<i>Aspergillus flavus</i> (+)	CML + BMT + GVHD
2	18.6	M	<i>Acinetobacter baumannii</i> (+), <i>Candida famata</i> (+)	PNT
3	18.3	M	<i>A baumannii</i> (+), <i>Haemophilus influenzae</i> (+)	PNT
4 [†]	11.2	M	<i>Candida albicans</i> (+)	SLE
5	4.7	M	CMV (+)	Lymphoma
6	16.6	F	CMV (+)	Histiocytosis X + BMT
7	3.2	M	CMV (+), <i>Streptococcus viridans</i> (+)	IgG deficiency
8	1.7	F	CMV (+) <i>S viridans</i> (+)	Astrocytoma
9	6.1	M	<i>H influenzae</i> (+)	ALL
10	6.8	M	<i>H influenzae</i> (+), <i>Streptococcus pneumoniae</i> (+)	AIDS
11	0.5	M	<i>Moraxella catarrhalis</i> (+), <i>C albicans</i> (+)	AIDS
12	2.4	M	<i>Mycobacterium tuberculosis</i> (+), <i>S viridans</i> (+)	PNT
13 [†]	5.5	M	<i>Pseudomonas aeruginosa</i> (+)	Neuroblastoma
14	0.2	F	<i>Pneumocystis carinii</i> (+)	Hyper-IgM
15	0.4	M	<i>P carinii</i> (+)	AIDS
16	4.1	M	<i>P carinii</i> (+)	ALL
17	8.7	M	<i>P carinii</i> (+)	CML + BMT + GVHD
18	1.2	F	<i>P carinii</i> (+) CMV (+)	ALL + BMT
19	4.7	M	VRS (+)	ALL
20	1.3	F	α -hemolytic <i>Streptococcus</i> (+)	Immunodeficiency under study
21	2	M	<i>Staphylococcus aureus</i> (+), <i>H influenzae</i> (+)	Immunodeficiency under study
22	14.2	M	<i>S aureus</i> (+), <i>S viridans</i> (+)	Medullary aplasia
23	2.3	F	<i>S viridans</i> (+), coagulase negative <i>Staphylococcus</i> (+)	AML
24	3.4	F	<i>S viridans</i> (+)	AML + BMT
25	1.5	F	<i>S viridans</i> (+)	Astrocytoma

*CMV indicates cytomegalovirus; GVHD, graft versus host disease; Ig, immunoglobulin; ALL, acute lymphocytic leukemia; AML, acute myeloid leukemia; CML, chronic myeloid leukemia; SLE, systemic lupus erythematosus; F, female; BMT, bone marrow transplantation; PNT, primitive neuroectodermal tumor; AIDS, acquired immunodeficiency syndrome; M, male; SRV syncytial respiratory virus.

[†]Patient on mechanical ventilation when fiberoptic bronchoscopy was performed.

patients developed major complications (severe hypoxemia in 2 cases, respiratory arrest in 1 case, and hemorrhage in 1 case) requiring endotracheal intubation and subsequent admission to the pediatric ICU. No deaths were recorded.

For 21 (31%) patients who underwent BAL, there was a change in antibiotic therapy, with drugs either added or withdrawn. Such a change was more frequent in the group for whom a specific pathogen had been isolated (67%). No pathogens were isolated in the remaining 43 BAL, but the patients' progressed satisfactorily during hospitalization and at least 1 antibiotic was withdrawn in 7% of the cases. The 7 patients transferred to our hospital for BAL returned to their referring hospitals within 24 hours of the procedure.

Discussion

Evaluation by FB with BAL in this series proved to be a safe procedure and had a diagnostic yield of 40%, allowing us to evaluate the possible causes of the various pulmonary infiltrates and to adopt an appropriate therapeutic approach in each of the cases. Pediatric FB, with which we now have considerable experience,^{16,17} has proven useful in the diagnosis of anatomic airway alterations, the removal of mucous plugs, the resolution of atelectasis, and the evaluation of recurrent pneumonia.^{11,18} The role of FB in immunocompromised patients, however, remains unclear for some authors.^{12,13} Strict standardization of fiberoptic bronchoscopy, including instilled and recovered BAL volumes, number of instillations, suction time and pressure, site of instillations, and finally the processing of the sample are needed in order to make comparisons between findings for a single patient or to compare different patient series.

BAL has its greatest applicability in immunocompromised hosts with bilateral, diffuse, and nonspecific infiltrates. BAL does not replace biopsy for the diagnosis of noninfectious lung disease.¹⁹ The present study evaluated the diagnostic yield of BAL in immunocompromised patients, but not its sensitivity. BAL shows a sensitivity of 47% to 58% in children on mechanical ventilation^{20,21} and up to 90% in those receiving previous antibiotic treatment, and a specificity of 45% to 100%.^{20,22} Prado et al²³ and our group²⁴ have reported diagnostic yield rates of 25% and 47%, respectively.

Pulmonary infiltrates on the chest x-rays of immunocompromised children are not always easy to interpret. Several noninfectious processes associated with cancer treatment can generate diverse radiographic patterns such as interstitial infiltrates, pulmonary nodules, pleural effusion, or condensations. In our series, there were other noncancerous diseases, like primary immunodeficiency (excess immunoglobulin E) or secondary immunodeficiency (acquired immunodeficiency syndrome [AIDS]), reflecting the heterogeneous nature of the sample. In transplant recipients, for example, it is

unclear whether pulmonary infiltrates are due to pneumonia or a graft-versus-host disease.²⁵

While lung biopsy does provide a specific diagnosis, it requires anesthesia and intubation, increasing risk. Potter et al⁸ reported a complication rate of up to 71% in ventilated patients undergoing lung biopsy. Evaluation by FB together with BAL is a less invasive option.

As our study lacked a control group, we cannot state with certainty that changes in therapeutic approach were due to the results obtained by BAL. Given the retrospective nature of the study, there was also a certain loss of information. As there was no follow up, the analysis refers only to the period of hospitalization. The introduction of new microbiological techniques as well as early bronchoscopic intervention allowed a greater diagnostic yield after the year 2000 even in patients receiving antibiotic therapy. It is important to take into consideration the negative predictive value of BAL when appropriate microbiological techniques are applied when deciding to withdraw an antibiotic such as co-trimoxazole or an antiviral agent such as ganciclovir. While it is true that the use of wide-spectrum antibiotics associated with antifungal or antiviral treatment can offer false security, it is often difficult to know when treatment should be discontinued. BAL should be performed shortly after or, better still, before beginning antibiotic therapy. Another problem is that of the contamination of the suction channel as it passes through the nasopharynx. For the above reasons, it is difficult to interpret with certainty the presence of such pathogens as *Haemophilus influenzae*, *Streptococcus pneumoniae*, and *Staphylococcus aureus*. Quantitative techniques should therefore be used and only samples with more than 100 000 colony-forming units/mL considered positive.²⁶

The true relevance of cytomegalovirus in the immunocompromised host is unknown, although it is commonly believed to be one of the most frequent causes of pneumonia in such patients. In our study, all isolations of cytomegalovirus were obtained by cultures, using the rapid centrifugation culture technique. No lung biopsies were performed due to the invasiveness of the procedure, our lack of experience with it, and the poor diagnostic yield obtained in our hospital. Uncertainty as to the presence of *C albicans* in patients infected with multiple pathogens and receiving wide-spectrum antibiotic therapy is always difficult to resolve; however, the possibility that *C albicans* is responsible for the pulmonary lesions in hosts whose condition is critical and unstable cannot be ruled out. For this reason, the term "specific isolation" is preferable to "specific diagnosis," which could introduce a dangerous bias into the interpretation of results.

The most frequent complication reported has been moderate and transient hypoxemia.^{27,28} Although 21 (31%) complications were recorded in our series, only 6% were major. It is worth noting that 20% of all BAL were performed on children receiving mechanical

ventilation, a reflection of the severity of the underlying diseases. In a recent study²⁷, major complications were observed in fewer than 2% of cases; however, this figure was for the general hospital population, not for critically ill patients. Transient fever after BAL may be due to the underlying disease, and not to a complication of the procedure. It is important to note that the complications observed in our series did not occur in a group with any specific characteristics and were, therefore, unpredictable.²⁹

In summary, BAL proved to be a minimally invasive procedure. Cultures provided adequate diagnostic yield, with no associated mortality and few major complications. Both positive and negative results contributed satisfactorily to treatment. The use of a protected catheter, quantitative microbiological techniques, and early intervention are recommended. Future prospective, controlled studies may be able to determine whether FB together with BAL can change the course of lung infiltrates in immunocompromised children.

REFERENCES

1. Williams DM, Remington JS. Pulmonary infection in the immunocompromised host. *Am Rev Resp Dis* 1976;114:259-64.
2. Park JR, Fogarty S, Brogan TV. Clinical utility of bronchoalveolar lavage in pediatric cancer patients. *Med Pediatr Oncol* 2002;39:175-80.
3. Stefanutti D, Morais L, Fournet JC, Jan D, Casanova JL, Scheinmann P, et al. Value of open lung biopsy in immunocompromised children. *J Pediatr* 2000;137:165-71.
4. Pattishall EN, Blakeslee EN, Orenstein DM. Use of bronchoalveolar lavage in immunocompromised children with pneumonia. *Pediatr Pulmonol* 1988;5:1-5.
5. Ben-Ari J, Yaniv I, Nahum E, Stein J, Samra Z, Schonfeld T. Yield of bronchoalveolar lavage in ventilated and non-ventilated children after bone marrow transplantation. *Bone Marrow Transplant* 2001;27:191-4.
6. Gross NJ. Pulmonary effects of radiation therapy. *Ann Intern Med* 1977;86:81-92.
7. Kornecki A, Shemie SD. Open lung biopsy in children with respiratory failure. *Crit Care Med* 2001;29:1247-50.
8. Potter D, Pass HI, Brower S. Prospective randomized study of open lung biopsy versus empirical antibiotic therapy for acute pneumonitis in non-neutropenic cancer patients. *Ann Thorac Surg* 1985;40:422-8.
9. Davies L, Dolgin S, Kattan M. Morbidity and mortality of lung biopsy in children. *Pediatrics* 1997;99:660-4.
10. Midulla F, de Blic J, Barbato A, Bush A, Eber E, Kotecha S, et al. Flexible endoscopy of paediatric airways. *Eur Resp J* 2003;22:698708.
11. de Blic J, Midulla F, Barbato A, Clement A, Dab I, Eber E, et al. Bronchoalveolar lavage in children. *Eur Resp J* 2000;15:217-31.
12. Feldman NT, Pennington JE, Ehrie MG. Transbronchial lung biopsy in the compromised host. *JAMA* 1997;238:1377-9.
13. Pizzo PA. Management of fever in patients with cancer and treatment induced neutropenia. *N Engl J Med* 1993;328:1323-32.
14. Ratjen F, Costabel U, Havers W. Differential cytology of bronchoalveolar lavage fluid in immunosuppressed children with pulmonary infiltrates. *Arch Dis Child* 1994;74:507-11.
15. Ronco R, Castillo A, Carrasco JA, Carrasco C, Parraguez R, Zamora M, et al. Sedación y analgesia para procedimientos pediátricos fuera del pabellón. *Rev Chil Pediatr* 2003;74:171-8.
16. Nussbaum E. Pediatric fiberoptic bronchoscopy: clinical experience with 2836 bronchoscopies. *Pediatr Crit Care Med* 2002;3:171-6.
17. Barbato A, Magarotto M, Crivello M, Novello A, Cracco A, de Blic J, et al. Use of the paediatric bronchoscope, flexible and rigid, in 51 European centres. *Eur Resp J* 1997;10:1761-6.
18. Holmgren NL, Córdova M, Ortúzar P, Sánchez I. Broncoscopia flexible en la reexpansión de atelectasias persistentes en pediatría. *Arch Bronconeumol* 2001;38:367-71.
19. Riedler J, Grigg J, Robertson CF. Role of bronchoalveolar lavage in children with lung disease. *Eur Resp J* 1995;8:1725-30.
20. Marquette CH, Copin MC, Wallet F. Diagnostic test for pneumonia in ventilated patients: prospective evaluation of diagnostic accuracy using histology as a diagnostic gold standard. *Am J Respir Crit Care Med* 1995;151:1878-88.
21. Papazian L, Thomas P, Garbe L. Bronchoscopic and blind sampling techniques for the diagnosis of ventilator-associated pneumonia. *Am J Respir Crit Care Med* 1995;152:1982-91.
22. Chastre J, Fagon JY, Bornet-Lecso M. Evaluation of bronchoscopic techniques for the diagnosis of nosocomial pneumonia. *Am J Respir Crit Care Med* 1995;152:231-40.
23. Prado F, Boza L, Badilla J, Isamitt D. Fibrobroncoscopia en pediatría: utilidad diagnóstica y terapéutica. *Rev Chil Pediatr* 1998; 69:207-14.
24. Zamorano A, Núñez A, Salinas ME, Navarro H, Holmgren L, Bertrand P, et al. Experiencia clínica de la utilidad del lavado broncoalveolar en pediatría. *Rev Chil Pediatr* 2002;73:576-82.
25. White P, Bonacum JT, Miller CB. Utility of fiberoptic bronchoscopy in bone marrow transplant patients. *Bone Marrow Transpl* 1997;20:681-7.
26. Khan FW, Jones JM. Diagnosing bacterial respiratory infection by bronchoalveolar lavage. *J Infect Dis* 1987;155:862-9.
27. de Blic J, Marchac V, Scheinmann P. Complications of flexible bronchoscopy in children: prospective study of 1328 procedures. *Eur Resp J* 2002;20:1271-6.
28. Bruce M, Schnapf DO. Oxygen desaturation during fiberoptic bronchoscopy in pediatric patients. *Chest* 1991;91:467-71.
29. Rodríguez C, Sossa MP. Factores asociados a complicaciones debidas a la realización de broncoscopia en pacientes pediátricos. *Arch Bronconeumol* 2003;39:501-6.