

Octreotide for Conservative Management of Postoperative Chylothorax

A. Gómez-Caro Andrés, C. Marrón Fernández, F.J. Moradiellos Díez, V. Díaz-Hellín Gude, J.A. Pérez Antón, and J.L. Martín de Nicolás

Servicio de Cirugía Torácica, Hospital 12 de Octubre, Madrid, Spain.

Postoperative chylothorax after lung resection is a major problem leading to morbidity and mortality and requiring reoperation in a large number of cases. The most advisable and least aggressive option is conservative management in progressive stages: a diet rich in medium-chain fatty acids and/or total parenteral nutrition, in addition to chest tube drainage. Including octreotide in this regimen seems to be related to a higher success rate without the need for surgery. We report a case in which the effectiveness and safety of octreotide in the resolution of postoperative chylothorax was excellent.

Key words: *Chylothorax. Octreotide. Conservative management.*

Tratamiento conservador con octreótido del quilotórax posquirúrgico

El quilotórax posquirúrgico tras resección pulmonar es un problema importante por su morbimortalidad y suele obligar a la reintervención en un porcentaje importante de los casos. La opción más aconsejable y menos radical es el tratamiento conservador con medidas escalonadas: dieta rica en ácidos grasos de cadena media y/o nutrición parenteral total, además de tubo de toracostomía. El uso del octreótido entre estas medidas parece estar relacionado con un índice mayor de resolución sin necesidad de un tratamiento quirúrgico. Presentamos un caso en que su efectividad e inocuidad en la resolución del quilotórax posquirúrgico fue excelente.

Palabras clave: *Quilotórax. Octreótido. Manejo conservador.*

Introduction

The incidence of chylothorax after surgery is between 0.5% and 2%,¹ and this complication is more common in congenital heart defect corrective surgery. Conservative management is currently the approach of choice, at least within 1 to 2 weeks after surgery, and consists of pleural drainage without aspiration and dietary measures—first with a diet low in fats and rich in medium-chain fatty acids (MCFA) and later total parenteral nutrition (TPN) with bowel rest. Years ago surgical intervention was considered necessary when, after 2 weeks, the amount of drainage remained above 1000 mL/d. The repair procedure depended on the likelihood of the lesion being located in the thoracic duct. Conservative management is currently complemented with various drugs that decrease the chyle leakage (somatostatin and analogs² such as octreotide,³ heparin,⁴ and etilefrine⁵).

Correspondence: Dr. A. Gómez-Caro Andrés.
Servicio de Cirugía Torácica, Hospital 12 de Octubre.
Ctra. de Andalucía, km 5,400. Madrid, España.
E-mail: ABELITOV@yahoo.es

Manuscript received January 19, 2004. Accepted for publication February 17, 2004.

Case Description

The patient was a 73-year-old man diagnosed with epidermoid (bronchogenic) carcinoma classified cT2 N2 M0 (stage cIIIA). He was treated with neoadjuvant therapy (3 cycles of cisplatin-gemcitabine), a left lower lobectomy, and standard mediastinal lymph node sampling. On the first day after surgery 2300 mL of serosanguineous exudate was drained through the chest tubes. The fluid became milky during the following 24 to 48 hours, and biochemical values were consistent with chylothorax. As the drainage continued to be greater than 2000 mL/d, it was decided to implement a diet rich in MCFA. Aspiration in both chest tubes was then disconnected.

Because leakage exceeding 2000 mL/d persisted, oral intake was suspended in order to begin TPN. Drainage remained above 2000 mL and had a serous appearance. The biochemical analysis of the exudate, triglyceride concentrations, and cholesterol were within normal ranges. Cytology of the pleural fluid revealed no evidence of malignancy. A chest x-ray (Figure) taken at a time when the patient's condition had worsened showed accumulation due to drainage obstruction, which caused hemodynamic instability. Conservative treatment had failed and withdrawal of the chest tubes was not possible due to elevated leakage; it was therefore decided to administer octreotide, an analog of somatostatin, at a subcutaneous dosage of 1 mg/8 h starting

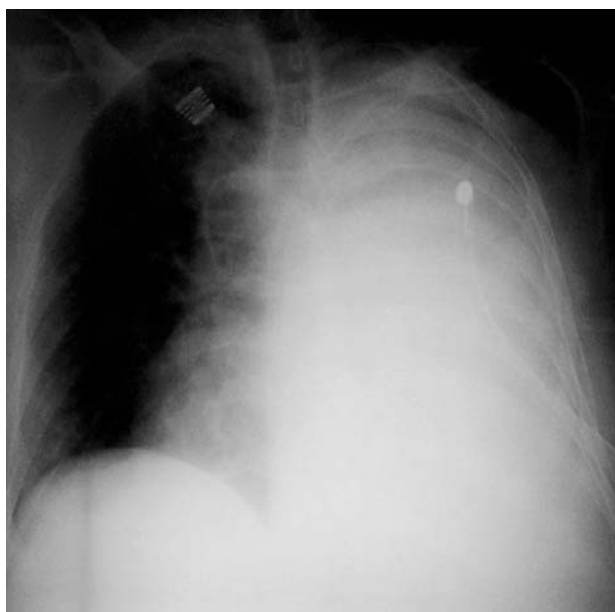


Figure. Chest x-ray of the patient with postsurgical chylothorax.

on postoperative day 15. On day 16, drainage greatly decreased (to less than 300 mL/d) and remained low throughout subsequent nutritional management for chylothorax and then a normal diet. On days 17 and 20 after surgery chest tubes were withdrawn. The patient was discharged on day 21. No symptoms were reported, and no radiographic evidence of pleural effusion was observed in follow up lasting over 6 months.

Discussion

Conservative management of chylothorax is widely recognized in the literature.^{1,2} Postoperative chylothorax is common after cardiovascular surgery and in particular after left mammary artery grafting in coronary revascularization surgery.⁶ Likewise, it is frequent following neonatal and cardiovascular surgery. The incidence is lower (approximately 1%) after lung resections due to bronchogenic carcinoma and is more common in patients undergoing pneumonectomy and neoadjuvant therapy.⁹ Some reported cases have involved a questionable association with direct surgical manipulation, such as in thoracic sympathectomy for hyperhidrosis, and mechanical ventilation may be implicated.¹⁰ Accepted conservative management of chylothorax involves measures that should be undertaken progressively and in stages.¹ Conservative management lasts 1 to 2 weeks, after which surgery continues to be recommended as the procedure of choice regardless of surgical approach.⁴

The treatment initially consists of pleural drainage and a diet rich in MCFA, later followed by TPN. However, in our recent experiences, TPN has been used from the beginning and octreotide administered for a maximum of 2 to 3 weeks before deciding to perform surgery in the

case of unresolved drainage. A diet rich in MCFA can lead to increased triglyceride and chylomicron concentrations, and water intake alone increases the drainage by 20% in certain patients. This may explain the poor resolution of chylothorax treated exclusively with MCFA.³ TPN resolves chylothorax in 77% of cases, but creates medium- and long-term problems related to increased infections, thrombosis, or cholestasis.

When surgical treatment is a difficult option, and prior conservative measures have been exhausted, a variety of drugs such as somatostatin and analogs (octreotide), etilefrine, and heparin have recently been used. Octreotide has similar activity to somatostatin, but selectivity is superior and half-life longer; octreotide also inhibits several pituitary and gastrointestinal hormones. The inhibition of serotonin and other intestinal peptides produces an increase in water absorption and intestinal transit and a decrease in pancreatic-duodenal secretion. More importantly, the resistance to splenic blood flow increases, and intestinal arteriolar flow decreases, in turn reducing lymphatic flow. Octreotide is recommended for endocrine tumors, esophageal variceal hemorrhage in portal hypertension, and reduction of lymphatic flow in chylous ascites.² The dosage of octreotide is initially 0.1 mg/8 h, which is the minimum dosage recommended for treatment of pancreatic fistula, and may reach 0.4 mg/8 h in continuous perfusion.³ However, the literature does not specifically address chylothorax in adults. In theory, drainage is withdrawn within 5 days after the start of treatment, although no contraindication for longer treatment has been reported.²

The use of either internal or external pleuroperitoneal shunts is widely accepted in the palliative treatment of refractory chylothorax.⁴ Nevertheless, when conservative measures fail, the definitive treatment is surgery: by thoracotomy or, recently, by video-assisted surgery, which has lower morbidity and mortality and a success rate of around 95%, using a thoracic or even an abdominal approach.¹ Any one of these procedures is usually combined with some type of pleurodesis.^{1,8}

Octreotide has been shown to be an effective, noninvasive treatment. It reduces the morbidity and mortality, hospital stay, and cost generated by complications of more aggressive treatment although no information regarding adverse side effects has been reported. Combining TPN and octreotide increases the rate of chylothorax resolution in children and avoids later surgical intervention, which can have a perioperative mortality rate as high as 10% in cases of postpneumonectomy chylothorax.

REFERENCES

1. Fahimi H, Casselman FP, Mariani MA, van Boven WJ, Knaepen PJ, van Swieten HA. Current management of postoperative chylothorax. *Ann Thorac Surg* 2001;71:448-51.
2. Rimensberger PC, Muller-Schenker B, Kalangos A, Beghetti M. Treatment of a persistent postoperative chylothorax with somatostatin. *Ann Thorac Surg* 1998;66:253-2.

3. Pratap U, Slavik Z, Ofoe VD, Onuzo O, Franklin RC. Octreotide to treat postoperative chylothorax after cardiac operations in children. *Ann Thorac Surg* 2001;72:1740-2.
4. Wolff AB, Silen ML, Kokoska ER, Bradley M, Rodgers BM. Treatment of refractory chylothorax with externalized pleuroperitoneal shunts in children. *Ann Thorac Surg* 1999;68:1053-7.
5. Guillem P, Billeret V, Houcke ML, Triboulet JP. Successful management of post-esophagectomy chylothorax/chyloperitoneum by etilefrine. *Dis Esophagus* 1999;12:155-6.
6. Kelly RF, Shumway SJ. Conservative management of postoperative chylothorax using somatostatin. *Ann Thorac Surg* 2000;69:1944-5.
7. le Coultre C, Oberhansli I, Mossaz A, Bugmann P, Faidutti B, Belli DC. Postoperative chylothorax in children: differences between vascular and traumatic origin. *J Pediatr Surg* 1991;26:519-23.
8. Vallieres E, Shamji FM, Todd TR. Postpneumonectomy chylothorax. *Ann Thorac Surg* 1993;55:1006-8.
9. Blanco Pérez JJ, Tábara J, Peñalver R. Quilotórax posneumonectomía. *Arch Bronconeumol* 2002;38:99-101.
10. Serra Mitjans M, Callejas Pérez MA, Rubio Garay M. Quilotórax en el postoperatorio de una simpatectomía torácica por toracoscopia. *Arch Bronconeumol* 2002;38:197-9.
11. Buettiker V, Hug MI, Burger R, Baenziger O. Somatostatin: a new therapeutic option for the treatment of chylothorax. *Intensive Care Med* 2001;27:1083-6.
12. Shapiro AM, Bain VG, Sigalet DL, Kneteman NM. Rapid resolution of chylous ascites after liver transplantation using somatostatin analog and total parenteral nutrition. *Transplantation* 1996;61:1410-1.