

Video-Assisted Thoracoscopic Thymectomy for the Treatment of Myasthenia Gravis

J. Loscertales, J. Ayarra Jarne, M. Congregado, A. Arroyo Tristán, R. Jiménez Merchán, J.C. Girón Arjona, and C. Arenas Linares

Servicio de Cirugía General y Torácica, Hospital Universitario Virgen Macarena, Sevilla, Spain.

OBJECTIVE: Traditionally, thymectomy for myasthenia gravis has been performed using either a transcervical approach or a median sternotomy. However, excision of the thymic tissue by video-assisted thoracoscopic surgery is less aggressive and recovery is faster. The aim of this study was to evaluate the usefulness and outcomes of video-assisted thoracoscopic thymectomy.

PATIENTS AND METHODS: Over the past 10 years, we have performed 25 video-assisted thoracoscopic thymectomies on patients with myasthenia gravis at our unit. This study included 16 women and 9 men, with a mean age of 48.1 years (range, 14-74 years). Right-side (22 cases) or left-side (3 cases) thoracoscopic surgery was performed, with a mean intervention time of 110 minutes (range, 60-193 minutes).

RESULTS: No patient required assisted ventilation for more than 4 hours and the maximum stay in intensive care was less than 24 hours. Complications from surgery included 3 cases of contralateral pneumothorax, 1 pleural effusion, and 2 intraoperative hemorrhages from the thymic vein, all of which were resolved by video-assisted thoracoscopy. Likewise, 3 cases required conversion (due to hemorrhaging in 2 patients and technical difficulties in 1) and 2 required a second thoracoscopic intervention. No deaths occurred and clinical outcome was excellent in 11 cases (medical treatment no longer required), good in 10 (reduced medical treatment), and poor in 4 (no changes).

CONCLUSIONS: Video-assisted thoracoscopic thymectomy is effective in the treatment of myasthenia gravis and improves patient recovery. In addition, the excellent surgical view allows the thymectomy to be performed with absolute safety.

Key words: *Myasthenia gravis. Thymectomy. Video-assisted thoracoscopy*

Timectomía videotoracoscópica para el tratamiento de la miastenia *gravis*

OBJETIVO: Tradicionalmente la timectomía en el tratamiento de la miastenia *gravis* se ha realizado por esternotomía media o transcervical; técnicamente, la cirugía videotoracoscópica permite la extirpación del tejido tímico con menor agresión quirúrgica y una recuperación temprana. El objetivo de este estudio es valorar la utilidad y los resultados de la timectomía videotoracoscópica.

PACIENTES Y MÉTODOS: En los últimos 10 años, hemos practicado 25 timectomías por videotoracoscopia en nuestro servicio a pacientes con miastenia *gravis*. Los pacientes incluidos en este estudio son 16 mujeres y 9 varones, con una edad media de 48,1 años (intervalo: 14-74). La intervención se realizó por toracosopia (derecha en 22 casos e izquierda en los 3 restantes) y tuvo una duración media de 110 min (intervalo: 60-193 min).

RESULTADOS: Ningún paciente precisó ventilación asistida durante más de 4 h y la estancia en la unidad de cuidados intensivos fue siempre menor de 24 h. En cuanto a las complicaciones de la intervención, hubo 3 casos de neumotórax contralateral, uno de derrame pleural y 2 de hemorragias intraoperatorias de la vena tímica, que se controlaron por videotoracoscopia. Asimismo, en 3 ocasiones hubo que recurrir a una conversión (en 2 por hemorragia y en la tercera por dificultades técnicas) y se practicaron 2 reintervenciones (por toracosopia). La mortalidad fue nula y los resultados clínicos excelentes en 11 casos (supresión del tratamiento médico), buenos en 10 (reducción) y regulares en 4 (sin cambios).

CONCLUSIONES: La timectomía videotoracoscópica es útil en el tratamiento de la miastenia *gravis* y tiene como ventaja una mejor recuperación del paciente. Además, ofrece una visión quirúrgica perfecta, por lo que permite realizar la timectomía con absoluta seguridad.

Palabras clave: *Miastenia gravis. Timectomía. Videotoracoscopia.*

Correspondence: Dr. J. Loscertales.
Servicio de Cirugía General y Torácica. Hospital Universitario Virgen Macarena.
Avda. Dr. Fedriani, 3. 41074 Sevilla. España.
E-Mail: jloscert@us.es

Manuscript received September 25, 2003. Accepted for publication April 26, 2004.

Introduction

Weigert,¹ the pathologist, changed the course of myasthenia gravis (MG) when he described, in 1901, the relation between thymic lesions and muscular weakness. Until then, most patients died of the disease, but

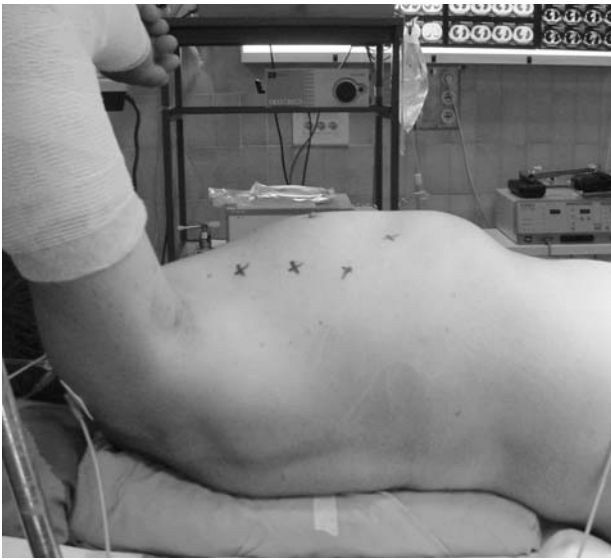

Figure 1. Position of surgical ports.

mortality rates dropped nearly 50% in the first years after Sauerbruch² began performing surgical interventions in 1912. In 1939, Blalock et al³ proposed the systematic use of thymectomy after demonstrating a clear relation between thymectomy and improvement of MG. The introduction of new techniques and specialized intensive care has improved results considerably; the death rate from the condition has fallen from 10% in the 1970s to the current rate of 0% to 2%.⁴

Thymectomy is currently indicated for all patients from puberty to 60 years of age with generalized myasthenia. Thymectomy is more effective when the lesion is caused by germinal center hyperplasia rather than thymoma. It is also more effective for patients in the early stages of the disease and those who have had the disease for less than 1 year (no more than 3 years is desirable).⁵ The role of surgery in mild forms—that is, ocular forms—is still under debate because corticosteroids are effective in these cases. However, given that 90% of mild forms progress to more advanced stages, surgery is justified. It is important to keep in mind that the effects of surgery are not immediate: improvement can take from 6 months to 3 years. Meanwhile, the patient must take medication to control the symptoms.⁵

Thymectomy involves resection of the thymus and all of the perithymic fat, which often contains ectopic

thymic tissue.⁶ In fact, the reason why most specialized centers prefer the transsternal approach to the transcervical is because the transcervical approach does not permit adequate exploration and dissection of the mediastinum, much less resection of perithymic fat in the cardiophrenic cavity; moreover, it can be especially difficult to control an unexpected hemorrhage.⁷⁻⁹

The aim of this study was to retrospectively analyze the results of video-assisted thoracoscopic thymectomy for the treatment of MG. We also describe the most significant advantages and disadvantages of thymectomy, based on our experience.

Patients and Methods

We carried out a retrospective observational study with a systematic review of patient records from the medical records department of the Hospital Universitario Virgen Macarena in Seville, Spain, for all patients who underwent a video-assisted thoracoscopic thymectomy for MG. The following parameters were recorded: preoperative Osserman classification, pre- and postoperative treatment and drug dosage, duration of surgery, intra- and postsurgical morbidity and mortality, length of stay in intensive care, need or not for mechanical ventilation after surgery, average postoperative hospital stay, and, of course, surgical outcome.

From March 1993 to May 2003 we performed 25 video-assisted thoracoscopic thymectomies on patients sent to our unit for surgical treatment of MG. Of these, 16 were female (64%) and 9 male (36%), with an average age of 48.1 years (range, 14-74 years).

Because the signs and symptoms of MG are quite varied, the diagnosis was not made at the referral hospital. In most cases, patients had to see more than 1 specialist for diagnosis. The time elapsed from symptom onset to confirmation of diagnosis and initiation of medical treatment was 8 months. The clinical stages of the patients according to the modified Osserman classification are described in Table 1.¹⁰

The following additional procedures were considered essential for the diagnosis of MG: complete standard laboratory workup; determination of complement factors; measurement of lymphocyte subpopulations, immunoglobulins, and tumor markers; conventional electromyography; edrophonium testing; and electrodiagnosis with calculation of jitter.

Posteroanterior and lateral chest x-rays were taken for all patients and provided the preliminary diagnosis in 11 cases (44%). Computed tomography (CT) scans were available for 18 (72%), magnetic resonance scan of tissues adjacent to the mediastinum for 11 (44%), and both for 4 (16%).

Preoperative drug therapy to control symptoms included the combination of pyridostigmine bromide and prednisone. Medication was stopped the day before the intervention. No patient was given immunodepressive treatment or plasmapheresis.

Surgical Technique

Under general anesthesia with selective intubation, the patient is positioned in left lateral semisupine (30°) decubitus to collapse the right lung. In the first 3 interventions, a left hemithorax approach was used. However, the presence of the aortic arch and the difficulty of managing the brachiocephalic vein—which is easily managed from the right side by

TABLE 1
Osserman Classification

Stage	Frequency	Percentage
I	4	16
IIa	5	20
IIb	10	40
III	4	16
IV	2	8
Total	25	100

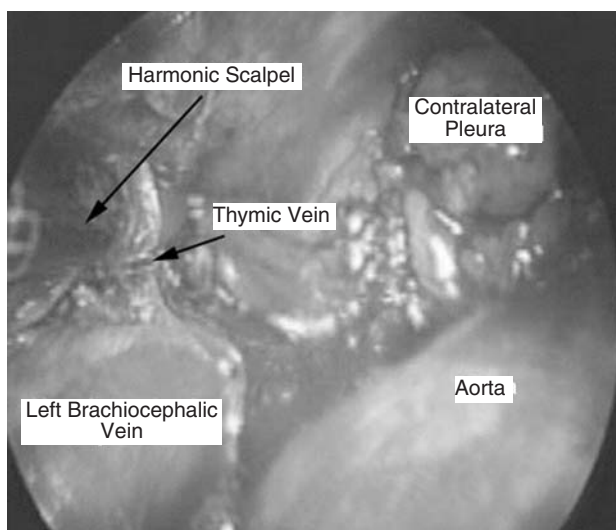


Figure 2. Section of the thymic vein with harmonic scalpel.

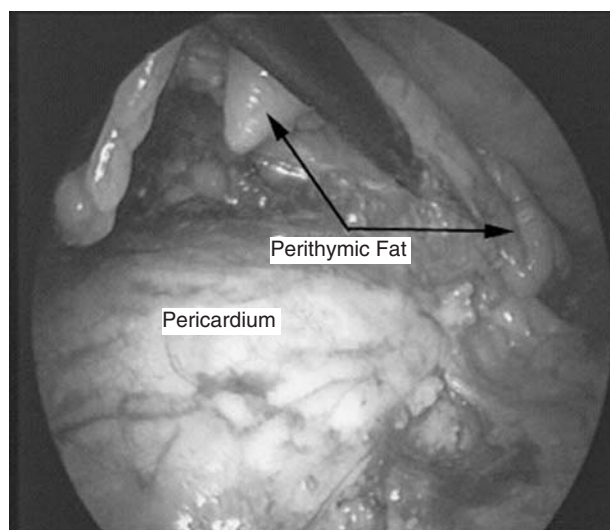


Figure 3. Resection of perithymic fat from the right cardiophrenic cavity.

following it from Pirogoff's triangle—made this approach awkward.

Four entry ports are made at the third and sixth intercostal spaces of the right posterior axillary, midaxillary, anterior, and midclavicular lines (Figure 1). In 3 patients, however, only 3 ports were made. The camera is introduced via trocar through the lower port at the sixth intercostal space of the midaxillary line, although the upper ports may also be used to make dissection of the inferior poles easier. The surgeon is positioned to the patient's right, the surgical orderly to the surgeon's right, and the 2 assistant surgeons in front. Two monitors are used, 1 on each side of the patient.

Once the thymus gland is located, a 2 or 3 cm incision is made in the mediastinal pleura medially to the phrenic nerve to avoid injuring it. Next, traction is applied to the right thymic lobe, which is first dissected from the pericardium and then from the aortic arch to the cervical vertebrae, where vessels coming from the inferior thyroid artery are secured with vascular clips. The right thymic horn is dissected—sometimes with difficulty—to the point where the superior pole ends above the brachiocephalic vein. The far end of the horn is coagulated or clipped. Once this is done, the horn is lifted and 1 or 2 thymic veins (which empty into the left brachiocephalic vein) are dissected; as dissection continues to the left, bleeding is controlled until hemostasis is achieved. In the final 7 cases we used a harmonic scalpel, which provided perfect hemostasis, whereas we had used surgical clips in the previous cases (Figure 2). Next, the inferior horn is dissected to the cardiophrenic angle and the mediastinal pleura underlying the sternum is incised to free the anterior side of the gland. Then, while monitoring the contralateral phrenic nerve closely, the same steps are repeated to free the left superior horn; this procedure is, however, somewhat more difficult given the position of the upper horn above the left brachiocephalic vein. Nonetheless, we have always been able to remove it in one piece. Once the gland has been extracted, the next step is to completely excise the perithymic fat from the pretracheal space—the area surrounding the internal mammary vessels and the pericardiophrenic angles (Figure 3)—because these areas contain ectopic thymic tissue in many cases (32%). After surveying the surgical field carefully and verifying hemostasis,

we place a chest tube in the lower port, where the camera had been. Lastly, we visually observe lung reexpansion.

Patients are transferred to the intensive care unit and moved to general care after 24 hours.

Results

In this study, we present the cases from our unit treated by video-assisted thoracoscopic thymectomy. Three patients who converted to open surgery were not included in the follow-up study. Of these, 2 required anterolateral thoracotomy due to hemorrhage, in 1 case because of injury to the brachiocephalic vein and in the second case because the clips used to ligate a thymic vein were ineffective and came loose. In the third case, a median sternotomy was necessary due to the extensive pleural adhesions, especially in the anterosuperior mediastinum. Despite the less than satisfactory outcome in 4 patients with thymoma (16% of patients) associated with MG, we have included them in this study because we believe they support our thesis that video-assisted thoracoscopic thymectomy is an excellent approach for thymus resection. In fact, only 1 of these cases required a video-assisted minithoracotomy to extract the tissue, which was 5 cm in diameter.

Twenty-five thymectomies to treat MG were performed. The average intervention time was 110 minutes (range, 60-193 minutes), although the final 8 interventions all took less than 100 minutes and the last one took only 60 minutes.

Intraoperative complications included 3 accidental incisions of the contralateral pleura resolved by a small caliber chest tube; 1 pleural effusion after removal of the intraoperative chest tube, also resolved by insertion of a new chest tube; and the 3 aforementioned conversions. Therefore, a total of 7 patients (28%) had complications. There was no intra- or postoperative (up

TABLE 2
Results of Histopathology

Histology	Frequency	Percentage
Thymic Involution	4	16
Thymus normal	8	32
Hyperplasia	8	32
Lipoma	1	4
Thymoma	1	4
Cortical thymoma	3	12
Total	25	100

TABLE 3
Reduction of Medical Treatment After Surgery
(Follow-up: 14-60 Months)

Therapeutic Modification	Frequency	Percentage
None	4	16
Reduction	11	44
Withdrawal	10	40

TABLE 4
Postoperative Osserman Classification

Postoperative Stage	Frequency	Percentage
Asymptomatic	17	68
IIa	2	8
IIb	3	12
III	1	4
IV	2	8
Total	25	100

to 30 days after the intervention) mortality.

Postoperative assisted ventilation was less than 5 hours for all patients and no patient required more than 24 hours in intensive care. The chest tube was removed 3 to 4 days after surgery and the average hospital stay, excluding those cases converted to conventional surgery, was 4.2 days (range, 3-6 days). Notably, fewer analgesics were required after thoracoscopic surgery when compared to patients treated by thoracotomy or sternotomy (the dose was as much as one third less in 13 patients and was reduced by half in 12) because oral medication was sufficient and there was no need for an epidural catheter. This decrease in postoperative pain resulted in a faster recovery than we had anticipated and a rapid return to regular activities. Only 3 patients had slight to moderate pain—managed with oral analgesics—lasting up to 5 months.

A second intervention was necessary in 2 patients after suspected thymic remnants were identified during routine CT follow up. Both underwent thoracoscopic intervention, but this time through the left hemithorax. The suspected thymic remnant, which in both cases turned out to be mediastinal fat, was dissected.

Table 2 shows results from the histologic study, with thymic hyperplasia and normal thymus being the most common findings. Postoperative changes in medical treatment (anticholinergics, corticosteroids, etc) and in Osserman classification are shown in Tables 3 and 4, respectively. Follow up ranged from 14 to 60 months. It

was necessary to reevaluate the first cases, since the effectiveness of the intervention was not, at times, apparent until 6 months to 3 years later. However, it is notable that 68% of the patients currently have no symptoms.

Discussion

The treatment of MG by thymectomy requires a clear view of the mediastinal compartment in order to fully excise the perithymic fat, which often contains ectopic thymic tissue and sometimes requires a second intervention to assure its removal.^{6,11} Median sternotomy, the classic approach, has nearly unanimous support and has long been considered the most effective approach, despite serious postoperative pain and a longer recovery period due to the degree of functional impairment and a greater need for postoperative assisted ventilation in patients with symptoms of respiratory distress or those who have had MG for a long time. Other complications inherent to this therapeutic modality include osteomyelitis, sternal dehiscence, and infections of the mediastinal space.¹²⁻¹⁴

The transcervical approach supported by some authors gives good results, but because the surgical view is limited, the possibility of leaving thymic remnants is higher. For this reason, some authors believe that this approach is only indicated to obtain thymic tissue samples for biopsy.¹⁵⁻¹⁷ Moreover, the potential of causing damage to the brachiocephalic vein during dissection of the thymic veins makes this approach inappropriate because hemostasis would be difficult to achieve.¹⁸ Combined approaches and the infrasternal mediastinoscopic approach share these disadvantages.^{19,20}

Results from maximal thymectomy, a technique that combines the transcervical and transsternal approaches to resect the mediastinal pleura, pericardium, and all of the preaortic fat, are no better. Moreover, maximal thymectomy has a higher morbidity rate.²¹

We agree with other authors that video-assisted thoracoscopic thymectomy is the optimal treatment for this disease because it provides a magnificent surgical field in a less invasive intervention with faster and better patient recovery, in addition to improved aesthetic results. Functional results are similar to open surgery.²²⁻²⁴

Although we believe that more studies are needed, outcomes of video-assisted thoracoscopic thymectomy are comparable to those achieved with any of the classic interventions. We believe—in agreement with Yim and Izzat²⁵—that thymectomy and resection of the perithymic fat can be achieved with absolute safety by video-assisted thoracoscopic thymectomy without damaging adjacent organs, and, as we have previously reported, this technique offers all the advantages of minimally invasive surgery: less pain, greater postoperative mobility, shorter hospital stay, and better aesthetic results.²³ Although we also believe that a

prudent attitude to the technique is necessary because few studies have been published and long term results may not be convincing, the studies reported to date suggest to us that median sternotomy—a technique that we have also used in previous cases or for large or invasive thymomas—provides better results in terms of effectiveness in the treatment of MG.

REFERENCES

1. Weigert C. Pathologisch-anatomischer Beitrag zur Erbschen Krankheit (myasthenia gravis). *Zentralbl Neurol* 1901;20:597.
2. Givel J-C. Historical review. In: Givel JC, editor. *Surgery of the thymus*. Berlin: Springer-Verlag, 1990; p. 1.
3. Blalock A, Mason MF, Morgan HJ, Riven SS. Myasthenia gravis and tumors of the thymic region: report of a case in which the tumor was removed. *Ann Surg* 1939;110:544-61.
4. Gronseth GS, Barohn RJ. Practice parameter: thymectomy for autoimmune myasthenia gravis (an evidence-based review): report of the Quality Standards Subcommittee of the American Academy of Neurology. *Neurology* 2000;55:7-15.
5. Ponseti JM. *Myasthenia gravis: manual terapéutico*. Barcelona: Springer-Verlag Ibérica, 1995; p. 71-2.
6. Ashour M. Prevalence of ectopic thymic tissue in myasthenia gravis and its clinical significance. *J Thorac Cardiovasc Surg* 1995;109:632-5.
7. Masaoka A, Yamakawa Y, Niwa H, Fukai I, Kondo S, Kobayashi M, et al. Extended thymectomy for myasthenia gravis patients: a 20-year review. *Ann Thorac Surg* 1996;62:853-9.
8. Mulder DG. Extended transsternal thymectomy. *Chest Surg Clin N Am* 1996;6:95-105.
9. Masaoka A. Extended trans-sternal thymectomy for myasthenia gravis. *Chest Surg Clin N Am* 2001;11:369-87.
10. Osserman KE. *Myasthenia gravis*. New York: Grune & Stratton, 1958; p. 165-83.
11. Ruckert JC, Sobel HK, Gohring S, Einhaupl KM, Muller JM. Matched-pair comparison of three different approaches for thymectomy in myasthenia gravis. *Surg Endosc* 2003;17:711-5.
12. Masaoka A. Extended trans-sternal thymectomy for myasthenia gravis. *Chest Surg Clin N Am* 2001;11:369-87.
13. Stern LE, Nussbaum MS, Quinlan JG, Fischer JE. Long-term evaluation of extended thymectomy with anterior mediastinal dissection for myasthenia gravis. *Surgery* 2001;130:774-80.
14. Jaretzki A. Thymectomy for myasthenia gravis: analysis of controversies-patient management. *Neurolog* 2003;9:77-92.
15. Bril V, Kojic J, Ilse WK, Cooper JD. Long-term clinical outcome after transcervical thymectomy for myasthenia gravis. *Ann Thorac Surg* 1998;65:1520-2.
16. Calhoun RF, Ritter JH, Guthrie TJ, Pestronk A, Meyers BF, Patterson GA, et al. Results of transcervical thymectomy for myasthenia gravis in 100 consecutive patients. *Ann Surg* 1999;230:555-9.
17. Pirskanen R, Matell G, Henze A. Results of transsternal thymectomy after failed transcervical "thymectomy". *Ann NY Acad Sci* 1987;505:866-7.
18. Hamelmann H, Thermann M. *Procedures on the mediastinum: procedures on the thymus*. Thoracic surgery. Berlin-Heidelberg: Springer-Verlag, 1989.
19. Novellino L, Longoni M, Spinelli L, Andretta M, Cozzi M, Faillace G. "Extended" thymectomy, without sternotomy, performed by cervicotomy and thoracoscopic technique in the treatment of myasthenia gravis. Infrasternal mediastinoscopic thymectomy in myasthenia gravis: surgical results in 23 patients. *Int Surg* 1994;79:378-81.
20. Uchiyama A, Shimizu S, Murai H, Kuroki S, Okido M, Tanaka M. Infrasternal mediastinoscopic thymectomy in myasthenia gravis: surgical results in 23 patients. *Ann Thorac Surg* 2001;72:1902-5.
21. Ashour MH, Jain SK, Kattan KM, Al Daef AQ, Abdal Jabbar MS, Al Tahan AR. Maximal thymectomy for myasthenia gravis. *Eur J Cardiothorac Surg* 1995;9:461-4.
22. Mack MJ, Landreneau RJ, Yim AP, Hazelrigg SR, Scruggs GR. Results of video-assisted thymectomy in patients with myasthenia gravis. *J Thorac Cardiovasc Surg* 1996;112:1352-9.
23. Loscertales J, Jiménez MR, Arenas Linares CJ, García DF, Girón Arjona JC, Congregado M. Tratamiento de la miastenia gravis mediante timentomía toracoscópica. Técnica y resultados iniciales. *Arch Bronconeumol* 1999;35:9-14.
24. Yim AP, Wan S, Lee TW, Arifi AA. VATS lobectomy reduces cytokine responses compared with conventional surgery. *Ann Thorac Surg* 2000;70:243-7.
25. Yim APC, Izzat MB. VATS approach to the thymus. In: Yim APC, Hazelrigg SR, Izzat MB, et al, editors. *Minimal access cardiothoracic surgery*. Philadelphia: W.B. Saunders Company, 2000; p. 209-20.