

Giant Thymolipoma

C. Roque, P. Rodríguez, C. Quintero, N. Santana, M. Hussein, and J. Freixinet

Servicio de Cirugía Torácica, Hospital Universitario de Gran Canaria Dr. Negrín, Las Palmas de Gran Canaria, Spain.

Thymolipoma is an uncommon benign tumor (accounting for 2% to 9% of thymus tumors). We present the case of a 26-year-old man who sought medical attention for left-sided pleural pain of 3 months duration. Computed tomography showed a mass in the left side of the chest occupying both the anterior mediastinum and the left pleural cavity. This mass caused lung collapse and mediastinal shift. Magnetic resonance imaging revealed a large fatty tumor and transthoracic biopsy with radiological guidance confirmed the diagnosis. The tumor was resected through a left thoracotomy. No postsurgical complications occurred and the histopathological diagnosis was thymolipoma.

Key words: *Thymolipoma. Mediastinum. Mediastinal tumor.*

Timolipoma gigante

El timolipoma es una neoplasia benigna poco frecuente (constituye del 2 al 9% de los tumores tímicos). Se presenta el caso de un varón de 26 años de edad que consultó por un dolor pleurítico izquierdo de 3 meses de evolución. La tomografía computarizada evidenció una masa torácica izquierda que ocupaba tanto el mediastino anterior como la cavidad pleural izquierda y provocaba un colapso pulmonar y una desviación mediastínica. La resonancia magnética puso de manifiesto una gran tumoración de origen graso y la biopsia transtorácica con control radiológico confirmó su etiología. Se intervino al paciente mediante toracotomía izquierda y se realizó una exéresis en bloque de la tumoración. El curso clínico postoperatorio transcurrió sin complicaciones y el diagnóstico histopatológico fue de timolipoma.

Palabras claves: *Timolipoma. Mediastino. Tumor de mediastino.*

Introduction

Thymolipoma is an uncommon benign tumor of the anterior mediastinum.¹ The cause is disputed, but the most accepted theory of pathogenesis is replacement of the thymus by mature adipose tissue. The tumor grows slowly and can become large. Although most patients with a thymolipoma are asymptomatic, local nonspecific symptoms may present or the tumor may be associated with parathymic syndromes such as myasthenia gravis, hyperthyroidism, lymphangiomas, aplastic anemia, chronic lymphocyte leukemia, and Hodgkin disease.² The tumor may resemble cardiomegaly in a chest x-ray and is difficult to distinguish from other mediastinal tumors.

We describe an adult who presented with left-sided pleural pain with a long duration and x-ray findings indicative of cardiomegaly, but the definitive diagnosis was giant thymolipoma.

Case Description

A 26-year-old man with no prior medical history of interest was transferred to the emergency room with left-sided pleural pain of 3 months duration but no other associated symptoms. The only finding of interest in the physical examination was the complete absence of vesicular breath sounds in the left side of the chest. The laboratory findings were normal.

Simple posteroanterior chest x-ray identified a large mass in the left side of the chest, located in the pleural cavity and anterior mediastinum. The initial diagnosis was cardiomegaly.

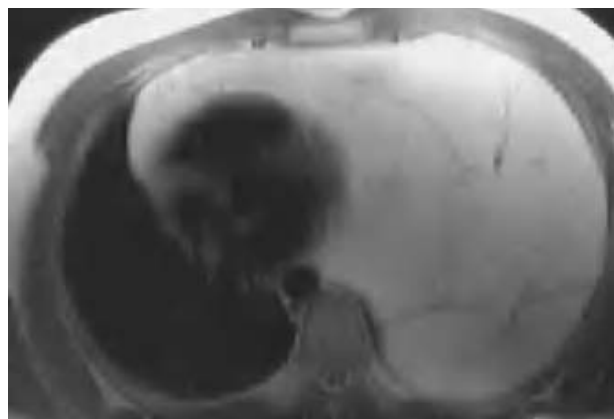


Figure 1. Chest magnetic resonance image showing a large mass in left side of the chest. The mass is isointense to fat and occupies the pleural cavity and the anterior mediastinum, causing complete collapse of the lung.

Correspondence: Dr. P. Rodríguez.
Servicio de Cirugía Torácica. Hospital Universitario de Gran Canaria Dr. Negrín.
Barranco de la Ballena, s/n. 35010 Las Palmas de Gran Canaria. Las Palmas. España.
E-mail: prosu2001@yahoo.es

Manuscript received September 2, 2004. Accepted for publication September 20, 2004.

Computed tomography showed a mass of 20 21 18 cm that occupied the entire left side of the chest. The mass had laterally shifted the mediastinum and collapsed the lung in the uppermost region of this side of the chest. No signs of invasion of neighboring structures were observed. In magnetic resonance scans, the mass was isointense to adipose tissue in the T1-weighted sequences and signal was suppressed in fat saturation sequences (Figure 1).

Biopsy done under radiological guidance revealed mature adipose tissue.

The patient underwent surgery in which the tumor was resected through a left anterolateral thoracotomy (Figure 2).

Pathological examination of the resected block confirmed diagnosis of thymolipoma. The mass measured 30 25 9 cm and weighed 3300 g.

The patient's recovery was satisfactory, and he was discharged 10 days after the operation.

Discussion

Thymolipoma is an uncommon benign neoplasm that accounts for 2% to 9% of thymic tumors.³ The incidence is the same in men and women and onset can occur at any age. It is also known as lipoma of the thymus, benign thymoma, thymolipomatous hamartoma, lipothymoma, and mediastinal lipoma. According to our review of the literature, its incidence is approximately 0.12 cases per 100 000 inhabitants per year.⁴ Several theories of the pathogenesis of this tumor have been proposed, but replacement of diffuse thymic hyperplasia by adipose tissue seems to be the most widely accepted explanation.⁵

Thymolipoma may present as an asymptomatic tumor that does not affect adjacent structures, and so large sizes can be reached before diagnosis. When such tumors grow in the left side of the chest, images may resemble cardiomegaly, as occurred in the case reported here. Approximately half of the patients with this tumor experience symptoms such as dyspnea, chest pain, and weight loss,⁴ and myasthenia gravis is present in up to 10% of the cases. Other related autoimmune diseases are systemic erythematosus lupus, hypogammaglobulinemia, Graves disease, and erythroblastopenia.⁶

The weight of these tumors, according to our review of the literature,⁷ ranges from 154 g to 6000 g; in our case, the tumor weighed more than 3000 g, and measured 30 25 9 cm.

Thymolipomas are characterized by mesodermal (fat) and endodermal (thymic epithelium) elements. They appear as lobulated well-encapsulated tumors with septal divisions, as we saw in our case. Large lobes of mature adipose tissue are interspersed with small areas of thymic tissue.⁸

These tumors are often confused with cardiomegaly in a simple x-ray, as happened in our case.⁹ To differentiate thymolipoma from lipoma, thymic hyperplasia, and liposarcoma, computed tomography or

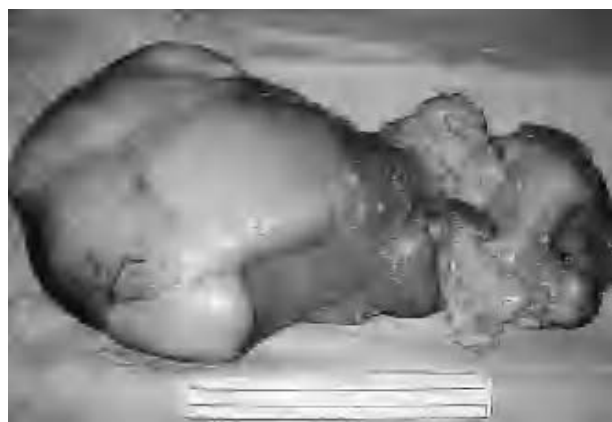

Figure 2. Photograph of the resected block: thymolipoma.

magnetic resonance imaging of the chest is needed. In T1-weighted magnetic resonance images, the adipose tissue of the tumor appears isointense and in the T2-weighted sequences, adipose tissue appears suppressed whereas the remains of thymic tissue are enhanced.

Although diagnosis can be established by imaging, a biopsy might be needed to confirm the histology of the tumor.

The only curative treatment is surgical resection of the tumor. Many authors prefer medial sternotomy to approach the tumor,⁸ but we opted for anterolateral thoracotomy because the tumor was benign and showed no signs of invasion in the x-ray, and because it might have spread to the other side of the chest through the mediastinum. In any case, if technical difficulties had arisen, we could have extended the chest incision to a transsternal bilateral thoracotomy known as the clamshell technique.

REFERENCES

1. Tindall H, Tandon AP, Ionescu MI. An unusual case of chest pain and cardiomegaly. *Br J Clin Pract.* 1990;44:766-7.
2. Mc Manus KG, Allen MS, Trastek VF. Lipothymoma with red cell aplasia, hypogammaglobulinemia and lichen planus. *Ann Thorac Surg.* 1994;58:1534-6.
3. Fenniche S, Maalej S, Hassene H. Unusual presentation of giant thymolipoma. *Tunis Med.* 2003;81:59-62.
4. Gamondes JP, Balawi A, Greenland T. Seventeen years of surgical treatment of thymoma: factors influencing survival. *Eur J Cardiothorac Surg.* 1991;5:124-31.
5. Argani P, Rosai J. Thymoma arising with a thymolipoma. *Histopathology.* 1998;32:5568-78.
6. Wang Y, Sun Y, Zhang J. Diagnosis, treatment and prognosis of thymoma: an analysis 116 cases. *Chin Med J.* 2003;116:1187-90.
7. Benton C, Gerard P. Thymolipoma in a patient with Graves' disease: case report and review of the literature. *J Thoracic Cardiovasc Surg.* 1996;51:428.
8. Shields TW, Robinson PG. Mesenchymal tumors of the mediastinum. In: Shields TW, editor. *General thoracic surgery.* Vol. 2. Philadelphia: 2000; p. 2357-423.
9. Yeh H, Gordon A, Kirschner PA, et al. Computed tomography and sonography of thymolipoma. *AJR Am J Roentgenol.* 1983;140: 1131.