

## Endothelial Dysfunction in Pulmonary Hypertension

J.C. Caraballo Fonseca, C.D. Martínez Balzano, and R. Sánchez de León

Sección de Fisiología Respiratoria, Facultad de Medicina, Escuela de Medicina Luis Razetti, Universidad Central de Venezuela, Caracas, Venezuela.

Pulmonary hypertension (PH) is a heterogeneous disease characterized by a pulmonary arterial pressure of more than 20 mm Hg at rest or 30 mm Hg during exercise that is usually due to an increase in pulmonary vascular resistance and in its later stages leads to heart failure. It occurs in 2 forms: primary and secondary. While the cause of primary PH is not fully understood, secondary PH is known to occur with a variety of diseases, such as chronic thromboembolism, collagen vascular diseases, mitral valve disease, vasoconstriction due to hypoxia, infection with the human immunodeficiency virus, and certain drugs (anorexiant).<sup>1</sup> All types of PH, both primary and secondary, have similar clinical manifestations.

Primary PH has a prevalence of 1 case per 1 000 000 individuals and is more common in women than men (a 1.7 to 1 ratio).<sup>2</sup> It is often hereditary and can affect multiple members of the same family; in this case it is known as familial primary PH. Cases in which there is no evidence of family history of the disease are classified as sporadic or nonfamilial primary PH. Primary PH is normally diagnosed in advanced stages, since earlier symptoms are nonspecific; consequently, the detailed natural history of the disease remains unknown. Patient survival ranges from 6 months to 3.5 years after diagnosis, depending on the New York Heart Association (NYHA) functional classification. The majority of patients die as a result of heart failure and sudden death.<sup>2</sup>

The pathophysiology of PH largely depends upon whether it is primary or secondary. Primary PH has traditionally been thought to develop in response to an as yet unidentified defect that leads to an imbalance between the different vasoactive agents that act on the smooth muscle of the pulmonary vasculature. This imbalance leads to a predominance of vasoconstriction, the consequence of which is an increase in vascular resistance and, therefore, pulmonary arterial pressure. In the long term, morphological changes in the arterial wall occur (Figure). It is well known that the endothelium is

responsible for the production of these vasoactive agents, which act on the medial layer of the arteries. Consequently, any alteration in these mediators must be a product of altered endothelial function. Vascular remodeling is almost identical in primary and secondary PH. It is characterized by proliferation of the medial layer, thickening of the intimal layer, and the formation of plexiform lesions, which constitute a mass of disorganized vessels containing proliferating endothelial cells, myofibroblasts, and smooth muscle cells. In primary PH, these lesions are more commonly found in the small arteries and arterioles, along with obstructive

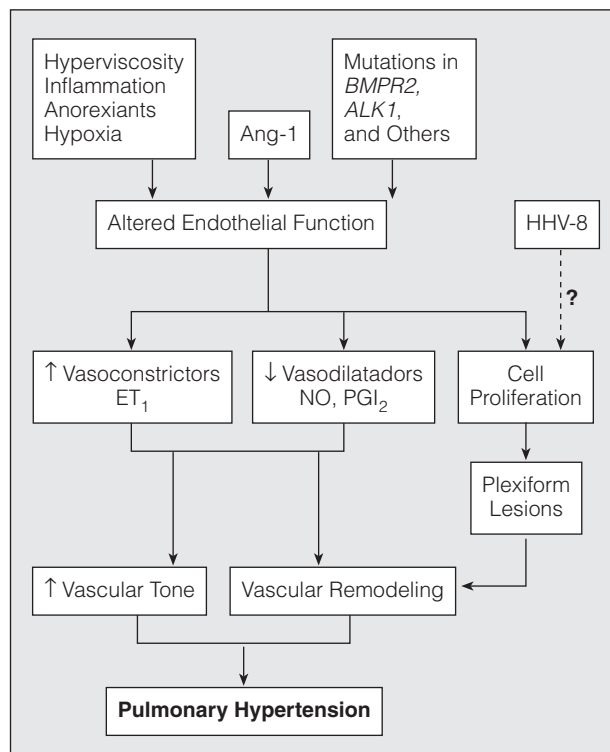


Figure. Flow chart showing the pathophysiology of pulmonary hypertension. Endothelial dysfunction and the resulting imbalance in vasoactive substances that this generates are central to the pathophysiology of primary pulmonary hypertension. Ang-1 indicates angiotensin-1; ET<sub>1</sub>, endothelin-1; NO, nitric oxide; PGI<sub>2</sub>, prostacyclin; HHV-8, human herpesvirus type 8.

Correspondence: Dr. R. Sánchez de León.  
POBA international #1-20312, Miami, Florida 33102-5255, USA.  
E-mail: rsdl@telecel.net.ve

Manuscript received August 24, 2004. Accepted for publication October 18, 2004.

intimal thickening.<sup>2,3</sup> In the primary disease, plexiform and concentric lesions contain a monoclonal population of endothelial cells; however, this is not the case in secondary PH.<sup>4</sup> This suggests that there may be a genetic alteration in these cells that leads to their proliferation in primary PH. Humoral signals arising from these defective endothelial cells would be responsible for the altered vascular tone and the development of the characteristic pathology of primary PH. However, it is also possible that these lesions represent an inappropriate response of the vasculature to increased pressure.

The genetics of familial primary PH have been extensively studied and an autosomal dominant pattern of inheritance has been observed. The disease is manifested in 10% to 20% of individuals who carry the mutation and, in addition, each new generation of carriers manifests the disease at an earlier age, a finding that is consistent with the phenomenon of genetic anticipation.<sup>5</sup> The mutation responsible for many cases of familial primary PH has been localized to the 2q31-q32 locus<sup>6,7</sup> in the gene that codes for bone morphogenetic protein receptor type II (BMPRII).<sup>8,9</sup> This gene encodes a receptor for proteins of the transforming growth factor beta (TGF- $\beta$ ) superfamily, which contains both TGF- $\beta$  itself and the bone morphogenetic proteins (BMPs). These growth factors regulate the differentiation and apoptosis of many cell types, including vascular smooth muscle, mainly by inhibiting growth and proliferation. Consequently, BMPRII dysfunction would interfere with the antiproliferative signal provided by TGF- $\beta$  superfamily members in the smooth muscle of the pulmonary vasculature and would, therefore, contribute to the alterations observed in the medial layer in primary PH.<sup>10</sup> Mutations have also been described in the gene *ALK1*, which codes for the type I TGF- $\beta$  receptor, in individuals with PH and hereditary hemorrhagic telangiectasia.<sup>11</sup> Nevertheless, there are many cases of familial primary PH in which mutations have not been identified in either of these 2 genes, indicating the existence of other mechanisms, probably involving mutations in genes associated with the TGF- $\beta$  superfamily, such as the Smads, proteins responsible for intracellular signaling downstream of BMPRII. It is likely that these mutations, along with many others that remain to be characterized, not only have a direct effect on the response of the smooth muscle to growth factors such as TGF- $\beta$  but also make the tissue more susceptible to paracrine signals from an endothelium that itself is altered, largely as a result of genetic defects. This would trigger a series of events that would culminate in the establishment of PH and vascular remodeling.

One of the most important vasoactive agents implicated in PH is endothelin-1 (ET<sub>1</sub>), the most potent vasoconstrictor identified to date.<sup>12</sup> ET<sub>1</sub> is a 21-amino acid peptide produced by the endothelium that acts through its receptors ETA and ETB to activate voltage-dependent Ca<sup>2+</sup> channels. Under normal conditions, ET<sub>1</sub>

is secreted in limiting quantities by the pulmonary vasculature. Patients with PH, however, have a clearly increased production of ET<sub>1</sub><sup>13</sup> that is directly correlated with the severity of the disease and the extent of development of plexiform lesions; thus, functional alteration of the endothelium would generate a larger amount of ET<sub>1</sub> and this increased production would be largely responsible for the increase in pulmonary vascular resistance through its action as a potent vasoconstrictor. In addition, ET<sub>1</sub> is linked to the induction of vascular remodeling by causing an increase in the expression of the serotonin 1B receptor in vascular smooth muscle cells.<sup>14</sup> This is supported by the beneficial effects of treatment with ET<sub>1</sub>-receptor antagonists, such as bosentan and sitaxsentan. Studies that have considered groups of PH patients in different NYHA functional classes subjected to short-term and long-term treatment with bosentan have provided very encouraging results, with a clear clinical improvement and a slight remission of vascular remodeling.<sup>15-17</sup> This demonstrates the importance of ET<sub>1</sub> in the pathophysiology of hypertension and, it would seem, the process of vascular remodeling in PH.

Various authors have attempted to relate certain pathophysiologic events common to the majority of patients with nonfamilial PH in a basic scheme to explain the development of the disease.<sup>18,19</sup> Thus, angiopoietin-1 (Ang-1), a hormone secreted during embryonic vascular development that is not normally detected in adult life, is found at increased levels in the blood of patients with primary PH and the level is known to be directly proportional to the clinical severity of the disease. These same patients display enhanced phosphorylation of the TIE-2 receptor, a receptor for Ang-1 that is exclusively expressed in endothelial cells, and reduced expression of the BMPRII receptor; patients with familial primary PH also have reduced levels of BMPRII due to the fact that the defective BMPRII has a tendency to dimerize with it. It has been demonstrated in vitro that these effects are directly attributable to Ang-1, and in vivo Ang-1 induces muscular hyperplasia in the pulmonary arterioles.<sup>19</sup> That study showed that Ang-1 acts via TIE-2 signaling to promote endothelial release of serotonin, a potent stimulator of growth in the smooth muscle cells that form the medial layer of blood vessels; this growth is not observed when serotonin receptors are blocked. Furthermore, serotonin levels are increased in the intimal and medial layers of the pulmonary arteries of patients with PH but not in healthy subjects, in whom the expression levels are very low. These findings suggest that defective production of Ang-1 could also be one of the pathophysiologic events that are important in PH, be it a constitutive defect, a defect caused by external factors, or perhaps a combination of the two.

Nitric oxide (NO) is another vasoactive agent synthesized by the endothelium that has been linked to the pathophysiology of PH as a result of its important role as a vasodilator. It is synthesized from L-arginine

by NO synthase, which exists in 3 isoforms: an isoform, expressed mainly by macrophages, another isoform expressed by neurons, and an endothelial form. Endothelial NO synthase (eNOS) is dependent on calcium and is widely expressed in the pulmonary endothelium of healthy individuals. Its action has been implicated in the maintenance of low resistance in the pulmonary vascular circuit<sup>20</sup> and its metabolism is clearly altered in patients with PH. NO acts through cyclic guanosine monophosphate (cGMP) to regulate potassium channels. Sildenafil, an inhibitor of type 5 cGMP-specific phosphodiesterase, has been beneficial in the treatment of PH and has even been used as a substitute for the subcutaneous prostacyclin analog treprostinil in the treatment of a case of PH associated with lupus erythematosus.<sup>21</sup> The metabolism of NO is altered in patients with PH, as shown by reduced levels of eNOS in lung tissue from patients with the disease.<sup>22</sup> There is a consequent reduction in the production of NO, the extent of which is directly correlated with the degree of vascular resistance and the clinical stage of the disease. This supports the possibility that the main vasodilator that is reduced in PH is NO.

The link between NO and pulmonary hypertension has traditionally been accepted. However, recent evidence has indicated that plexiform lesions have increased expression of eNOS, leading to the hypothesis that there is a compensatory mechanism associated with increased vascular tone in PH. Paradoxically, increased expression of the enzyme is not always accompanied by a concomitant increase in NO production.<sup>23</sup> In addition, levels of inducible NO synthase, which had not been studied previously, were revealed in this study to be increased in the plexiform lesions of patients with PH, probably in relation to shear stresses. This study was limited by the fact that immunohistochemical methods can demonstrate increased expression of a protein but not its degree of activation, thereby leaving doubts over whether the endothelium expresses a defective form of the enzyme, probably as a result of a mutation, that triggers defective production by the endothelium and a consequent deficiency in the medial layer of the vessels that would permit a predominant effect of vasoconstrictors such as ET<sub>1</sub>.

Another important vasoactive agent that could be affected in a dysfunctional endothelium is prostacyclin, which has also been studied in relation to the pathophysiology of PH. Prostacyclin is the principal arachidonic acid metabolite released by the endothelium and possesses both vasodilatory and antiplatelet effects. In normal lungs, prostacyclin synthase is expressed at higher levels in the larger pulmonary vessels and at lower levels in the arterioles and small caliber vessels. This characteristic pattern of expression seems to be exaggerated in patients with PH, probably because the arterioles of these individuals have a greater number of plexiform lesions and more marked endothelial alteration. Consequently, enhanced vasoconstriction and a tendency towards coagulation is seen in these vessels,<sup>24</sup>

favoring the chronic thromboembolism present in some patients with PH. The use of prostacyclin (epoprostenol) is currently the most effective treatment for the management of these patients, particularly those in high-risk states. Inhaled iloprost, a stable analog of prostacyclin, has been used to treat secondary PH occurring as a result of chronic thromboembolism in which surgery has been rejected. The results obtained are better than with traditional treatment,<sup>25</sup> not only due to its vasodilatory effects but also to its antiplatelet activity.

Another field of investigation in PH is focused on potassium channels. Comparison of the functionality of these channels in smooth muscle cells from the pulmonary arteries of patients with primary and secondary PH has shown that the potassium channels of cells from patients with primary PH have reduced function.<sup>26</sup> This indicates that the smooth muscle would show an enhanced response to vasoconstrictors released by the endothelium, since they would generate a higher membrane potential and an increased cytoplasmic calcium concentration. This would play a central role in vasoconstriction and could possibly act as a stimulus for hyperplasia and hypertrophy of the vascular smooth muscle in primary PH.

Very recently, Cool et al<sup>27</sup> used immunohistochemical methods to demonstrate the presence of human herpesvirus type 8 (HHV-8), a vasculotropic virus implicated in Kaposi's sarcoma, in the lung tissue of 10 patients with primary PH but not in patients with secondary PH. A clear association was found between this virus and primary PH. These interesting findings suggest that HHV-8 infection of the lungs could be a factor that contributes to the monoclonal expansion of endothelial cells and the somatic mutations present in the plexiform lesions of patients with primary PH that would lead to altered endothelial function and, from this point, all of the alterations that favor establishment of the disease.

Despite these findings relating to the etiopathology of primary PH, there still remains much to be understood in terms of the pathophysiology. Nevertheless, the characterization of the pathophysiologic process advances further each day and will lead to new therapeutic options. In reality, endothelial dysfunction is the central pathophysiologic event in primary PH, since all of the implicated processes are either a cause or a consequence. Due to the central role of the endothelium in the regulation of vascular tone, any factor that affects it and its release of vasoactive agents will also affect vascular resistance and, consequently, be a cause of PH. The discovery of the genetic, humoral, and even viral processes that can play an important role in establishing endothelial dysfunction gives us an idea of the complexity of the pathogenesis of this disease and the heterogeneity of the mechanisms involved, all of which make primary PH an incurable and difficult to treat disease. It is hoped that the advances in scientific research in this field will help to resolve this situation.

## REFERENCES

1. Barberà J. Nueva nomenclatura y clasificación de la hipertensión pulmonar. *Arch Bronconeumol*. 2002;38 Supl 1:3-9.
2. Rich S, editor. Primary pulmonary hypertension. Executive summary from the World Symposium on Primary Pulmonary Hypertension. *Evian*; 1998.
3. Yi E, Kim H, Ahn H, Strother J, Morris T, Masliah E, et al. Distribution of obstructive intimal lesions and their cellular phenotypes in chronic pulmonary hypertension. A morphometric and immunohistochemical study. *Am J Respir Crit Care Med*. 2000;162:1577-86.
4. Lee S, Shroyer K, Markham N, Cool C, Voelkel N, Tudor R. Monoclonal endothelial cell proliferation is present in primary but not secondary pulmonary hypertension. *J Clin Invest*. 1998;101:927-34.
5. Lloyd J, Butler M, Foroud T, Conneally P, Phillips J, Newman J. Genetic anticipation and abnormal gender ratio at birth in familial primary pulmonary hypertension. *Am J Respir Crit Care Med*. 1995;152:93-7.
6. Nichols W, Koller D, Slovis B, Foroud T, Terry V, Arnold N, et al. Localization of the gene for familial primary pulmonary hypertension to chromosome 2q31-32. *Nat Genet*. 1997;15:277-80.
7. Morse J, Jones A, Barst R, Hodge S, Wilhelmsen K, Nygaard T. Mapping of familial primary pulmonary hypertension locus (PPH1) to chromosome 2q31-q32. *Circulation*. 1997;95:2603-6.
8. Newman J, Wheeler L, Lane K, Loyd E, Gaddipati R, Phillips J, et al. Mutation in the gene for bone morphogenetic protein receptor II as a cause of primary pulmonary hypertension in a large kindred. *N Engl J Med*. 2001;345:319-24.
9. Thomson J, Machado R, Pauciulo M, Morgan N, Humbert M, Elliott G, et al. Sporadic primary pulmonary hypertension is associated with germline mutations of the gene encoding BMPRII, a receptor member of the TGF-beta family. *J Med Genet*. 2000;37:741-5.
10. Morrell N, Yang X, Upton P, Jourdan K, Morgan N, Sheares K, et al. Altered growth responses of pulmonary artery smooth muscle cells from patients with primary pulmonary hypertension to transforming growth factor-beta and bone morphogenetic proteins. *Circulation*. 2001;104:790-5.
11. Trembath R, Thomson J, Machado R, Morgan N, Atkinson C, Winship I, et al. Clinical and molecular genetic features of pulmonary hypertension in patients with hereditary hemorrhagic telangiectasia. *N Engl J Med*. 2001;345:325-34.
12. Yanagisawa M, Kurihara H, Kimura S, Goto K, Masaki T. A novel peptide vasoconstrictor, endothelin, is produced by vascular endothelium and modulates smooth muscle Ca<sup>2+</sup> channels. *J Hypertens Suppl*. 1988;6:88-91.
13. Giaid A, Yanagisawa M, Langleben D, Michel R, Levy R, Shennib H, et al. Expression of endothelin-1 in the lungs of patients with pulmonary hypertension. *N Engl J Med*. 1993;328:1732-9.
14. Rondelet B, van Beneden R, Kerbaul F, Motte S, Fesler P, McEntee K, et al. Expression of the serotonin 1b receptor in experimental pulmonary hypertension. *Eur Respir J*. 2003;22:408-12.
15. Channick R, Simonneau G, Sitbon O, Robbins I, Frost A, Tapson V, et al. Effects of the dual endothelin-receptor antagonist bosentan in patients with pulmonary hypertension: a randomised placebo-controlled study. *Lancet*. 2001;358:1119-23.
16. Sitbon O, Badesch D, Channick R, Frost A, Robbins I, Simonneau G, et al. Effects of the dual endothelin receptor antagonist bosentan in patients with pulmonary arterial hypertension: a 1-year follow-up study. *Chest*. 2003;124:247-54.
17. Galie N, Hinderliter A, Torbicki A, Fourme T, Simonneau G, Pulido T, et al. Effects of the oral endothelin-receptor antagonist bosentan on echocardiographic and doppler measures in patients with pulmonary arterial hypertension. *J Am Coll Cardiol*. 2003;41:1380-6.
18. Du L, Sullivan C, Chu D, Cho A, Kido M, Wolf P, et al. Signaling molecules in nonfamilial pulmonary hypertension. *N Engl J Med*. 2003;348:500-9.
19. Sullivan C, Du L, Chu D, Cho A, Kido M, Wolf P, et al. Induction of pulmonary hypertension by an angiotensin II/TIE2/serotonin pathway. *Proc Natl Acad Sci USA*. 2003;100:12331-6.
20. Dinh-Xuan A, Higenbottam T, Clelland C, Pepke-Zaba J, Cremona G, Butt A, et al. Impairment of endothelium-dependent pulmonary-artery relaxation in chronic obstructive lung disease. *N Engl J Med*. 1991;324:1539-47.
21. Cea-Calvo L, Escribano P, Tello R, Gómez M, Delgado J, Sáenz C. Sildenafil como sustituto de la prostaciclina subcutánea en la hipertensión pulmonar. *Arch Bronconeumol*. 2003;39:476-7.
22. Giaid A, Saleh D. Reduced expression of endothelial nitric oxide synthase in the lungs of patients with pulmonary hypertension. *N Engl J Med*. 1995;333:214-21.
23. Berger R, Geiger R, Hess J, Bogers A, Mooi W. Altered arterial expression patterns of inducible and endothelial nitric oxide synthase in pulmonary plexogenic arteriopathy caused by congenital heart disease. *Am J Respir Crit Care Med*. 2001;163:1493-9.
24. Tudor R, Cool C, Geraci M, Wang J, Abman S, Wright L, et al. Prostacyclin synthase expression is decreased in lungs from patients with severe pulmonary hypertension. *Am J Respir Crit Care Med*. 1999;159:1925-32.
25. Roig V, Herrero A, de la Torre N, Hernández E, Aller J, Cabello J. Iloprost en la hipertensión pulmonar tromboembólica crónica. *Arch Bronconeumol*. 2004;40:326-8.
26. Yuan J, Aldinger A, Juhaszova M, Wang J, Conte J, Gaine S, et al. Dysfunctional voltage-gated K<sup>+</sup> channels in pulmonary artery smooth muscle cells of patients with primary pulmonary hypertension. *Circulation*. 1998;98:1400-6.
27. Cool C, Rai P, Yeager M, Hernández-Saavedra D, Serls A, Bull T, et al. Expression of human herpesvirus 8 in primary pulmonary hypertension. *N Engl J Med*. 2003;349:1113-22.