

## LETTERS TO THE EDITOR

### Pulmonary Infiltrates After Initiation of Treatment with Infliximab for Adult Still's Disease

#### To the editor:

The first line of treatment for adult Still's disease is methotrexate, administered orally both as monotherapy and in combination with second-line drugs (sulfasalazine or hydroxychloroquine) or, finally, with agents that block the action of tumor necrosis factor (TNF) such as infliximab or etanercept and more recently adalimumab. TNF- $\alpha$  is a proinflammatory cytokine that is believed to be a mediator in the pathophysiology of pulmonary fibrosis. Therefore drugs in the last group have been trialed as possible treatments for patients with pulmonary fibrosis associated with rheumatoid arthritis.<sup>1</sup> Paradoxically, and exceptionally, some patients with rheumatoid arthritis who are in treatment with methotrexate develop a clinical picture of pneumonitis after infliximab therapy is started.<sup>2</sup> We report such a case that resolved after treatment with corticosteroids and withdrawal of infliximab.

The patient was a 60-year-old woman with a medical history of overweight, noninsulin-dependent diabetes mellitus, herniorrhaphy, kidney stones, cholecystectomy, and nonfunctioning adrenal nodule. Diagnosed with adult Still's disease 15 years earlier,<sup>3</sup> she had been taking methotrexate at doses ranging from 15 to 7.5 mg/week for 2 years. Due to worsening clinical indicators for joint disease, with increased pain and positivation of rheumatoid factor, infliximab treatment was started at a dosage of 3 mg/kg. Seven days after the first infusion, the patient was admitted with fever and severe pleuritic pain mainly on the left side. Exanthema was not found. Noteworthy laboratory results were an elevated white blood cell count with left shift and elevated erythrocyte sedimentation rate and C-reactive protein level. The sputum culture and smear test were negative. Resting arterial blood gas analysis revealed a PaO<sub>2</sub> of 63 mm Hg, a PaCO<sub>2</sub> of 31 mm Hg, and a pH of 7.47. A simple x-ray revealed an azygos lobe, bibasal atelectasis, and a small pleural effusion on the left side (Figure 1). A computed tomography (CT) scan of the thorax showed a small area of bilateral pleural effusion, posterobasal atelectasis, and thickening of interlobar septae that suggested interstitial involvement (Figure 2). Lung function tests indicated slight loss of forced vital capacity and normal forced expiratory volume in the first second and carbon monoxide diffusing capacity. Treatment with parenteral methylprednisolone (60 mg/day) led to gradual improvement in symptoms and arterial blood gas. The follow-up chest CT scan 15 days later was completely normal, as were all lung function parameters 3 months later.

The anti-inflammatory effects of TNF blockers have led to their use in a variety of inflammatory diseases (chronic juvenile arthritis, adult Still's disease, psoriatic arthritis, Crohn's disease) although the original indication was rheumatoid arthritis. TNF- $\alpha$  plays a central role in inflammation and is

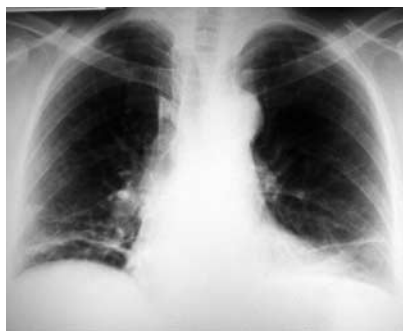

Figure 1. Simple chest radiograph.

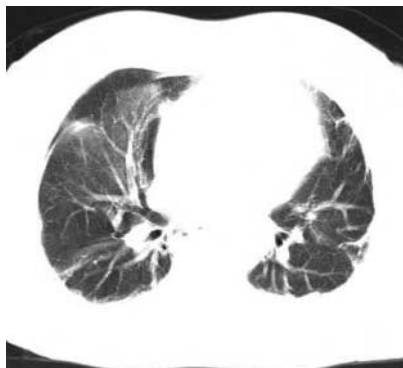

Figure 2. High resolution computed tomography scan of the thorax.

considered one of the most potent proinflammatory cytokines. Blocking it rapidly neutralizes inflammatory signs and symptoms (fever, elevated C-reactive protein levels, anemia, and more) and TNF- $\alpha$  blockers are therefore used as an additional treatment in these processes so that the usual immunodepressant therapy can be reduced.<sup>4</sup>

Currently, there are 3 biological agents that neutralize the biological action of TNF- $\alpha$ : a chimeric monoclonal antibody (infliximab), a soluble receptor (etanercept), and a humanized monoclonal antibody (adalimumab). All of them reduce T-helper 1-type immunity by blocking interleukins 12 and 18. Because of the resulting immunosuppression, their clinical use has been associated with a wide range of infectious diseases (tuberculosis, histoplasmosis, cryptococcosis) as the most common complication. Other adverse effects described occasionally have been fulminant hepatitis, pulmonary granulomatosis, and induction pneumonitis in patients treated with methotrexate.<sup>2</sup>

C. Martín Carrasco, B. Hortal Reina,  
and E. Fernández Vázquez

Servicio de Neumología,  
Hospital Universitario Virgen de las Nieves,  
Granada, Spain.

1. Vasallo R, Matteson E, Thomas CF. Clinical response of rheumatoid arthritis associated pulmonary fibrosis to tumor necrosis factor- $\alpha$  inhibition. *Chest*. 2002; 122:1093-6.

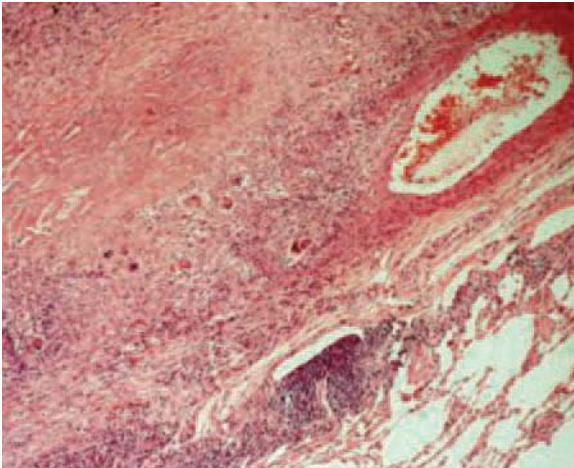
2. Kramer N, Chuzhin Y, Kaufman LD, Ritter JM, Rosenstein ED. Methotrexate pneumonitis after initiation of infliximab therapy for rheumatoid arthritis. *Arthritis Rheum*. 2002; 47:670-1.
3. Yamaguchi M, Ohta A, Tsunematsu T, Kasukawa R, Mizushima Y, et al. Preliminary criteria for classification of adult Still's disease. *J Rheumatol*. 1992;19: 424-30.
4. Charles P, Elliot MJ, Davis D, Potter A, Kalden JR, Antoni C. Regulation of cytokines, cytokine inhibitors, and acute-phase proteins following anti-TNF- $\alpha$  therapy in rheumatoid arthritis. *J Immunol*. 1999; 163:1521-8.

### Necrotizing Sarcoid Granulomatosis

#### To the editor:

Necrotizing sarcoid granulomatosis (NSG) is a rare cause of granulomatosis and pulmonary vasculitis, first described by Liebow<sup>1</sup> in 1973. Histology is characterized by sarcoid granulomata and granulomatous vasculitis.<sup>2</sup> On x-ray it presents as lung nodules and the clinical course is benign, with or without or treatment.

We present the case of a 45-year-old man, smoker of 40 pack-years and consumer of 30 g of alcohol per day. During the preoperative examination, a chest x-ray revealed partially cavitated bilateral lung nodules. The patient reported no respiratory symptoms: merely mild intoxication with weight loss of 4 kg in the previous month. The physical examination revealed no information of interest. The hemogram showed no abnormalities and the erythrocyte sedimentation rate was 47 mm/h. Biochemistry revealed abnormal liver function. The angiotensin-converting enzyme value was 58 U/L. Tumor markers ( $\beta_2$ -microglobulin, carcinoembryonic antigen) were negative, as were serologies for human immunodeficiency virus, hepatitis B and C, *Legionella* and *Mycoplasma* species, Q-fever and psittacosis. The basic immunologic study was also negative for cryoglobulins, extractable nuclear antigens, antinuclear antibodies, neutrophil anticytoplasmic antibodies,  $\alpha$ -1 antitrypsin, complement, E immunoglobulin, anti-smooth muscle antibodies, antimitochondrial antibodies, anti-DNA antibodies, and rheumatoid factor. The chest x-ray showed one nodule in the right lower lobe and another in the left lower lobe (LLL) with calcification. The Ziehl-Neelsen stain and sputum cultures for *Mycobacterium* species were negative. Lung-function tests gave the following results: forced vital capacity, 4.70 L (114%); forced expiratory volume in 1 second, 3.98 L (116%); ratio of forced expiratory volume in 1 second to forced vital capacity, 84%; vital capacity, 4.93 L (114%); total lung volume, 6.56 L (103%); residual volume, 1.63 L (82%); carbon monoxide diffusing capacity corrected for alveolar volume, 84%. Computed tomography of the chest showed bilateral lung nodules (in the LLL and the right lower lobe), some of them cavitated and partially calcified, with no appreciable mediastinal lymph-node involvement. Fine-needle aspiration was performed on the nodule in the LLL, guided by computed tomography and the



**Figure. Epithelioid granuloma affecting the vascular wall (hematoxylin-eosin,  $\times 10$ ).**

cytology and microbiology tests were negative. Bronchoscopy showed no significant macroscopic abnormalities and cytology results (bronchoalveolar lavage and bronchial aspirate) were negative for malignant cells, Ziehl-Neelsen staining and cultures were negative. The composition of the bronchoalveolar lavage was 96% macrophages, 3% lymphocytes, and 1% polymorphonuclear cells.

In the absence of a diagnosis, a lung biopsy was performed via video-assisted thoracoscopy and a yellow nodule situated in the LLL was removed. Histology revealed the presence of abundant epithelioid granulomata, some with large areas of central necrosis, occasionally affecting the walls of vascular structures (Figure). Paraaminosalicylic acid, Gomori, and Kinyoun stains were negative. The pathologist's diagnosis was NSG. During the 6-month clinical follow-up period, the patient remained asymptomatic with no clinical or radiographic progression. No treatment was prescribed, therefore.

The etiopathogenesis of NSG is unknown although a hypersensitivity reaction due to the vascular involvement and granulomatous inflammation have been implicated. NSG has been shown to respond well to corticosteroids. It tends to occur toward middle life and is seen predominantly in women.<sup>3</sup> Symptoms may be absent in 25% of cases, as occurred with our patient, or patients may present nonspecific pulmonary symptoms and/or systemic symptoms. Extrapulmonary involvement is not usual. Chest x-rays typically reveal the

presence of multiple lung nodules (though occasionally there may be only a solitary one) with cavitation present in some cases. The fact that some of the nodules were calcified in our patient was of note. NSG should be distinguished from pulmonary sarcoidosis, which mostly presents with respiratory symptoms although it may also affect the lymph nodes, eyes, and skin. It is occasionally detected in asymptomatic patients. Vasculitis and secondary necrosis are very rare in sarcoidosis but are typical of NSG. Some authors consider NSG to be a variant of nodular sarcoidosis.<sup>4</sup> Furthermore, B- and T-cell activity and angiotensin converting enzyme concentrations in blood and lung tissue are normal with this condition, unlike sarcoidosis. Other markers, such as the interleukin-2 receptor show high levels in NSG and are therefore useful in clinical detection of the disease.<sup>5</sup> Differential diagnosis, including pulmonary sarcoidosis, tuberculosis, Wegener's granulomatosis and lymphomatoid granulomatosis, is based on autoimmune studies and pathology. Final diagnosis is made by means of open lung biopsy, where typical findings include angiocentric necrosis, confluent epithelioid and giant-cell granulomata, and granulomatous vasculitis in the walls of small vessels. NSG is often associated with necrosis

of the vascular wall and lung parenchyma, which distinguishes it from sarcoidosis.<sup>4</sup> All these findings were detected in our patient.

Prognosis is usually benign and in many cases no treatment is required. However, corticosteroids have been used with good results in patients with progressive or severe disease or where there is central nervous system involvement. Immunosuppressants (cyclophosphamide, chlorambucil) have also been used in patients with progressive disease<sup>6</sup> or who are refractory to corticosteroid treatment or who develop side effects. Experience is very limited, however.

The foregoing induces us to believe that, given the existence of bilateral lung nodules, we should bear in mind the diagnosis of NSG, which has a benign and favorable prognosis.

**L. Cuadra Llopart,<sup>a</sup> B. Barreiro López,<sup>b</sup> and P. Forcada Guin<sup>c</sup>**

<sup>a</sup>Servicio de Medicina Interna, Hospital Mútua de Terrassa, Terrassa, Barcelona, Spain.

<sup>b</sup>Servicio de Neumología, Hospital Mútua de Terrassa, Terrassa, Barcelona, Spain.

<sup>c</sup>Servicio de Anatomía Patológica, Hospital Mútua de Terrassa, Terrassa, Barcelona, Spain.

1. Liebow AA. Pulmonary angiitis and granulomatosis. *Am Rev Respir Dis.* 1973; 108:1-18.
2. Churg A, Carrington CB, Gupta R. Necrotizing sarcoid granulomatosis. *Chest.* 1979;76:406-13.
3. Churg A. Pulmonary angiitis and granulomatosis revisited. *Hum Pathol.* 1983;14:868-83.
4. Popper HH, Klemen H, Colby TV, Churg A. Necrotizing sarcoid granulomatosis. Is it different from nodular sarcoidosis? *Pneumologie.* 2003;57:268-71.
5. Harada T, Amano T, Takahashi A, Furuya J, Yamaguchi E, et al. Necrotizing sarcoid granulomatosis presenting with elevated serum soluble interleukin-2 receptor levels. *Respiration.* 2002;69:468-70.
6. Koss MN, Hochholzer L, Feigin DS, Garancis JC, Ward PA. Necrotizing sarcoid-like Granulomatosis: clinical, pathologic, and immunopathologic findings. *Hum Pathol.* 1980;11 Suppl:510-9.