

Sarcoidosis Following Combined Ribavirin and Interferon Therapy: a Case Report and Review of the Literature

I. Alfageme Michavila,^a M. Merino Sánchez,^a J. Pérez Ronchel,^a I. Lara Lara,^b E. Suárez García,^c and J. López Garrido^b

^aSección de Neumología, Hospital Universitario de Valme, Sevilla, Spain.

^bServicio de Anatomía Patológica, Hospital Universitario de Valme, Sevilla, Spain.

^cSección de Digestivo, Hospital Universitario de Valme, Sevilla, Spain.

Treatment of active chronic viral hepatitis type C with interferon alpha has proved effective and therefore its use is being extended to a large number of patients. Common side effects include respiratory manifestations. One side effect attributable to the immunomodulatory effect of interferon is the possible triggering or exacerbation of systemic or cutaneous sarcoidosis. We report a new case and offer an exhaustive review of the literature.

A 49-year-old man with type C chronic, active hepatitis developed new respiratory symptoms and pulmonary infiltrates with hilar and mediastinal adenopathy after 4 months of treatment with pegylated interferon and ribavirin. The transbronchial biopsy showed multiple sarcoid granulomas. When the patient was diagnosed, he had already taken the total dose of interferon and no specific treatment was started. His hepatitis did not respond to therapy and his viral load and transaminase levels remained high.

Key words: *Pulmonary sarcoidosis. Hepatitis C. Interferon therapy. Adverse effects interferon therapy. Antiviral agents.*

Sarcoidosis tras tratamiento con interferón y ribavirina. Presentación de un caso y revisión de la bibliografía

El tratamiento con interferón alfa en la hepatitis crónica activa por el virus C tiene una eficacia demostrada, por ello se está generalizando su uso a gran número de pacientes. Entre los efectos secundarios, las manifestaciones respiratorias banales son muy frecuentes. Un efecto secundario atribuible al efecto inmunomodulador del interferón es la posibilidad de agravar o desencadenar una sarcoidosis cutánea o sistémica. Presentamos un nuevo caso y hacemos una exhaustiva revisión de la bibliografía.

Se comunica el caso de un varón de 49 años con hepatitis crónica activa por el virus C que a los 4 meses de tratamiento con interferón pegilado más ribavirina presentó sintomatología respiratoria que no tenía previamente e infiltrados pulmonares con adenopatías hiliares y mediastínicas. En la biopsia transbronquial se apreciaron abundantes granulomas sarcoideos. Cuando se diagnosticó, el paciente había finalizado toda la dosis de interferón y no se instauró ningún tratamiento específico. La hepatitis no respondió a la terapia, permaneciendo elevada la carga viral y las transaminasas.

Palabras clave: *Sarcoidosis pulmonar. Hepatitis C. Tratamiento con interferón. Efectos adversos del tratamiento con interferón. Agentes antivirales.*

Introduction

Sarcoidosis is a multisystemic granulomatous illness of unknown cause that has been associated with various agents and whose pathogenesis involves immunological mechanisms that are only partly understood, such as the exaggerated immune response of helper T lymphocytes (T_H1) to a variety of exogenous antigens or

autoantigens.¹

Interferon alpha (IFN- α) is an immunomodulator used as an antiviral agent in cases of active chronic viral hepatitis C. Its antiviral effect is due to the inhibition of protein synthesis and an increase in viral RNA degradation, inducing a state of resistance to viral infection inside cells and modulating the effector arm of the immune system in order to neutralize viruses or eliminate the cells infected by them.

The first report of a case of sarcoidosis triggered by IFN- α treatment, in a patient with a renal carcinoma, was published in 1987; in 1994 the first case of sarcoidosis in a patient with active chronic viral

Correspondence: Dra. I. Alfageme.
Bobby Deglané, 5, 3D. 41001 Sevilla, España.
E-mail: ialfageme@telefonica.net

Manuscript received May 19, 2003. Accepted for publication June 3, 2003.

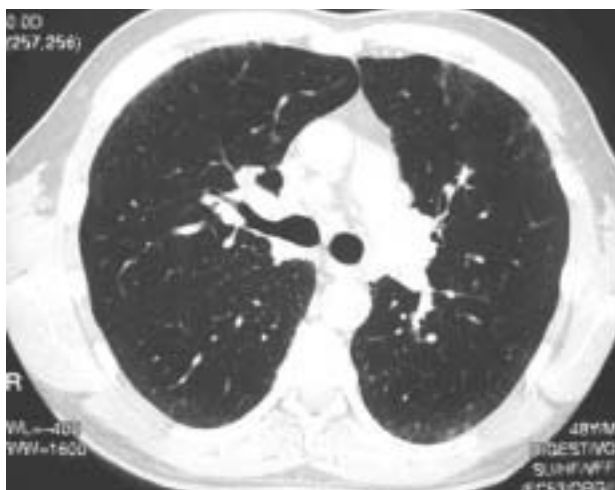

Figure 1. Infiltrate on ground glass opacities and affected hilar nodes.

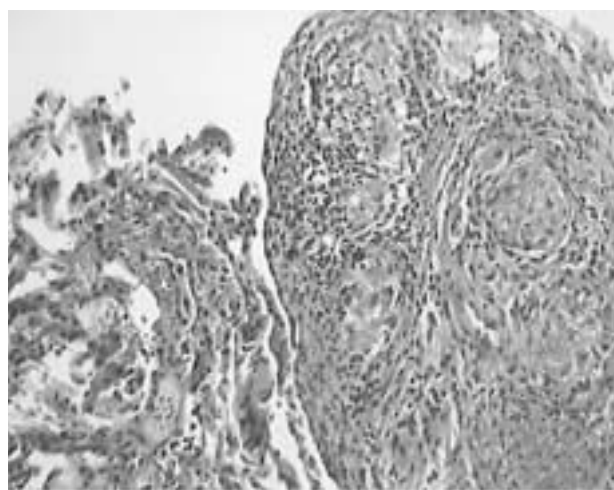


Figure 2. Pulmonary tissue: sarcoid granulomas with central, noncaseous fibrinoid necrosis with palisading histiocytes, rimmed by macrophages and lymphocytes (hematoxylin, eosin, $\times 200$).

hepatitis C treated with IFN- α was reported.² Given the clearly demonstrated effectiveness of IFN- α treatment, it is to be expected that a high number of patients will benefit from it in the next few years.

For this reason, and because of the consequences this treatment can have in clinical practice, we report a new case of sarcoidosis triggered by treatment with IFN- α and ribavirin and provide an exhaustive review of the literature.

Clinical Observations

We report the case of a 48-year-old man, diagnosed with active chronic hepatitis C infection in 1989 with no history of smoking or alcohol abuse. A liver biopsy showed chronic portal and periportal hepatitis with features suggesting C virus infection. The hepatitis C viral load was 3 090 000 IU/mL, and its genotype was 1b. The hemogram was within normal limits, with an aspartate aminotransferase concentration of 64 U/L, and an alanine aminotransferase concentration of 162 U/L; the results of all other analyses were normal. In April 2001 treatment was started using a combination of pegylated IFN- α at a dosage of 180 μ g/week and ribavirin at a dosage of 1200 mg/day. The treatment ended in April 2002. In the first month of treatment the patient developed thrombopenia (platelet count 87 000) and leukopenia (neutrophil count 1810), although the dosage of interferon and ribavirin was not altered because of this. After 9 months of treatment, the patient developed nonspecific respiratory symptoms and breathing difficulties that persisted and increased after April 2002, for which reason he was seen at our clinic. When treatment ended the viral load was still 1 220 000 IU/mL, the aspartate aminotransferase concentration was 136 U/L, the alanine aminotransferase concentration was 247 U/L, and anemia and thrombopenia had returned to

normal. Apart from the respiratory symptoms described previously, the physical examination revealed no abnormalities. The chest x-ray showed an ill-defined interstitial infiltrate affecting mainly the lower lung fields. High-resolution computed tomography of the thorax (Figure 1) revealed an interstitial pattern and the presence of affected hilar and mediastinal lymph nodes measuring less than 1 cm. The lung function examination gave the following results: forced vital capacity, 5.74 L (117%); forced expiratory volume in the first second, 4.49 L (114%); forced expiratory volume in the first second/forced vital capacity, 78%; total lung capacity, 8.69 L (116%), and carbon monoxide diffusion capacity, 9.46 (86%). Basal arterial blood gas tests gave the following results: PaO₂, 98 mm Hg; PaCO₂, 40 mm Hg; pH, 7.43. The angiotensin-converting enzyme concentration was 47 U/L (normal range: 20-60 U/L). Fiberoptic bronchoscopy was carried out, with bronchoalveolar lavage and transbronchial biopsy. The bronchoalveolar lavage fluid contained 73% macrophages, 20% lymphocytes, 5% neutrophils and 2% eosinophils; the CD4 count was 190, the CD8 count was 50, and the CD4/CD8 ratio was 3.8. Examination of the transbronchial biopsy revealed the presence of multiple sarcoid granulomas (Figure 2).

Discussion

We report a new case in which sarcoidosis was triggered by treatment with IFN- α plus ribavirin in a patient with active chronic viral hepatitis C. A search of the literature in the main databases (PubMed, MEDLINE, Embase, Scirus and Índice Médico Español) using the words "interferon," "sarcoidosis," and "hepatitis C," gave a total of 35 references from which 22 were selected. One case occurred twice (once in Spanish and once in English) and was only counted

TABLE
Characteristics of the Patients With Sarcoidosis During Interferon Alfa(IFN- α) Treatment for Active Chronic Viral Hepatitis C*

Authors and Year	No. of Cases	Age/Sex	Dosage	Type of IFN- α and Antiviral Agent	Time of Appearance (Months) [†]	Location	Diagnostic Method	Treatment for Sarcoidosis	Evolution of Sarcoidosis	Evolution Active Chronic Viral Hepatitis C
Ohhata et al., ² 1994	1	57 W	NIG	NIG	2	Skin+lung	Skin biopsy	Reduce IFN+prednisone	Cured	NIG
Nakajima et al., ³ 1996	1	67 M	60 MU	NIG	5	Lung	TBB	Suspend IFN+prednisone	Cured	NIG
Teragawa et al., ⁴ 1996	1	62 W	522 MU	IFN-2a	4	Lung	Lung biopsy	Prednisone	Improved	Cured
Otte et al., ⁵ 1997	1	72 M	108 MU	NIG	3	Skin+lung	Skin biopsy+lung biopsy	Prednisone+chloroquine	Improved	NIG
Hoffmann et al., ⁶ 1998	3	41 M 39 M 54 M	228 MU 288 MU 144 MU	2a+R 2a 2a+R	4 5 3	Lung Skin+lung Lung	TBB Skin biopsy+CT TBB	Prednisone Suspend IFN None	Cured Cured Improved	No R Cured No R
Eberlein-König et al., ⁷ 1999	1	60 W	552 MU	2 a	4	Skin	Skin biopsy	Reduce IFN+topical corticosteroid	Improved	No R
Pohl et al., ⁸ 2000	1	41 W	864 MU	NIG+R	4	Lung	TBB	Suspend IFN	Improved	Cured
Savoie et al., ⁹ 2000	1	52 W	432 MU	NIG+R	6	Skin	Skin biopsy	None	Cured	Cured
Cacoub et al., ¹⁰ 2000	1	62 W	72 MU	NIG	2	Skin+lung+heart+uveitis	Skin biopsy+systemic symptoms	Suspend IFN+prednisone	Cured	No R
Vander et al., ¹¹ 2000	1	39 W	39 MU	NIG+R	6	Skin+lung	TBB	Prednisone	Improved	NIG
Neglia et al., ¹² 2001	1	50 W		NIG	3	Skin	NIG	NIG	NIG	NIG
Leveque et al., ¹³ 2001	2	46 M 55 W	612 MU 288 MU	NIG+R NIG+R	5 4	Lung Skin	TBB Skin biopsy	Suspend IFN+prednisone	Cured	No R
Bonnet et al., ¹⁴ 2001	1	NIG	NIG	NIG	NIG	Lung	Lung biopsy	Suspend IFN	Improved	NIG
Krehmeier et al., ¹⁵ 2001	1	42 M		NIG	10	Lung	TBB	Prednisone	NIG	NIG
Ravenel et al., ¹⁶ 2001	1	42 W	864 MU+ 15 μ g \times 2	2b+R+peg.	23	Lung	Lung biopsy	Suspend IFN+prednisone	Improved	NIG
Wendling et al., ¹⁷ 2002	2	54 W 50 M	1.4 μ g/kg 108 MU	Peg+R NIG+R	4 3	Skin+lung Skin	Skin biopsy+CT Skin biopsy	None	Cured	NIG
Nawras et al., ¹⁸ 2002	1	42 W	36 MU	2b	1	Lymph node+skin	Biopsies of affected paratracheal lymph nodes and skin	Suspend IFN+prednisone	Cured	NIG
Cogrel et al., ¹⁹ 2002	2	44 W 30 M	324 MU 108 MU	NIG+R NIG+R	3 3	Skin Skin+lung	Skin biopsy Skin biopsy+CT	Suspend IFN	Cured Cured	Cured
Noguchi et al., ²⁰ 2002	1	26 M	216 MU	2b	1	Lung	TBB	Prednisone	Cured	No R
Gitlin, ²¹ 2002	2	49 M 52 M	216 MU 216 MU	2b+R 2b+R	4 5	Skin+liver Skin	Skin and/or liver biopsies Skin biopsy	None Suspend IFN	Cured	No R No R
Pérez-Álvarez et al., ²² 2002	2	50 W 38 M	432 MU 576 MU	2b,a+R 2b,a+R	1 5	Lung Skin+lung	TBB Skin biopsy+XR	Prednisone Suspend IFN+ prednisone	Improved Cured	Cured No R
Li et al., ²³ 2002	1	48 M	1650 MU	2a+2b	11	Lymph node	Lymph node biopsy	Suspend IFN	Improved	No R
Present case	1	48 M	180 μ g per week in 3 doses	Peg+R	10	Lung	TBB	None	Stable	No R

*TBB indicates transbronchial biopsy; CT, computed tomography; XR, x-ray; M, men; W, women; MU, million units; NIG, no information given; no R, no reply; peg, pegylated; R, ribavirin. [†]After start of treatment.

once. The rest were descriptions of new cases. The table shows the main characteristics of all these cases. A total of 30 patients (14 men, 16 women) are described, including the case we report. The average age was 49 (age range from 26 to 72 years). In 4 of the cases (14%) there was an exacerbation of previously diagnosed sarcoidosis and in the rest sarcoidosis was diagnosed for the first time. Nine patients had previously been unsuccessfully treated with IFN- α alone and had been selected for a new combined treatment using IFN- α and ribavirin (or other antiviral agent). IFN- α 2a was used in all but 3 patients, in whom pegylated interferon was used. The dosage of interferon administered varied greatly (between 36 and 1650 million units in total, with a mean total of 368 million units). Combined treatment with IFN- α and ribavirin was initiated in 17 patients (57%). Signs and symptoms of sarcoidosis appeared over a long period after treatment was started (1-23 months, with a mean of 5 months). Seven patients presented cutaneous sarcoidosis only; in the remaining 23 there was systemic involvement. In 70% of patients (n=21) the lungs were affected. Lung involvement was revealed by histological tests in 14 of these patients and in the remaining 7, radiographic or functional changes caused lung disease to be suspected. Cutaneous involvement appeared in 17 patients, including 5 with sarcoid lesions on old scars or tattoos. When sarcoidosis was detected 12 patients had already completed their treatment and taken the prescribed dose of interferon, in 12 cases treatment was discontinued, and in 14 cases corticosteroids were added. The evolution of the sarcoidosis varied: in 14 patients it was cured, in 10 there was clinical improvement, in 2 there was no change, and in 1 it remained stable. The evolution of the hepatitis C infection is reported in 17 cases; in 11 of them (65%) measurement of the viral load or biochemical liver parameters indicated that the illness was not cured. In the 6 remaining patients the transaminase level returned to normal or the viral load disappeared.

Active chronic hepatitis C virus infection causes an inflammatory reaction in the liver with hepatocellular necrosis and fibrosis. Approximately 4 000 000 people in the USA and probably more than 100 000 000 people in the world are infected by the hepatitis C virus.²⁴ According to the World Health Organization, 2% of the Spanish population may be infected by the hepatitis C virus. Of the people infected 70%-80% become chronic carriers; most of them have a mild form of the illness that progresses slowly. However chronic progressive hepatitis has a high morbidity and mortality rate and is the main cause of cirrhosis, end-stage liver disease, and cancer of the liver.²⁴ IFN- α has been used in treatment since 1989 (first alone and later in combination with ribavirin). A sustained response at the end of treatment has been achieved in 33% of cases in treatments lasting 24 weeks and in 41% of cases in treatments lasting 48 weeks.^{25,26} More recently the use of high doses of pegylated interferon combined with ribavirin has

achieved a sustained response in 54% of cases.²⁷ Side effects of interferon treatment are very common and correlate with dosage, although in the case of pegylated interferon, treatment is discontinued in only 3%-14%.²⁸ The side effects are usually not severe and pulmonary infiltrates occur in less than 1%.²⁸ The incidence of sarcoidosis in association with interferon treatment is not known. Hofmann et al⁶ found 3 cases (5%) in a series of 60 patients treated with interferon (with or without added ribavirin). It is difficult to calculate the exact incidence because the signs and symptoms of sarcoidosis can add to the usual effects of interferon. This may lead to under-diagnosis of sarcoidosis. Although the appearance of sarcoid lesions has been described in treatments using interferon alone or in combination with ribavirin, ribavirin alone has never been associated with the appearance of sarcoidosis. Hepatitis C has been associated with other autoimmune diseases but there is insufficient information to link it to the appearance of sarcoidosis.

As well as its antiviral and antiproliferative effects, IFN- α has immunomodulatory functions that probably include regulating the differentiation of helper T cells by inhibiting T_H2 activation, inducing the production of interferon gamma, Interleukin-12 receptor expression, and Interleukin-12 signaling, as well as neutralizing the effects of Interleukin 4, affecting the maturing of helper T cells.²⁹ Although the causes of sarcoidosis are still unknown, there are good reasons for suspecting the exposure of genetically susceptible hosts to external environmental agents. This could lead to the conclusion that the administration of exogenous IFN- α may influence the differentiation of CD4 T cells towards the T_H1-type immune response, leading to the formation of granulomas and giving rise to sarcoidosis in susceptible individuals. The existence of 29 cases in the literature corroborates the connection between the activity of exogenous IFN- α and the differentiation of lymphocytes towards the T_H1 line, leading to the formation of granulomas. Although this could be attributed to the number of people who would have presented with sarcoidosis during their lifetime, the fact that sarcoidosis that was previously in remission worsened seems to support the theory that exogenous interferon affects this particular immune response.

We therefore wish to call attention to this side effect of IFN- α treatment so that it can be taken into account when deciding on treatment for active chronic hepatitis C infection, so that such treatment can be avoided in known cases of sarcoidosis, and so that caregivers can be alert for the appearance of respiratory signs and symptoms or pulmonary infiltrates during IFN- α treatment.

REFERENCES

1. Kataria YP, Holter JF. Immunology of sarcoidosis. *Clin Chest Med* 1997;18:719-39.
2. Ohhata I, Ochi T, Kurebayashi S, Masutani H, Kikui M. A case of subcutaneous sarcoid nodules induced by interferon-alpha. *Nihon*

ALFAGEME MICHAVILA I, ET AL. SARCOIDOSIS FOLLOWING COMBINED RIBAVIRIN AND INTERFERON THERAPY:
A CASE REPORT AND REVIEW OF THE LITERATURE

- Kyobu Shikkan Gakkai Zasshi 1994;32:996-1000.
3. Nakajima M, Kubota Y, Miyashita N, Niki Y, Matsushima T, Manabe T. Recurrence of sarcoidosis following interferon alpha therapy for chronic hepatitis C. *Intern Med* 1996;35:376-9.
 4. Teragawa H, Hondo T, Takahashi K, Watanabe H, Ohe H, Hattori N, et al. Sarcoidosis after interferon therapy for chronic active hepatitis C. *Intern Med* 1996;35:19-23.
 5. Otte HG, Hartig C, Stadler R. Sarcoidosis in interferon-alpha therapy. *Hautarzt* 1997;48:482-7.
 6. Hoffmann RM, Jung MC, Motz R, Gossel C, Emslander HP, Zachoval R, et al. Sarcoidosis associated with interferon-alpha therapy for chronic hepatitis C. *J Hepatol* 1998;28:1058-63.
 7. Eberlein-König B, Hein R, Abeck D, Engst R, Ring J. Cutaneous sarcoid foreign body granulomas developing in sites of previous skin injury after systemic interferon-alpha treatment for chronic hepatitis C. *Br J Dermatol* 1999;140:370-2.
 8. Pohl J, Stremmel W, Kallinowski B. Pulmonary sarcoidosis: a rare side effect of interferon-alpha treatment for chronic hepatitis C infection. *Z Gastroenterol* 2000;38:951-5.
 9. Savoye G, Gorla O, Herve S, Riachi G, Noblesse I, Bastien L, et al. Probable cutaneous sarcoidosis associated with combined ribavirin and interferon-alpha therapy for chronic hepatitis C. *Gastroenterol Clin Biol* 2000;24:679.
 10. Cacoub P, Sbai A, Frances C, Genesti C, Hausfater P, Piette JC. Systemic sarcoidosis during interferon-alpha therapy for chronic hepatitis C virus infection. *Gastroenterol Clin Biol* 2000;24:364-6.
 11. Vander Els NJ, Geddes H. Sarcoidosis and IFN-(alpha) treatment. *Chest* 2000;117:294.
 12. Neglia V, Sookoian S, Herrera M, Abeldano A, Kien MC, Chouela E, et al. Development of cutaneous sarcoidosis in a patient with chronic hepatitis C treated with interferon alpha 2b. *J Cutan Med Surg* 2001;5:406-8.
 13. Leveque L, De Boulard A, Bielefeld P, Sgro C, Hillon P, Gabreau T, et al. Sarcoidosis during the treatment of hepatitis C by interferon-alpha and ribavirin: 2 cases. *Rev Med Interne* 2001;22:1248-52.
 14. Bonnet F, Dubuc J, Morlat P, Delbrel X, Doutre MS, De Witte S, et al. Sarcoidosis and comorbidity: retrospective study of 32 cases. *Rev Med Intern* 2001;22:619-23.
 15. Krehmeier H, Egberts EH. Sarcoidosis after interferon-alpha treatment in hepatitis C. *Dtsch Med Wochenschr* 2001;126:460.
 16. Ravenel JG, McAdams HP, Plankeel JF, Butnor KJ, Sporn TA. Sarcoidosis induced by interferon therapy. *AJR Am J Roentgenol* 2001;177:199-201.
 17. Wendling J, Descamps V, Grossin M, Marcellin P, Le Bozec P, Belaich S, et al. Sarcoidosis during combined interferon-alpha and ribavirin therapy in 2 patients with chronic hepatitis C. *Arch Dermatol* 2002;138: 546-7.
 18. Nawras A, Alsolaiman MM, Mehboob S, Bartholomew C, Maliakkal B. Systemic sarcoidosis presenting as a granulomatous tattoo reaction secondary to interferon-alpha treatment for chronic hepatitis C and review of the literature. *Dig Dis Sci* 2002; 47:1627-31.
 19. Cogrel O, Doutre MS, Marliere V, Beylot-Barry M, Couzigou P, Beylot C. Cutaneous sarcoidosis during interferon alpha and ribavirin treatment of hepatitis C virus infection: two cases. *Br J Dermatol* 2002;146:320-4.
 20. Noguchi K, Enjoji M, Nakamura M, Sugimoto R, Coto K, Nawata H. Various sarcoid lesions in a patient induced by interferon therapy for chronic hepatitis C. *J Clin Gastroenterol* 2002;35: 282-4.
 21. Gitlin N. Manifestation of sarcoidosis during interferon and ribavirin therapy for chronic hepatitis C: a report of two cases. *Eur J Gastroenterol Hepatol* 2002;14:883-5.
 22. Pérez-Álvarez R, Pérez-López R, Lombrana JL, Rodríguez M, Rodrigo L. Sarcoidosis in two patients with chronic hepatitis C treated with interferon, ribavirin and amantadine. *J Viral Hepat* 2002;9:75-9.
 23. Li SD, Yong S, Srinivas D, Van T. Reactivation of sarcoidosis during interferon therapy. *J Gastroenterol*. 2002;37:50-4.
 24. Liang TJ, Rehermann B, Seeff LB, Hoofnagle JH. Pathogenesis, natural history, treatment, and prevention of hepatitis C. *Ann Intern Med* 2000;132:296-305.
 25. McHutchison JG, Gordon SC, Schiff ER, Shiffman ML, Lee WM, Rustgi V, et al. Interferon alpha 2b alone or in combination with ribavirin as initial treatment for chronic hepatitis C. *N Engl J Med* 1998;339:1485-92.
 26. Poynard T, Marcellin P, Lee SS, Miederau C, Minuk GS, Ideo G, et al. Randomised trial of interferon a2b plus ribavirin for 48 weeks or for 24 weeks versus interferon a2b plus placebo for 48 weeks for treatment of chronic infection with hepatitis C virus. *Lancet* 1998;352:1426-32.
 27. Manus MP, McHutchison JG, Gordon SC, Rustgi VK, Shiffman M, Reindollar R, et al. Peginterferon alpha-2b plus ribavirin compared with interferon alpha-2b plus ribavirin for initial treatment of chronic hepatitis C: a randomized trial. *Lancet* 2001; 358:958-65.
 28. Fried MW. Side effects of therapy of hepatitis C and their management. *Hepatology* 2002;36:S237-S44.
 29. Fels AOS, Nathan DF, Cohn ZA. Hydrogen peroxide release by alveolar macrophages from sarcoid patients and by alveolar macrophages from normal after exposure to recombinant interferons α A, β and γ and 1,25-dihydroxyvitamin D3. *J Clin Invest* 1987;80:381-6.