

Polyradiculitis and Wegener's Granulomatosis

A. Casanova,^a E. Pérez Amor,^a R.M. Girón,^a E. Zamora,^a M.D. Vélez,^b and J. Ancochea^a

^aServicio de Neumología, Hospital Universitario de la Princesa, Madrid, Spain.

^bServicio de Anatomía Patológica, Hospital Universitario de la Princesa, Madrid, Spain.

Wegener's granulomatosis is a systemic vasculitis of unknown etiology, primarily affecting the upper and lower respiratory tract and the kidneys, although there is a form restricted to the lungs. Wegener's granulomatosis occurs infrequently, with an estimated annual incidence of 8.5 cases per million. The principal symptoms at onset usually involve the upper and lower airway. The central nervous system is involved in approximately 22% of cases, but neurological signs occur infrequently among the initial clinical manifestations. Proteinase 3-specific antineutrophil cytoplasmic antibodies are useful serological markers for establishing a diagnosis, which should, however, be confirmed by a tissue biopsy of the affected organ.

Key words: *Wegener's granulomatosis. Polyneuropathy. Pulmonary vasculitis.*

Polirradiculitis y enfermedad de Wegener

La enfermedad de Wegener es una vasculitis granulomatosa sistémica de etiología desconocida, que afecta sobre todo al tracto respiratorio superior e inferior y al riñón, aunque se distingue una forma limitada al pulmón. Es una entidad poco frecuente, con una incidencia estimada de 8,5 por 1.000.000 de habitantes/año. Los principales síntomas de comienzo suelen ser los derivados de la afectación de las vías aéreas superior e inferior. El sistema nervioso central se implica en alrededor de un 22% de los casos, pero es infrecuente que la clínica neurológica forme parte de la sintomatología inicial. Los anticuerpos anticitoplasma del neutrófilo específicos contra la proteinasa 3 constituyen marcadores serológicos de gran utilidad para el establecimiento del diagnóstico, aunque éste debe confirmarse por la biopsia tisular del órgano afectado.

Palabras clave: *Enfermedad de Wegener. Polineuritis. Vasculitis pulmonares.*

Introduction

Wegener's granulomatosis is a multisystemic granulomatous vasculitis, primarily affecting the respiratory tract and the kidneys. Although of unknown etiology, evidence suggests that circulating immune complexes may play a role in its pathogenesis.¹ At onset, most patients have upper airway involvement and lung infiltrates. Nervous system involvement is rare, with mononeuropathy being the most characteristic initial manifestation. We present a case in which neurological symptoms were predominant in the initial phase of the disease.

Correspondence: Dr. R.M. Girón Moreno.
Servicio de Neumología, Hospital de la Princesa.
Diego de León, 62. 28006 Madrid. España.
E-mail: med002861@nacom.es

Manuscript received March 4, 2003. Accepted for publication July 9, 2003.

Case Description

A 59-year-old woman presented to the emergency room complaining of myalgia in both quadriceps that began 3 days earlier. The patient also reported odynophagia, chills, and pleuritic pain on the right side of 2 months' duration. The patient had no relevant medical history. Pain in the distal third of both quadriceps upon deep palpation was the only relevant finding of physical examination. Blood analysis revealed hemoglobin concentration of 9.2 mg/dL, mean corpuscular volume of 86 fl, hematocrit of 29.2%, and a platelet count of 544 000/ μ L. An initial arterial blood gas analysis revealed a PaCO₂ of 32.2 mm Hg, PaO₂ of 72.7 mm Hg, and oxygen saturation of 97.1%. A chest x-ray showed opacities indicative of alveolar infiltrates in the upper and middle right lobes. The patient was discharged with a diagnosis of pneumonia and normocytic anemia. Amoxicillin/clavulanic acid and

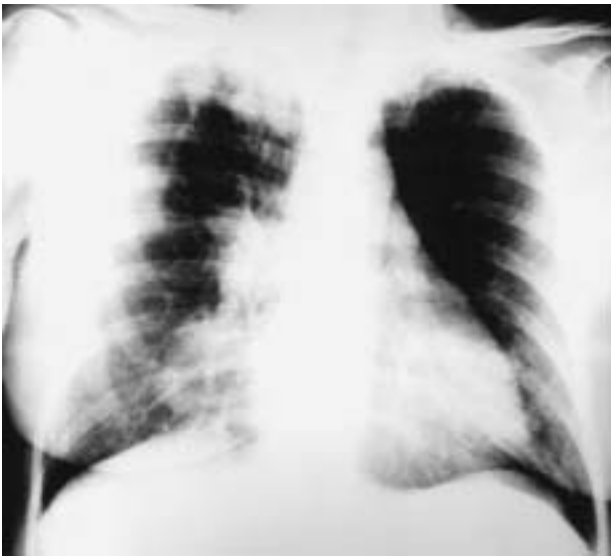

Figure 1. Posteroanterior chest x-ray in which an alveolar infiltrate in the upper right lobe and a lung nodule in the middle lobe can be seen.

clarithromycin were prescribed and she was referred to the outpatient respiratory medicine clinic.

Four days later, she returned to the emergency room with paresthesia and paresis of the upper and lower limbs. Blood tests showed the continued presence of anemia and, in addition, leukocytosis (white cell count 21 210/ μ L, 92% neutrophils). The physical exam revealed skin pallor and rales at the apices of both lung fields, as well as sensorimotor involvement of dermatomes and musculature dependent on the seventh cervical nerve (C7), and, to a lesser extent, on C8 and the first thoracic nerve (T1) on the right side; there was sensory involvement on the left at C7, and neurological deficit at the fifth lumbar-first sacral nerve (L5-S1) involving the lower left limb. Flexion-extension of the wrist and pronation-supination of the forearm was impossible, though sensation was maintained. The extensor digitorum longus and extensor hallucis longus of the lower left limb were affected and the left Achilles reflex was absent. A chest x-ray revealed the continued presence of lung infiltrates (Figure 1), prompting her

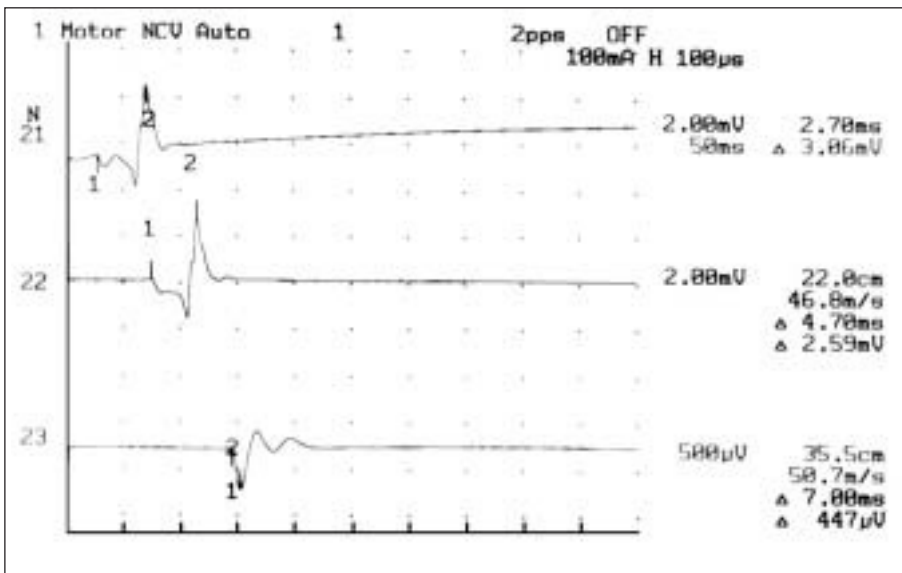


Figure 2. Electromyogram of the right median nerve showing decreased wave amplitude.

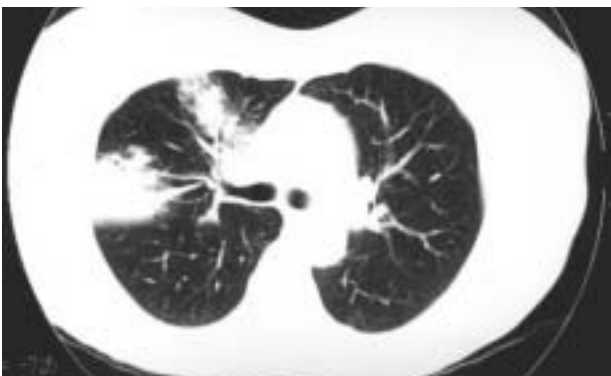

Figure 3. Computed tomography scan showing lung nodules with some areas of cavitation.

admittance to the respiratory medicine ward for further evaluation.

No bone lesions or compressed vertebral bodies were apparent on the x-ray of the spinal column. A computed tomography (CT) scan of the brain was normal and the gadolinium enhanced magnetic resonance image of the lumbar spine showed minimal posterior disk protrusion at L4-L5, without nerve root involvement in that area, as well as diffuse annular disk protrusion at L5-S1, accentuated towards the left side and affecting the left L5 root. The electromyogram of the muscles tested (biceps brachii, triceps brachii, thenar eminence, calf—all on the right side) showed loss of motor units and decreased amplitude, findings indicative of polyradiculitis (Figure 2). Lumbar puncture and analysis of the cerebrospinal

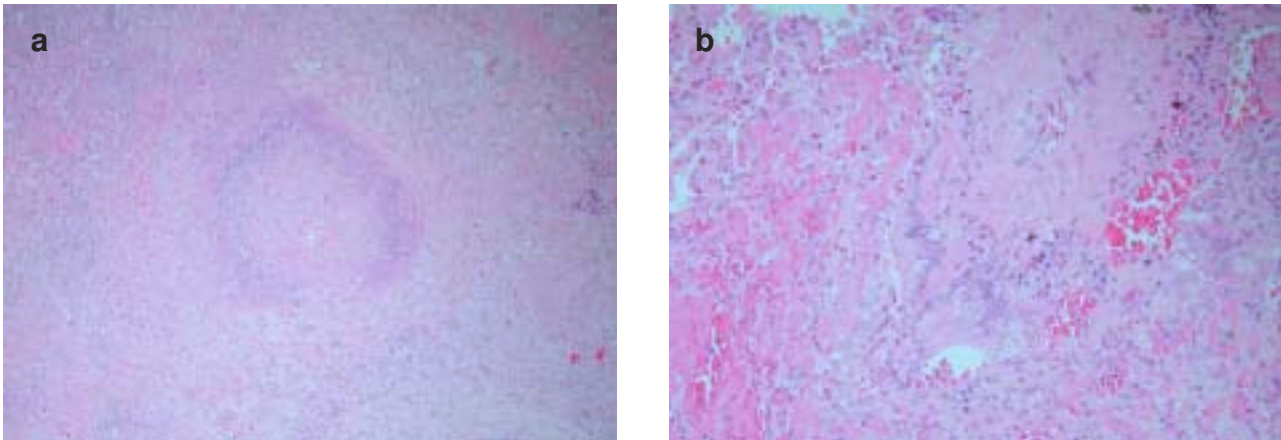


Figure 4. a) Granuloma with central necrosis, palisading histiocytes, and polymorphonuclear leukocytes b) acute vasculitis with polymorphonuclear leukocytes infiltrating a pulmonary artery.

fluid revealed a clear liquid with a glucose level of 54 mg/dL; proteins, 31 mg/dL; red blood cells, 1/μL; and white blood cells, 2/μL. Cytology was negative for malignancy.

The flow-volume curve revealed a forced vital capacity of 1.91 (83%), forced expiratory volume in the first second of 1.62 (84%) and a ratio of forced expiratory volume in the first second to forced vital capacity of 85%. Lung nodules—with poorly defined margins and, in some cases, air bronchogram—involving both upper lobes and the middle right lobe were observed on the intravenous contrast enhanced CT scan of the chest (Figure 3). Serum levels of tumor markers were normal and results of the Mantoux test were negative.

Fiberoptic bronchoscopy ruled out intrabronchial disease. The only finding in the bronchial aspirate sample taken for microbiology and pathology was the presence of acute inflammatory cell markers. Tests for antinuclear antibodies and extractable nuclear antigen (ENA) antibodies were negative. Tests for antineutrophil cytoplasmic antibodies (ANCA) were negative for perinuclear ANCA (p-ANCA), while results for cytoplasmic ANCA (c-ANCA) were positive, with proteinase 3-specific antibody concentrations at 60 U/mL (positive at >20 U/mL). With a diagnosis of suspected systemic vasculitis (Wegener's granulomatosis) and while awaiting results from the lung biopsy, treatment with corticosteroids (prednisone 50 mg/day) and cyclophosphamide (100 mg/day) and neurological rehabilitation was begun.

Video-assisted thoracoscopic biopsy of the right lung confirmed the suspected diagnosis, revealing lung parenchyma with large areas of necrotizing granulomatous inflammation with irregular margins and central necrosis, nuclear fragments, and inflammatory cells surrounded by polymorphonuclear leukocytes, histiocytes, and giant cells. Vasculitis of small and medium sized vessels with inflammatory infiltrates and transmural necrosis, frequently segmental, was observed in the areas adjacent to the granulomas. The

pathological diagnosis was Wegener's granulomatosis (Figure 4).

After treatment was initiated, the respiratory symptoms and peripheral polyradiculopathy improved. At 1 month of treatment, test results were still positive for c-ANCA, but the proteinase 3-specific antibody titers decreased to 20 U/mL. At 2 months they were negative.

Discussion

Wegener's granulomatosis is a systemic vasculitis affecting small and medium sized vessels. Typical inflammatory lesions include necrosis, the formation of granulomas, and vasculitis.¹ Two clinical forms may be distinguished: *a*) classic Wegener's granulomatosis, mainly involving the upper and lower respiratory tracts and the kidneys in the form of glomerulonephritis, and *b*) a limited form without renal involvement, described in 1966 by Carrington and Liebow, that is present in approximately a quarter of patients. Nevertheless, even without the renal component, involvement of organs, such as the lung, heart, digestive system, or central nervous system may be serious and could endanger the life of the patient. Up to one-third of patients with lung impairment may be asymptomatic, as was the case with our patient. Progression of the disease in most patients with untreated or inadequately treated generalized disease is rapid and fatal.²⁻⁴ Wegener's granulomatosis is a rare disease with incidence peaking in middle age, and with men and women affected equally. An annual incidence of 8.5 cases per million and a prevalence of 3 cases per 100 000 have been reported.

Central nervous system involvement has been described in both clinical forms in variable percentages, reaching 54% in some series,^{5,6} but is rare as a presenting manifestation of the disease, as happened with our patient. Peripheral neuropathy and, particularly, mononeuropathy multiplex is the most characteristic

manifestation, although symmetric distal sensorimotor neuropathy, involvement of the paired cranial nerves, external ophthalmoplegia, and cerebral infarction have been described.⁷ The paired cranial nerves most often affected are the optic and oculomotor nerves.^{8,9} Meningeal involvement is rare, however.¹⁰ Pathogenic mechanisms leading to central nervous system involvement in Wegener's granulomatosis include direct invasion from the affected paranasal sinuses, remote effects of the granulomatous inflammation, and vasculitis of the central nervous system.⁹ The extent and reversibility of neurological damage in patients with Wegener's granulomatosis depend on early diagnosis and treatment, which is why knowledge of the natural history of the disease and the techniques that help to establish diagnosis is important.¹¹ In the present case, early pharmacological intervention and intensive rehabilitative treatment led to a progressive and full recovery.

Other vasculitides affecting the central nervous system include polyarteritis nodosa, cutaneous vasculitis, temporal arteritis, lymphomatoid granulomatosis, and Behçet syndrome.¹² Additional diagnostic tests ruled out these diseases in our patient.

In the last decade, the diagnosis of Wegener's granulomatosis has been facilitated by the presence of ANCA. These antibodies are detected by immunofluorescence and two groups are recognized: c-ANCA and p-ANCA. The c-ANCA react with proteinase 3, while the p-ANCA react mostly with myeloperoxidase. Most patients with active Wegener's granulomatosis test positive for ANCA (65%-90%); of these patients, 80%-95% test positive for c-ANCA, while 5 to 20% test positive for p-ANCA.¹³ Therefore, ANCA seem to be useful serological markers for establishing the diagnosis of the underlying disease. Early detection of these antibodies may be of great value in the period before organ damage (particularly of the kidneys and lungs) becomes irreversible. Furthermore, ANCA are useful markers for monitoring the effect of therapy: the antibody concentrations decrease with clinical remission and increase in relapses. However, ANCA alone are insufficient for establishing or excluding a diagnosis of Wegener's granulomatosis because their sensitivity decreases in cases of limited or inactive Wegener's granulomatosis. Moreover, ANCA are associated with other diseases, such as microscopic

polyangiitis; Churg-Strauss syndrome; rheumatic diseases, such as rheumatoid arthritis and lupus; gastrointestinal illnesses, such as ulcerative colitis and regional enteritis. They are also associated with drugs such as hydralazine or minocycline.

A diagnosis of Wegener's granulomatosis is generally confirmed by tissue biopsy of the affected organ. Biopsies of nasopharyngeal lesions, the kidneys, and lungs may be performed. Open lung or thoracoscopic lung biopsy is the technique of choice because the absence of granulomatous vasculitis in the transbronchial tissue biopsy does not rule out diagnosis.¹⁴

REFERENCES

1. Wegener's granulomatosis: prospective clinical and therapeutic experience with 85 patients for 21 years. *Ann Intern Med* 1983; 98:76-85.
2. Steppat D, Gross W. Stage-adapted treatment of Wegener's granulomatosis. *Klin Wochenschr* 1989;67:666-71.
3. Cordier JF, Valeyre D, Guillemin L, Loire R, Brechot JM. Pulmonary Wegener's granulomatosis. A clinical and imaging study of 77 cases. *Chest* 1990;97:906-12.
4. Fonollosa V, Vilardell M. Granulomatosis de Wegener, 1992. *Med Clin (Barc)* 1992;99:57-9.
5. Newman N, Slamovtis T, Friedland S, Wilson W. Neuro-ophthalmic manifestations of meningocerebral inflammation from the limited form of Wegener's granulomatosis. *Am J Ophthalmol* 1995;120:613-21.
6. Kelly PJ, Toke DE, Boyer P, Donald M, Niles J. Granulomatous compressive thoracic myelopathy as the initial manifestation of Wegener's granulomatosis. *Neurology* 1998;51:1769-70.
7. Hoffman GS, Kerr GS, Leavitt RY, Hallahan CW, Lebovics RS, Travis WD, et al. Wegener granulomatosis, an analysis of 158 patients. *Ann Intern Med* 1992;116:488-98.
8. Ojeda E, Belzunegui T, Neira F, Martín L, Martín F, Gutiérrez A. Formas limitadas de la enfermedad de Wegener. Revisión del concepto y diagnóstico diferencial. A propósito de un caso. *Rev Clin Esp* 1985;176:194-8.
9. García Asensio S, Barrena R, Guelbenzu S, Velilla J, Martínez R. Granulomatosis de Wegener con afectación meníngea: correlación clínico-radiológica. *Rev Neurol* 1998;27:833-6.
10. Mamelak A, Nelly W, Davis R, Roseblum M. Idiopathic hypertrophic cranial pachimeningitis. Report of three cases. *J Neurosurg* 1993;79:270-6.
11. Nishino H, Rubino F, De Remeé R, Swanson J, Parisi J. Neurological involvement in Wegener's granulomatosis: an analysis of 324 consecutive patients at the Mayo Clinic. *Ann Neurol* 1993;33:4-9.
12. Weinberger L, Cohen M, Remler B, Naheedy M, Leigh R. Intracranial Wegener's granulomatosis. *Neurology* 1993;43:1831-4.
13. Hoffman GS, Specks U. Antineutrophil cytoplasmic antibodies. *Arthritis Rheum* 1998;41:1521.
14. Schnabel A, Hollulrich K, Dalhoff K, Reuter M, Gross W. Efficacy of transbronchial biopsy in pulmonary vasculitides. *Eur Respir J* 1997;10:2738.