

Effectiveness and Complications of Video-Assisted Surgery for Primary Spontaneous Pneumothorax

A. Gómez-Caro, F.J. Moradiellos, E. Larrú, V. Díaz-Hellín, C. Marrón, J.A. Pérez-Antón, and J.L. Martín de Nicolás

Servicio de Cirugía Torácica, Hospital Universitario 12 de Octubre, Madrid, Spain.

OBJECTIVE: To assess the effectiveness and describe the complications of video-assisted thoracoscopic surgery (VATS) for the treatment of primary spontaneous pneumothorax.

PATIENTS AND METHODS: Between May 1997 and September 2003, our department scheduled 147 VATS procedures for spontaneous pneumothorax in 127 patients (102 men [80.5%]). The mean (SD) age for the series was 28.3 (11.6) years. Bullae and blebs were resected by endostapler and vigorous pleural abrasion was carried out. Vanderschueren staging was as follows: stage I, 10 (6.8%); stage II, 22 (15%); stage III, 71 (48.3%); and stage IV, 44 (29.9%). The procedure was indicated for the following reasons: third episode, 56 (38.1%); persistent air leak, 47 (32%); elective, 16 (10.9%); simultaneous bilateral pneumothorax, 28 (19%). VATS was performed on the right side only in 85 patients (57.8%), on the left in 62 (42.2%), and on both sides in 16 (11.6%).

RESULTS: A total of 137 of the 147 VATS procedures scheduled (93.2%) were performed, and there were no deaths. The rate of conversion to thoracotomy was 6.8%, and the overall rate of complications was 13.7%. Postoperative complications were due to bleeding in 5 cases (3.6%), air leak (>5 days) in 10 (7.2%), wound infection in 2 (1.4%), residual pneumothorax in 4 (2.9%), need to insert a new pleural drain in 3 (2.1%), and pleural empyema in 1 (0.7%). Two patients took oral analgesics for more than 30 days after the procedure. Pneumothorax recurred during follow-up in 7 patients (5.1%). No significant correlation was found between recurrence of pneumothorax after VATS and Vanderschueren stage, age, bilaterality of the procedure, indication, or days of postoperative drainage ($P > .05$).

CONCLUSIONS: VATS for resection of pleural lesions plus pleural abrasion is an efficacious and simple treatment for primary spontaneous pneumothorax regardless of intraoperative findings.

Key words: *Pneumothorax. Video-assisted thoracoscopy. Complications. Recurrence.*

Eficacia y morbilidad del tratamiento con cirugía videoasistida del neumotórax espontáneo primario

OBJETIVO: Evaluar y describir la eficacia y la morbilidad de la VATS (*video assisted toracic surgery* [cirugía torácica videoasistida]) en el tratamiento del neumotórax espontáneo primario (NEP).

PACIENTES Y MÉTODOS: Entre mayo de 1997 y septiembre de 2003 se programaron en nuestro servicio 147 intervenciones por NEP para VATS en 127 pacientes. Las lesiones bullosas se resecaron mediante endograpadoras. Posteriormente se realizó pleuroabrasión vigorosa. La estadificación según Vanderschueren resultó: estadio I, 10 (6,8%); II, 22 (15%); III, 71 (48,3%), y IV, 44 (29,9%). Se intervino a 102 (80,5%) hombres y 25 (19,5%) mujeres. La media de edad fue de $28,3 \pm 11,6$ años. Las indicaciones fueron: tercer episodio, 56 (38,1%); fuga aérea persistente, 47 (32%); cirugía electiva, 16 (10,9%); neumotórax bilateral sincrónico, 28 (19%). Se realizó VATS en el lado derecho en 85 pacientes (57,8%) y en el izquierdo en 62 (42,2%). Se realizó intervención bilateral en 16 (11,6%).

RESULTADOS: Se realizaron 137 VATS (93,2%). No hubo mortalidad y la tasa de reconversión fue del 6,8%. La incidencia de complicaciones fue del 13,7%. La morbilidad postoperatoria fue: sangrado en 5 pacientes (3,6%); fuga aérea (> 5 días) en 10 (7,2%); infección de herida en 2 (1,4%); neumotórax residual en 4 (2,9%); nuevo drenaje torácico en 3 (2,1%), y empiema pleural en 1 (0,7%). Dos pacientes tomaron analgésicos orales durante más de 30 días después del procedimiento. La recurrencia en seguimiento fue de 7 (5,1%). Se analizó el índice de recurrencia post VATS en relación al estadio Vanderschueren, la edad, el carácter bilateral del neumotórax, la indicación o los días de drenaje postoperatorio y no se encontraron diferencias significativas ($p > 0,05$).

CONCLUSIONES: La VATS con resección de lesiones y pleuroabrasión es un método eficaz y sencillo independiente de los hallazgos intraoperatorios para el tratamiento del NPE.

Palabras Clave: *Neumotórax. VATS. Complicaciones. Morbilidad. Recidiva.*

Correspondence: Dr. A. Gómez-Caro.
Servicio de Cirugía Torácica. Hospital Universitario 12 de Octubre.
Ctra. de Andalucía, km 5,4. 28041 Madrid. España.
E-mail: abelitov@yahoo.es

Manuscript received March 1, 2005. Accepted for publication May 3, 2005.

Introduction

Video-assisted thoracic surgery (VATS) is now the procedure of choice for spontaneous pneumothorax in children. The annual incidence rate for this entity is currently 1/100 000 and 7/100 000 in females and

males, respectively,¹ and the rate of recurrence is 20% after a first episode, 60% after a second, and 80% after a third.² Spontaneous pneumothorax is initially treated by thoracic drainage and surgery is reserved for cases of recurrence or persistent air leak.³ When pneumothorax occurs in persons with high-risk occupations, such as deep sea divers, mountain climbers, or pilots, surgery might be scheduled to treat the first episode in order to prevent recurrences.⁴ Certain surgical teams, however, perform VATS regularly to treat the first episode, arguing that doing so requires a shorter hospital stay, fewer days off work, less discomfort caused by thoracic drainage, and therefore a lower overall cost of treatment.⁵ Video technology provides an excellent view of the pleura and lung with minimal invasion and, therefore, less postoperative pain and fewer complications. The success of VATS is related to the shorter operative time and reduction of possible postoperative complications, but it seems that the rate of recurrence is slightly higher after VATS than after open surgery.^{6,7} The aim of this study was to assess the effectiveness and rate of complications after VATS that included lung resection of bullae and pleural abrasion to treat primary spontaneous pneumothorax but without complementary pleural interventions such as pleurectomy or chemical pleurodesis.

Patients and Methods

From May 1997 through September 2003 we performed 147 VATS procedures for primary spontaneous pneumothorax in 127 patients. The case records of those patients were reviewed retrospectively to collect the necessary information for the variables to be analyzed. Computed tomography (CT) of the thorax was not ordered for all patients before surgery. Pneumothorax was bilateral in 19 patients (12.9%). Twenty-five patients (19.5%) were female and 102 (80.5%) were male. The mean (SD) age was 28.3 (11.6) years. Indications for surgery are shown in Table 1. Emergency surgery was performed to treat the first episode in cases of persistent air leak, when there was simultaneous contralateral pneumothorax, or if there was a history of recurrent pneumothorax on the opposite lung. Surgery was not recommended in any cases of a first episode, but it was performed in certain patients based on individual characteristics.

The procedure was on the right lung in 85 cases (57.8%), the left lung in 62 (42.2%), and bilateral in 16 cases (11.6%).

Description of the Procedure

All VATS procedures were carried out under general anesthesia through a double lumen orotracheal tube with the patient in lateral decubitus position on the side opposite the one that was the object of surgery, preparations like those for posterolateral thoracotomy were made. Single lung ventilation was begun before the first skin incision. The first trocar was inserted in the 6th intercostal space 1 to 2 cm from the end of the scapula. A 0° telescope was then inserted through a 10 mm trocar. The next 2 channels were established on the anterior surface, usually in the fourth and 7th intercostal spaces, in function of whether or not pleural adhesions were found. A trocar was or was not used

according to the surgeon's preference. A stapler was used to move the apex of the lung and to staple areas with bullae or fibrosis before they were excised. If no bullae or blebs were found after careful exploration, the apex or the most evidently diseased portion was excised. Intraoperative findings were classified according to the Vanderschueren staging system⁸ (Table 2).

Saline solution was then instilled to check that there were no leaks. If a leak was found, the affected area was excised. Pleurodesis was then accomplished by vigorous abrasion of the parietal pleura, without pleurectomy. Particular attention was given to the apex of the cavity, to anterior and posterior zones, and to the surface adjacent to the diaphragm. The mediastinal surface was not abraded and chemical pleurodesis was not performed. An apical drain (28-French tube) was inserted through an anterior incision and adequate re-expansion of the lung was verified endoscopically. The thoracic drain was connected to a suction pump to give 20 cm H₂O of negative pressure. A 2% solution of bupivacaine was instilled into the working channels without inducing a pleural block. All excised tissue was sent for pathology.

Postoperative Care

The trachea was extubated in the operating room and the patient was observed in the recovery unit for 3 to 6 hours. Postoperative analyses were performed and chest radiographs were taken in that period. Continuous monitoring consisted of pulse oximetry and electrocardiography. The patients were later transferred to the thoracic surgery ward. All patients received a visit from a physiotherapist and performed breathing exercises with an incentive spirometer. The chest tube was withdrawn when the air leak had been repaired, when drainage was less than 150 cm³ daily, and when the lung was fully re-expanded. A leak that lasted longer than 5 days was considered persistent.

Combined intravenous analgesia with nonsteroidal anti-inflammatory drugs and pyrazolones was provided until the drain was removed. Oral medication was then provided as needed. The day after the drain was withdrawn and after radiographic follow-up, the patient was considered for discharge.

TABLE 1
Indications for and Characteristics of the VATS Procedures Performed*

Indications	No. of Cases (%)
Third episode	56 (38.1)
Elective surgery	16 (10.9)
Pneumothorax, not simultaneous bilateral	28 (19)
Persistent air leak	47 (32)
Bilateral procedure	16 (11.6)
VATS, first episode	29 (19.7)

*VATS indicates video-assisted thoracoscopic surgery.

TABLE 2
Vanderschueren Staging and Recurrences

Stage	No.	%	Recurrences
I (no endoscopic findings)	10	6.8	0
II (pleuropulmonary adhesions)	22	15	0
III (blebs/bullae <2 cm)	71	48.3	3
IV (blebs/bullae >2 cm)	44	29.9	4

Follow-up took place in an outpatient clinic for 1 year and was continued by telephone afterwards. All patients were asked about the need to take oral analgesics daily. Chronic pain was recorded on the chart if the patient reported pain or dysesthesia that led to use of analgesics for longer than 30 days.

Statistical Analysis

Statistical analysis of data was carried out with SPSS, version 11. Qualitative variables were compared with the χ^2 test or the Fisher exact test, as appropriate. The confidence level was based on a value of *P* less than .05. The likelihood of recurrence was calculated by the Kaplan-Meier method.

Results

No postoperative deaths occurred. The mean (SD) postoperative stay was 4.2 (4.6) days. The rate of conversion (number of patients who required open surgery) was 6.8% (10 patients). The main cause was the presence of serious pleuropulmonary adhesions (Table 3). The mean duration of surgery was 43.6 (12.3) minutes. The mean number of staples loaded per intervention was 3.4 (3.7). Pleural abrasion was carried out in 98% of the patients. Two adverse events occurred during surgery due to stapler failure. Both required conversion to axillary minithoracotomy because of parenchymal bleeding and the impossibility of performing a new mechanical suture. No intraoperative vascular or pulmonary lesions occurred because of insertion of trocars. The mean duration of thoracic drainage was 2.6 (3.2) days. The drain was removed on the first day after surgery in 73.9% of the cases. The

TABLE 3
Reasons for Conversion to Thoracotomy in Patients Treated by VATS*

Reason for Conversion in 10 Cases (6.8%)	No. (%)
Severe pleuropulmonary adhesions	7 (4.6%)
Pulmonary lesion	1 (0.7%)
Stapler failure	2 (1.4%)

*VATS indicates video-assisted thoracoscopic surgery.

TABLE 4
Complications and Recurrences in Patients Treated by VATS (n=137)*

Complication/Recurrence	No. (%)	Reoperation During Postoperative Recovery	Recurrence
None	111 (81.0%)	—	—
Bleeding	5 (3.6%)	5 (3.6%)	—
Air leak (>5 days)	10 (7.2%)	3 (2.1%)	—
Wound infection	2 (1.4%)	—	—
Residual pneumothorax	4 (2.9%)	—	—
New chest drain	3 (2.1%)	—	—
Long-lasting chronic pain	2 (1.4%)	—	—
Postoperative fever	1 (0.7%)	—	—
Pleural empyema	1 (0.7%)	—	—
Recurrence	7 (5.1%)	—	5 (3.6%)

*VATS indicates video-assisted thoracoscopic surgery.

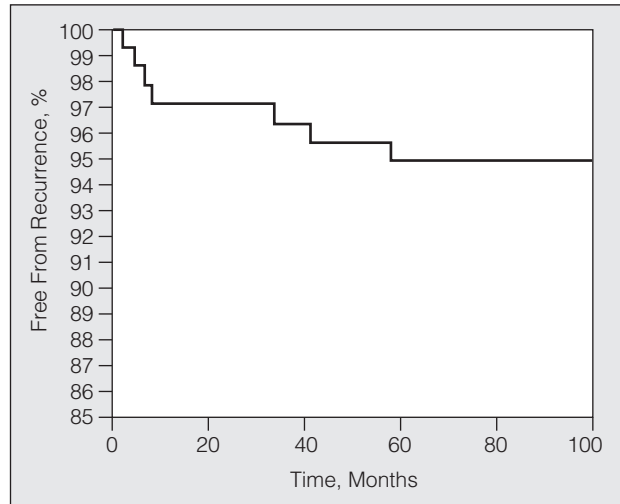


Figure. Patients not experiencing recurrence during the follow-up period, calculated by the Kaplan-Meier method.

rate of postoperative complications was 13.7% (19 cases). Complications and recurrences are shown in Table 4.

Five patients were reoperated before discharge due to bleeding: 3 by VATS and 2 by axillary minithoracotomy. Three more axillary minithoracotomies were necessary to treat persistent air leaks. Patients were followed for a mean 40.5 (22.3) months. The recurrences occurred 2, 4, 8, 41, and 59 months after surgery. The rate of absence of recurrence was calculated (Figure). Recurrence was unrelated to hospital stay, duration (days) of drainage, Vanderschueren stage, bilaterality of the procedure, age, smoking, sex, or any other variable studied (*P*>.05).

The 7 patients (5.1%) who suffered a recurrence were treated by thoracic drainage if appropriate and later by axillary minithoracotomy. Five patients were reoperated. The other 2 patients did not need either a thoracic drain or surgery.

Only 2 patients had chronic pain, although 17 (12.2%) reported continuous use of analgesics for less than 30 days. Lasting pain and a sensation of discomfort was reported by 24 patients (17.4%) who did not require daily analgesics, even though their discomfort continued for several weeks.

Discussion

The outcome of VATS for treating primary spontaneous pneumothorax is similar to treatment by thoracotomy: morbidity rates are similar, hospital stay is shorter after VATS and recovery is earlier.⁹ The recurrence rate, however, seems to be higher for VATS.^{6,10}

The decision to perform VATS is guided by recurrence rates and the procedure is accepted as necessary without a doubt by a third episode.¹¹ Placement of a drainage tube is usually considered acceptable treatment for the first episode, as that approach achieves re-expansion of the lung in 60% to 90% of the cases and much more fluid is drained than is aspirated in fine needle biopsy.¹² Torresini

et al⁵ described a group of patients who underwent VATS for a first episode. Hardly any complications occurred and savings in resources were evident. Less work time was lost and fewer admissions followed—outcomes that made even the greater cost of endoscopic material worthwhile. It would weigh in against taking that approach, however, if we were to take into consideration postoperative pain—which occurs in percentages approaching 30% and is accompanied by dysesthesias, hypoesthesias and referred pain—and if we were to consider the small risk of severe complications.¹³

The rate of postoperative chronic pain was very low in our series, but a larger percentage of patients reported pain and discomfort for several weeks even though they did not feel the need for daily analgesics. The presence of intense postoperative pain seems to be a predictor of more lasting, chronic pain.¹⁴ Analgesic use is less after VATS than after thoracotomy.^{7,15} There appears to be no major effect of using or not using trocars, whether rigid or flexible, to insert direct vision telescopes, although conclusive evidence to that effect is as yet unavailable.¹⁵ Nor is there evidence that the location of working channels has a significant effect on the development of chronic postoperative pain, although the channel most often involved in these situations is a posterior one,¹³ and for that reason we do not use such a channel in our hospital. Chronic pain, in any case, is more common after thoracotomy than after VATS.¹⁵

The duration of postoperative drainage ranges from 1 to 5 (2) days in other series.^{16,17} The difference seems to be related to the number of drains used. We removed drains from our patients without prior repositioning and removal took place the day after surgery in a very high percentage of cases (73.2%). All the cases of recurrence in our series occurred among those patients. Repositioning the drain before removing it and continuing drainage for 4 to 5 days is common practice in the French school, the purpose being to promote formation of stronger adhesions.¹⁸ The incidence of persistent air leak in our series was similar to rates reported for other series with related rates of reoperation and findings.^{4,5,9} Stapler failure occurred in 2 cases and was not detected during VATS.

The most frequently recorded reason for reoperation in this series was postoperative bleeding, which was described in 4 of the 5 cases with severe, extensive adhesions that had to be released. The second VATS was performed in 3 cases to evacuate the clotted hemothorax from the chest and facilitate adequate hemostasis. The 2 axillary minithoracotomies were carried out because of difficulties with single lung ventilation in these patients, but in our judgment the initial approach in such cases would be reoperation by VATS.

The choice of one technique over another one for the treatment of spontaneous pneumothorax is a frequent decision for groups like ours that perform both VATS and pulmonary resection or ligation of bullae with or without pleurectomy and the application of talc depending on intraoperative findings.^{3,4,9,16,19-21}

We used a standard treatment, stapling bullae and providing mechanical pleural abrasion, an approach that has not been shown to have a higher recurrence rate and that avoids complications related to extensive pleurectomy such as postoperative pain, greater risk of bleeding, and transient Horner syndrome.^{2,22} The rate of recurrence in our series was similar to percentages reported for other series in the literature^{16,18} and is no greater than the rates reported for series in which both VATS and pleurectomy were performed.^{3,4} Pleurectomy can be effective, but it is unnecessary for the treatment of spontaneous pneumothorax in our opinion. Although it is used often,^{3,4,19} it is not a guarantee against recurrence.²⁰

Follow-up was longer in our series than in others in the literature,^{3,9,16} as we had records available at 41 and 59 months. We believe that the recurrences within the first 6 months may have been due to technical errors. In our series and in others in the literature,^{9,19,23} recurrences were unrelated to Vanderschueren stage.

Our usual approach to the treatment of recurrences of spontaneous pneumothorax after VATS was not the performance of axillary minithoracotomy. Landreneau et al¹⁵ reported a 1% rate of recurrence after posterolateral thoracotomy and a rate of nearly 4% after VATS, but those authors also underlined the advantages of VATS: less postoperative pain, less need for analgesics in the early postoperative period, and a better esthetic outcome, among others.

We are not in favor of chemical pleurodesis with talc or any other agent. Distributing talc particles in extrapleural tissues and the granulomatous reaction of the pleura itself^{3,9} make subsequent thoracotomy difficult and can lead to respiratory distress. For this reason we are unenthusiastic about the use of talc except in elderly patients who are not candidates for a second high-risk operation. We have a similar opinion of the use of other agents, such as iodopovidone.²⁴

Unlike other groups^{4,5} we did not consider thoracic CT to be absolutely necessary for planning surgery in young patients with primary spontaneous pneumothorax. Therefore we only ordered CT scans when pneumothorax was known or thought to be secondary to another process, in agreement with the practice followed by other authors.³

In conclusion, VATS is an effective, minimally invasive and safe approach for the treatment of primary spontaneous pneumothorax. Pleural abrasion is less invasive than either pleurectomy or talc pleurodesis, although the rate of recurrence is slightly higher for VATS than for thoracotomy. Chronic pain related to the procedure is observed in a minority of patients, fewer after than after open surgery.

REFERENCES

1. Neal JF, Vargas G, Smith DE, Akl BF, Edwards WS. Bilateral bleb excision through median sternotomy. *Am J Surg.* 1979;138:794-7.

2. Chan P, Clarke P, Daniel FJ, Knight SR, Seevanayagam S. Efficacy study of video-assisted thoracoscopic surgery pleurodesis for spontaneous pneumothorax. *Ann Thorac Surg.* 2001;71:452-4.
3. Mouroux J, Elkaim D, Padovani B, Myx A, Perrin C, Rotomondo C. Video-assisted thoracoscopic treatment of spontaneous pneumothorax: technique and results of one hundred cases. *J Thorac Cardiovasc Surg.* 1996;112:385-91.
4. Hatz RA, Kaps MF, Meimarakis G, Loehe F, Muller C, Furst H. Long-term results after video-assisted thoracoscopic surgery for first-time and recurrent spontaneous pneumothorax. *Ann Thorac Surg.* 2000;70:253-7.
5. Torresini G, Vaccarili M, Divisi D, Crisci R. Is video-assisted thoracic surgery justified at first spontaneous pneumothorax? *Eur J Cardiothorac Surg.* 2001;20:42-5.
6. Dumont P, Diemont F, Massard G, Tourmieux B, Wihlm JM, Morand G. Does a thoracoscopic approach for surgical treatment of spontaneous pneumothorax represent progress? *Eur J Cardiothorac Surg.* 1997;11:27-31.
7. Kim KH, Kim HK, Han JY, Kim JT, Won YS, Choi SS. Transaxillary minithoracotomy versus video-assisted thoracic surgery for spontaneous pneumothorax. *Ann Thorac Surg.* 1996; 61:1510-2.
8. Vanderschueren RG. The role of thoracoscopy in the evaluation and management of pneumothorax. *Lung.* 1990;168 Suppl:1122-5.
9. Naunheim KS, Mack MJ, Hazelrigg SR, Ferguson MK, Ferson PF, Boley TM. Safety and efficacy of video-assisted thoracic surgical techniques for the treatment of spontaneous pneumothorax. *J Thorac Cardiovasc Surg.* 1995;109:1198-203.
10. Atta HM, Omar L, Moore J, Caudill R, Snyder A. Thoracotomy versus video-assisted thoracoscopic pleurectomy for spontaneous pneumothorax. *American Surg.* 1997;63:209-11.
11. Cran IR, Rumball CA. Survey of spontaneous pneumothorax in Royal Special Force. *Thorax.* 1967;22:462-5.
12. Andrivet P. Pneumothorax. *Rev Prat.* 2003;53:962-6.
13. Passlick B, Born C, Siemel W, Thetter O. Incidence of chronic pain after minimal-invasive surgery for spontaneous pneumothorax. *Eur J Cardiothorac Surg.* 2001;19:355-8.
14. Katz J, Jackson M, Kavanagh BP, Santana N. Acute pain after surgery predicts long-term post-thoracotomy pain. *Clin J Pain.* 1996;12:50-5.
15. Landreneau RJ, Hazelrigg SR, Mack MJ, Dowling RD, Burke D, Gavlick J. Postoperative pain-related morbidity: video-assisted thoracic surgery versus thoracotomy. *Ann Thorac Surg.* 1993; 56:1285-9.
16. Inderbitzi RG, Leiser A, Furrer M, Althaus U. Three years' experience in video-assisted thoracic surgery (VATS) for spontaneous pneumothorax. *J Thorac Cardiovasc Surg.* 1994;107: 1410-5.
17. Radberg G, Dernevik L, Svanvik J, Thune A. A comparative retrospective study of thoracoscopy versus thoracotomy for the treatment of spontaneous pneumothorax. *Surg Laparosc Endosc.* 1995;5:90-3.
18. Lang-Lazdunski L, Chapuis O, Bonnet PM, Pons F, Jancovici R. Videothoracoscopic bleb excision and pleural abrasion for the treatment of primary spontaneous pneumothorax: long-term results. *Ann Thorac Surg.* 2003;75:960-5.
19. Cardillo G, Facciolo F, Giunti R, Gasparri R, Lopergolo M, Orsetti R, et al. Videothoracoscopic treatment of primary spontaneous pneumothorax: a 6-year experience. *Ann Thorac Surg.* 2000;69: 357-61.
20. Leo F, Pastorino U, Goldstraw P. Pleurectomy in primary pneumothorax: is extensive pleurectomy necessary? *J Cardiovasc Surg (Torino).* 2000;41:633-6.
21. Liu HP, Yim AP, Izzat MB, Lin PJ, Chang CH. Thoracoscopic surgery for spontaneous pneumothorax. *World J Surg.* 1999;23: 1133-6.
22. Deslauriers J, Beaulieu M, Despres JP, Lemieux M, Leblanc J, Desmeules M. Transaxillary pleurectomy for treatment of spontaneous pneumothorax. *Ann Thorac Surg.* 1980;30:569-74.
23. Galbis Caravajal JM, Mafe Madueno JJ, Benlloch CS, Baschwitz GB, Rodríguez Paniagua JM. Videotoracoscopia en el tratamiento del neumotórax: 107 procedimientos consecutivos. *Arch Bronconeumol.* 2003;39:310-3.
24. Estrada SG, Farina RC, Fibla Alfara JJ, Gómez SG, Unzueta MC, León GC. Neumotorax espontáneo: pleurodesis con solución yodopovidomina. *Arch Bronconeumol.* 2003;39:171-4.