

Clinical Image

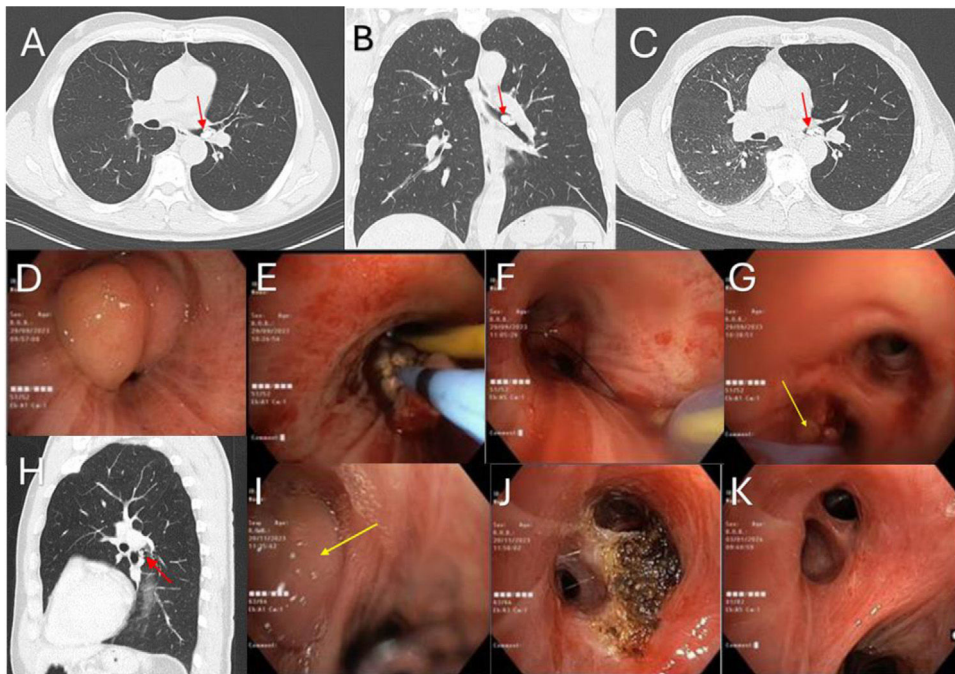
## Endobronchial Hamartoma Resected by Flexible Bronchoscopy: A Complex Approach

Joana Lourenço<sup>a,\*</sup>, Luís Rodrigues<sup>b</sup>, Paulo Matos<sup>b</sup>, Michele Santis<sup>b</sup>, Amélia Estevão<sup>c</sup>, Lourdes Barradas<sup>b</sup>

<sup>a</sup> Pulmonology Department, Pedro Hispano Hospital, Matosinhos Local Health Unit, Oporto, Portugal

<sup>b</sup> Pulmonology Department, Francisco Gentil Portuguese Institute of Oncology of Coimbra, Portugal

<sup>c</sup> Radiology Department, CUF Hospital, Coimbra, Portugal



**Fig. 1.** (A and B) Initial chest computed tomography revealing a lesion (red arrow) at the left main bronchial bifurcation; (C) air entrapment observed in the left lung during expiratory phase in chest computed tomography; (D) endoscopic view of the left main bronchus; (E) bronchial repermeabilization process using cryoablation and argon-plasma coagulation by flexible bronchoscopy; (F) endoscopic view of the left main bronchus after endoscopic resection; (G) endoscopic view inside left b6 segment showing a small remaining lesion (yellow arrow) at a b6 subdivision; (H) chest computed tomography follow-up, 1 month after endoscopic resection, identifying a residual endobronchial lesion (red arrow) at the left b6 segment; (I) endoscopic view of left b6 segment showing a growing lesion (yellow arrow), 2 months after endoscopic resection; (J) endoscopic view inside left b6 segment after the second endoscopic treatment; (K) endoscopic view of left b6 segment, 3 months after the first resection.

A 59-year-old ex-smoker man, presented with progressive dyspnoea and wheezing for several years, interpreted as asthma unresponsive to inhaled therapy. Chest CT (Fig. 1A and B) revealed extensively calcified lesion measuring 17 mm × 9.5 mm at the left main bronchial bifurcation, partially obstructing the lumen, with air entrapment observed in the left lung during expiratory phase (Fig. 1C). First bronchoscopic examination showed a large lobulated and vascularized lesion with a firm consistency, on the superolateral wall of the left main bronchus (Fig. 1D), causing complete obstruction of the bronchial lumen. Bronchial repermeabilization was possible after endoscopic treatment

\* Corresponding author.  
E-mail address: joanacnlorenco@hotmail.com (J. Lourenço).

using a diathermic loop and 1.7 mm cryoprobe (Fig. 1E). Additional haemostatic control was obtained with tangential argon-plasma coagulation (APC) and Arndt endobronchial blocker placed prophylactically. Only a residual lesion remained at a b6 subdivision (Fig. 1F and G). Histology revealed chondroid hamartoma. Follow-up chest CT identified residual endobronchial lesion (Fig. 1H) measuring 7 mm × 5 mm at the left b6 segment and therefore a second bronchoscopy was performed, 2 months after the initial procedure. The residual polypoid lesion (Fig. 1I) was resected with an electrocoagulation loop in combination with a cryoprobe and APC (Fig. 1J). Endobronchial follow-up at 3 months showed no recurrence of the hamartoma (Fig. 1K).

Endobronchial types account for less than 10% of pulmonary hamartomas.<sup>1</sup> Although most pulmonary hamartomas are asymptomatic and found incidentally, endobronchial forms often present with symptoms (persistent cough, wheezing or haemoptysis) and have a higher likelihood of airway obstruction and pneumonia.<sup>2</sup> Differential diagnosis includes malignant tumours and foreign body aspiration. Endoscopic resection of endobronchial hamartomas may present as definitive treatment and is generally performed by rigid bronchoscopy.<sup>1</sup> Nevertheless, in cases involving distal lesions, flexible bronchoscopy may be preferred over traditional rigid bronchoscopy, enabling further techniques such as loop, cryoprobe, APC and endobronchial blocking.<sup>1,3</sup> Guidelines regarding endoscopic follow-up in these cases are insufficient in literature.

## Funding

This research did not receive any specific grant from funding agencies in the public, commercial, or not-for-profit sectors.

## Authors' Contributions

All authors had contributed substantially to obtain the results and preparation of the manuscript in accordance with ICMJE criteria.

## Conflicts of Interest

The authors declare not to have any conflicts of interest that may be considered to influence directly or indirectly the content of the manuscript.

## Artificial Intelligence Involvement

No artificial intelligence software or tool were used to produce the material of this paper.

## References

1. Cardoso CG, Martins M, Souto-Moura C, Fernandes G. Endobronchial hamartoma – a 10-year retrospective analyses of bronchoscopy treatment. *Pulmonology*. 2023;29:89–91, <http://dx.doi.org/10.1016/j.pulmoe.2022.07.002>.
2. Minalyan A, Gopiseti N, Estepa A, Grover H, Patel R. Endobronchial hamartoma as a rare cause of recurrent respiratory symptoms: case report and literature review. *Cureus*. 2019;11:e5489, <http://dx.doi.org/10.7759/cureus.5489>.
3. Suzuki M, Watanabe H, Hashimoto M, Ishii S, Naka G, Iikura M, et al. Endobronchial hamartoma resected via bronchoscopy using high-frequency electrosurgical snare – preoperative strategies using virtual bronchoscopy. *Radiol Case Rep*. 2022;17:4232–8, <http://dx.doi.org/10.1016/j.radcr.2022.08.018>.