

Clinical Letter

Change in Therapeutic Management After Left Adrenal Biopsy With a Single Broncho-Echoendoscopy (EUS-B): Pushing the Envelope

To the Director,

In the staging of lung cancer (LC), several tests are utilized. A computerized tomography (CT) and a positron emission tomography (PET) scans help determine size and extension of the tumor. However, tissue sampling is essential for an accurate diagnosis and therapeutic decision-making.

We present a case in which the therapeutic management and prognosis of a patient were significantly impacted by a broncho-echoendoscopy performed by a pulmonologist (EUS-B).

A 69-year-old active smoker woman was referred to the pulmonary department due to a lung nodule detected on a chest x-ray, requested for catarrhal symptoms.

A CT showed a left upper lobe mass (38 mm × 33 mm). A PET revealed a maximum standard uptake volume value (SUVmax) of 16.63, while the SUVmax in the left adrenal gland (LAG) was 5.41. The nuclear medicine official report indicated a benign etiology rather than neoplastic in the gland. Although there are publications suggesting a lower SUVmax, a cut-off point of 6 is accepted as the threshold above which a malignancy is likely to be its cause.¹

We performed a systematic echobronchoscopy. Three small 4L Lymph nodes (LN) were visualized and biopsied. Despite the PET report, we decided to perform an EUS-B through the esophagus using the same echobronchoscope (EB19-J10U, Pentax). A 13.1 mm nodule was punctured in the LAG (Fig. 1A) using a 22G needle (SonoTip EBUS ProFlex, Medi-Globe). The procedure lasted for 20 min, and no complications were encountered.

The pathological anatomy (PA) of the LAG biopsies was compatible with pulmonary adenocarcinoma metastasis. Molecular analysis was weakly positive for PD-L1 (<50%) (Fig. 1B). The mediastinal 4L LNs were negative for malignancy.

The tumor committees decided to perform an upper left lobectomy followed by a left adrenalectomy. Importantly, the LAG probably would not have been resected but for the diagnosis obtained with EUS-B.

The PA of the lung revealed adenocarcinoma. The analyzed LN (7-11L-12L) were negative for malignancy. The left adrenalectomy PA was consistent with metastasis from lung adenocarcinoma and showed the same PD-L1 levels as the EUS-B samples.

Based on the 8th edition of the TNM classification for LC in effect at the time of diagnosis, the pathologic stage was pT2cN0M1b.

One year after treatment, the patient shows no clinical or imaging evidence of tumor recurrence.

Performing EUS-B to combine mediastinal and extra-thoracic staging during a single endoscopy is feasible and safe² and it is recommended by international guidelines. We have shown that the results obtained by pulmonologists are similar to those obtained by gastroenterologists.³

Adrenal metastases are present in 8% of stage IV LC. The presence of adrenal metastasis without LN involvement (skip metastasis), although less frequent, is associated with a better prognosis than those with LN involvement.⁴

It is important to confirm the location and number of extrathoracic metastasis, especially after the proposed changes in the new 9th edition of the TNM,⁵ as this has implications for the patient's prognosis and management.

In conclusion, EUS-B offers pulmonologists a valuable tool for the detection of malignant lesions in the upper esophago-gastric region in a single procedure. It can reduce the number of invasive procedures typically conducted in the staging of patients with suspected LC.

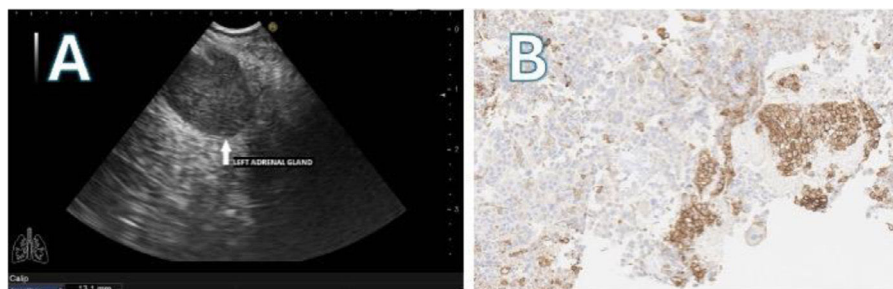


Fig. 1. (A) EUS-B: left adrenal mass (tick arrow). (B) EUS-B-FNA of left adrenal gland: PD-L1 expression.

<https://doi.org/10.1016/j.arbres.2024.04.024>

0300-2896/© 2024 SEPAR. Published by Elsevier España, S.L.U. All rights reserved.

Please cite this article as: J. Cascón-Hernández, L. Fernández-Fernández and F. López-González, Change in Therapeutic Management After Left Adrenal Biopsy With a Single Broncho-Echoendoscopy (EUS-B): Pushing the Envelope, Archivos de Bronconeumología, <https://doi.org/10.1016/j.arbres.2024.04.024>

Authors' contribution

Study concept and design, JCH; Drafting of the manuscript, JCH, LFF, FLG; Critical revision of the manuscript for important intellectual content, JCH, LFF, FLG.

Informed consent

The patient has signed the informed consent form.

Conflict of interests

The authors state that they have no conflict of interests.

Acknowledgments

We would like to thank Bartolome Celli (Brigham and Women's Hospital, Harvard Medical School, Boston, USA) for his work as a scientific advisor.

References

1. Villar JM, Muñoz N, Rodríguez A, Olmos E, Moreno C, Rodríguez R, et al. Diagnostic efficacy and discriminatory capacity of positron emission tomography combined with axial tomography of adrenal lesions. *Cir Esp*. 2010;88:247-52, <http://dx.doi.org/10.1016/j.ciresp.2010.07.007>.

2. Christiansen IS, Ahmad K, Bodtger U, Naur TMH, Sidhu JS, Nessar R, et al. EUS-B for suspected left adrenal metastasis in lung cancer. *J Thorac Dis*. 2020;12:258-63, <http://dx.doi.org/10.21037/jtd.2020.01.43>.
3. Cascón JA, Cordovilla R, Iglesias M, González JM, Álvarez A, Guevara V, et al. Usefulness of endoscopic ultrasound performed by pulmonologists in lung cancer. *Eur Respir J*. 2019;54:PA4771, <http://dx.doi.org/10.1183/13993003.congress-2019.PA4771>.
4. Gao XL, Zhang KW, Tang MB, Zhang KJ, Fang LN, Liu W. Pooled analysis for surgical treatment for isolated adrenal metastasis and non-small cell lung cancer. *Interact Cardiovasc Thorac Surg*. 2017;24:1-7, <http://dx.doi.org/10.1093/icvts/ivw321>.
5. Fong KM, Rosenthal A, Giroux DJ, Nishimura KK, Erasmus J, Lievens Y, et al. The IASLC lung cancer staging project: proposals for the revision of the m descriptors in the forthcoming 9th edition of the TNM classification of lung cancer. *J Thorac Oncol*. 2024, <http://dx.doi.org/10.1016/j.jtho.2024.01.019>. S1556-0864(24)00060-1.

Juan Cascón-Hernández^{a,*}, Luis Fernández-Fernández^b,
Francisco López-González^a

^a *Interventional Pulmonology Unit, Department of Respiratory Medicine, Hospital Universitario Central de Asturias, Oviedo, Spain*
^b *Pathology Department, Hospital Universitario Central de Asturias, Oviedo, Spain*

Corresponding author.

E-mail address: jcasconh@gmail.com (J. Cascón-Hernández)

✉ [@jcasconh](https://twitter.com/jcasconh) (J. Cascón-Hernández).