

Clinical Image

Late Unexpected Pneumopericardium Due to Pleuro-pericardial Atrial Perforation by Pacemaker Lead



Ana María Gómez-Gago*, Begoña de las Heras-Marqués, Florencio Quero-Valenzuela

Servicio de Cirugía Torácica, Hospital Universitario Virgen de las Nieves, Granada, Spain

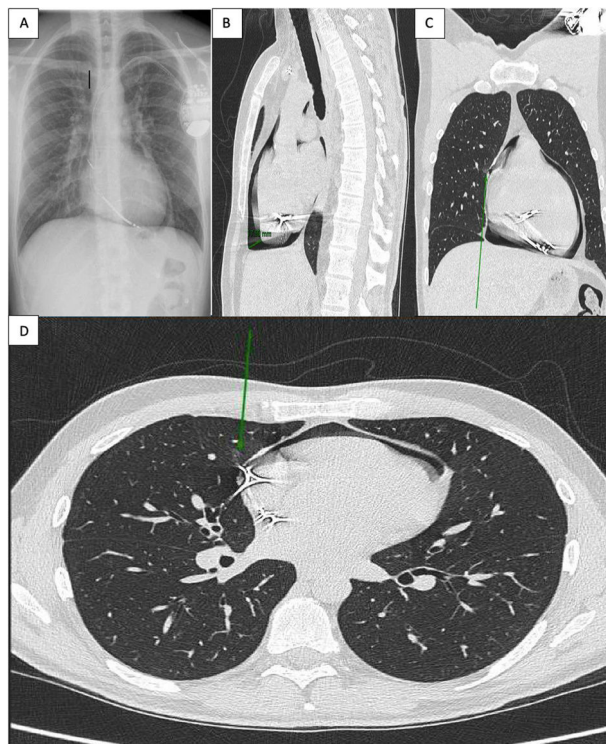


Fig. 1. Posterolateral chest radiography (A). Sagittal section chest computed tomography (B). Coronal and cross-section chest computed tomography (C and D) showing atrial and pleural perforation by pacemaker lead (arrows).

Thirty-eight-year-old patient with previous history of pacemaker insertion one year ago, as consequence of toxic dilated cardiomyopathy following chemotherapy for non-Hodgkin lymphoma. After pacemaker placement, a chest X-ray was performed with no immediate complications. One year later he presents to the emergency department with acute chest pain and bubbling sensation during exercise, not previously reported. A chest X-ray was performed showing pneumopericardium (Fig. 1A).

Chest CT scan confirmed the presence of moderate pneumopericardium (Fig. 1B) secondary to pleural and cardiac perforation by pacemaker lead (Fig. 1C and D arrows).

Treatment consisted of removal and replacement of atrial lead.

* Corresponding author.

E-mail address: anagomezgago@gmail.com (A.M. Gómez-Gago).

Pneumopericardium is a rare complication usually resulting of myocardium perforation by pacemaker lead entering lung parenchyma and establishing communication between the lung and pericardial space.¹

Late development of pneumopericardium has only been documented in previous history of cardiac surgery and persisting pleuro-pericardial fistula.² Late development of pneumopericardium after pacemaker implantation is therefore a particularly rare complication and potentially life-threatening.

Funding

This article did not receive any specific grant from funding agencies in the public, commercial, or not-for-profit sectors.

Conflicts of Interests

The authors declare not to have any conflicts of interest that may be considered to influence directly or indirectly the content of the manuscript.

References

1. Goel R, Winchester DE, Austin C, Staples ED. Pneumopericardium develops after pacemaker implantation. *Tex Heart Inst J*. 2021;48:e197093, <http://dx.doi.org/10.14503/THIJ-19-7093> [PMID: 34665870; PMCID: PMC8717756].
2. Parahuleva M, Schifferings P, Neuhof C, Tillmanns H, Erdogan A. Pneumopericardium and pneumomediastinum as a late complication of defibrillator implantation after coronary artery bypass graft surgery. *Thorac Cardiovasc Surg*. 2009;57:491–3, <http://dx.doi.org/10.1055/s-2008-1039221> [PMID: 20013626].