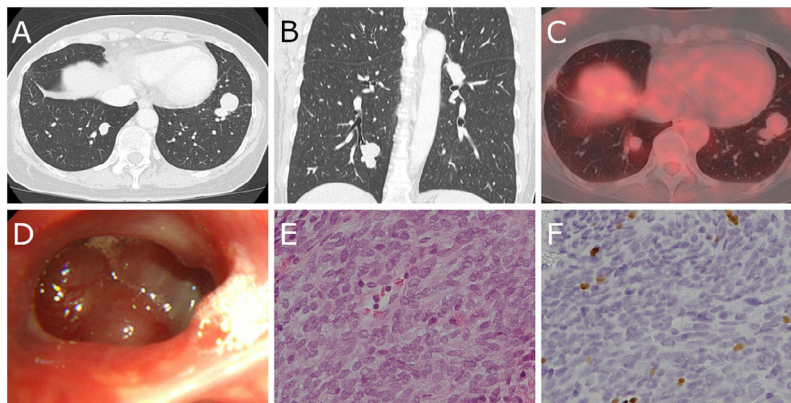


## Clinical Image

# Bronchoscopic Diagnosis of Hematogenous Recurrence of Thymoma

Miki Tasato, Akihiko Sokai\*, Takashi Nishimura

Department of Respiratory Medicine, Kyoto Katsura Hospital, 17 Yamadahirao-cho, Nishikyo-ku, Kyoto 615-8256, Japan



**Fig. 1.** (A and B) Computed tomography shows bilateral nodules. (C) Positron emission tomography-computed tomography shows the tumors have little uptake of  $^{18}\text{F}$ -fluorodeoxyglucose. (D) Bronchoscopic examination shows a tumor with smooth edges in right B10. (E and F) Histopathology reveals that the tumor is composed of proliferating spindle cells and infiltrating T cells which are positive for terminal deoxynucleotidyl transferase (TdT) (E: H/E staining,  $\times 20$ , F: TdT staining,  $\times 20$ ).

A 57-year-old woman was referred to our hospital for multiple nodules in the bilateral lower lung fields of a chest X-ray image. Her medical history included surgery for ruptured type A thymoma 15 years previously, and follow-up had been completed with no recurrence for more than five years post-surgery. Computed tomography demonstrated several nodules of various sizes in multiple lobes (Fig. 1A and B), which exhibited little uptake of  $^{18}\text{F}$ -fluorodeoxyglucose on positron emission tomography-computed tomography (Fig. 1C). The tumors were suspected to be metastases, despite these examinations having revealed no primary tumor. Bronchoscopy found a tumor with smooth edges in right B10 (Fig. 1D), from which a biopsy was performed. Histopathology revealed that the tumor was composed of proliferating spindle cells and infiltrating T cells which were positive for terminal deoxynucleotidyl transferase (Fig. 1E and F). Thus, the tumors were diagnosed as a recurrence of thymoma. The patient underwent surgical resection of several lung metastases twice at another institution. A few metastatic tumors that were difficult to resect continue to be followed up.

Thymoma recurrence after surgery occurs in less than half of the patient population, and most recurrences appear in the form of pleural dissemination.<sup>1,2</sup> Surgery for pulmonary metastases of thymoma, which are relatively rare, can be an option.<sup>3</sup> Complete resection of recurrent thymoma can result in a favorable outcome.<sup>4,5</sup> In the present case, although rare, the tumors which were suspected to be hematogenous metastases could be observed and diagnosed by bronchoscopy examination as a recurrence of thymoma. Due to the long duration of recurrence, the patient underwent surgical resections twice, albeit incomplete resections.

## Funding

None.

## Conflict of interest

The authors have no conflicts of interest to declare.

\* Corresponding author.  
E-mail address: [sokai.med@gmail.com](mailto:sokai.med@gmail.com) (A. Sokai).

## Acknowledgements

We would like to thank Dr. Shinsuke Shibuya (Department of Diagnostic Pathology, Kyoto Katsura Hospital) for pathological evaluations and Prof. Masaaki Sato (Department of Thoracic Surgery, University of Tokyo Hospital) for surgical treatment.

## References

1. Haniuda M, Kondo R, Numanami H, Makiuchi A, Machida E, Amano J. Recurrence of thymoma: clinicopathological features, re-operation, and outcome. *J Surg Oncol*. 2001;78:183–8, <http://dx.doi.org/10.1002/jso.1146>.
2. Sandri A, Cusumano G, Lococo F, Alifano M, Granone P, Margaritora S, et al. Long-term results after treatment for recurrent thymoma: a multicenter analysis. *J Thorac Oncol*. 2014;9:1796–804, <http://dx.doi.org/10.1097/jto.0000000000000370>.
3. Hirono M, Nonaka M, Himuro N, Tomita Y, Kataoka D, Kadokura M. Two cases of thymoma with pulmonary metastasis: a case report. *World J Surg Oncol*. 2014;12:114, <http://dx.doi.org/10.1186/1477-7819-12-114>.
4. Girard N, Ruffini E, Marx A, Faivre-Finn C, Peters S. Thymic epithelial tumours: ESMO Clinical Practice Guidelines for diagnosis, treatment and follow-up. *Ann Oncol*. 2015;26 Suppl. 5:v40–55, <http://dx.doi.org/10.1093/annonc/mdv277>.
5. Chiappetta M, Grossi U, Sperduti I, Margaritora S, Marulli G, Fiorelli A, et al. Which is the best treatment in recurrent thymoma? A systematic review and meta-analysis. *Cancers (Basel)*. 2021;13, <http://dx.doi.org/10.3390/cancers13071559>.