

Clinical Image

Spontaneous Haemothorax and Diffuse Pleural Thickening as Unusual Presentations of Undifferentiated Large Cell Carcinoma of the Lung

Celia Cabrero-Rodríguez^{a,*}, María José Antona-Rodríguez^a, Ana Isabel Parejo-Morón^b

^a Servicio de Neumología, Hospital Universitario de Jaén, Jaén, Spain

^b Servicio de Medicina Interna, Hospital Universitario Clínico San Cecilio, Granada, Spain

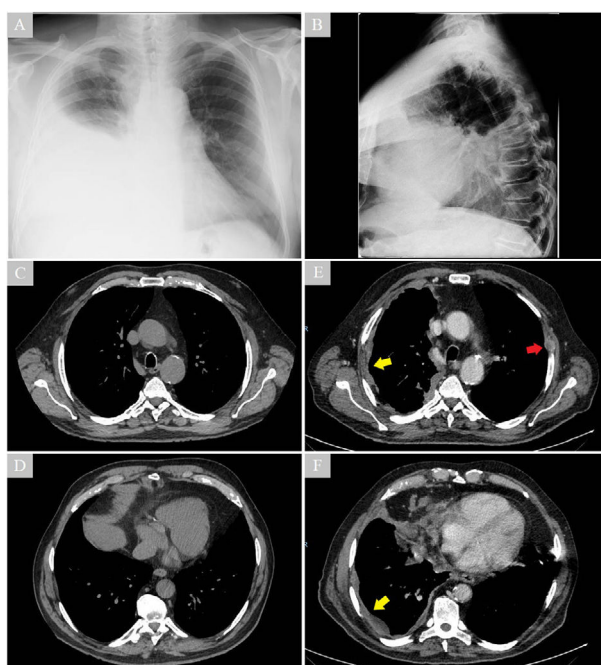


Fig. 1. The images show the evolution of the radiological findings over six months. CT scan performed six months prior to admission, with no findings (C and D). Chest X-ray with a right pleural effusion performed when the patient consulted the emergency department (A and B). Diffuse right pleural thickening (yellow arrows) and lytic lesion in the left fourth costal arch (red arrow) after drainage of the pleural effusion (E and F).

A 72-year-old ex-smoker male was admitted due to dyspnoea and chest pain, showing right pleural effusion (Fig. 1A and B) that was not found on chest CT scan conducted 6 months earlier (Fig. 1C and D). Clinical observations included haemothorax

after placement of a pleural drainage tube with 2000 ml of fluid output. Moreover, the chest CT scan showed right diffuse irregular nodular pleural thickening and costal lytic lesion (Fig. 1E and F). He was transferred to the Thoracic Surgery Department, where videothoracoscopy was performed. During the surgery, coagulated haematic effusion and multiple pleural tumour mamelons were observed. Definitive diagnosis of undifferentiated large cell carcinoma was determined using pleural biopsy. SMARCA-4 deficiency was excluded.

The histological subtype diagnosed is the third most common lung cancer, which has no clear differentiation and a diverse presentation. Spontaneous haemothorax is a rare pathology that includes neoplasms, especially metastases of gonadal tumours and sarcomas, as one of its causes. A case of diffuse pleural thickening has been published presenting this subtype¹ and another case revealing spontaneous haemothorax due to large cell carcinoma.² This is the first time that both clinical forms are reported in the literature.

Conflict of Interests

The authors state that they have no conflict of interests.

References

1. Nakamura H, Ikeda I, Nakahama H, Sugita M. Large-cell carcinoma presenting as diffuse thickening of the pleura and resembling malignant mesothelioma. *Nihon Kyobu Shikkan Gakkai Zasshi*. 1997;35:451–4.
2. Ausín P, Gómez-Caro A, Pérez Rojo R, Moradiellos F, Díaz-Hellín V, Martín de Nicolás J. Hemotórax espontáneo por carcinoma broncogénico. *Arch Bronconeumol*. 2005;41:400–1. <http://dx.doi.org/10.1157/13076972>.

* Corresponding author.
E-mail address: celiarodriguez93@gmail.com (C. Cabrero-Rodríguez).