

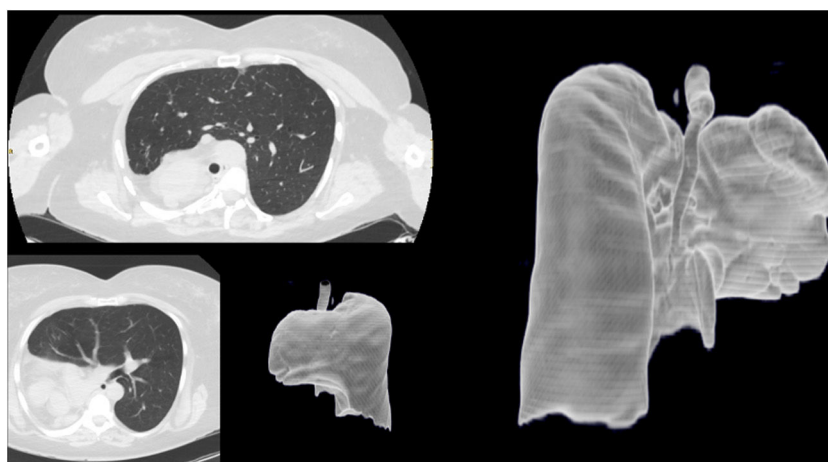
## Clinical Image

# A Silent Pulmonary Agenesis

Manuel David Viñuales-Aranda<sup>a,\*</sup>, Jorge Rodríguez-Sanz<sup>a</sup>,  
Ricardo Ignacio Gomez-Miranda<sup>b</sup>

<sup>a</sup> Department of Pulmology, Hospital Universitario Miguel Servet, Zaragoza, Spain

<sup>b</sup> Department of Radiology, Hospital Universitario Miguel Servet, Zaragoza, Spain



**Fig. 1.** Computed tomography revealed complete agenesis of the right lung with compensatory hyperinflation of the left lung.

## Description

The term «agenesia» is interpreted as complete lack of lung formation.<sup>1</sup> Pulmonary agenesis can be very rarely diagnosed in adults and it is usually associated with infectious or respiratory symptoms. In addition, right lung agenesis has a worse prognosis.<sup>2</sup>

We present a 49-year-old woman with exposure to 2 pack-years of cigarette smoking, asthma and scoliosis.

She was referred to us to assess that condition. Her clinical presentation had always been typical of a healthy individual, without breathlessness, wheezing nor any signs of bronchial obstruction or respiratory insufficiency.

The computed tomography reported a complete agenesis of the right lung and right pulmonary veins, and right main artery stump is observed. There is a compensatory hyperinflation of the left lung which herniates through the anterior mediastinum (Fig. 1).

She has undergone many diagnostic procedures; the patient has a 71% of diffusing capacity of the lungs for carbon monoxide, which when is related to ventilation rises up to 103%, again, suitable for a healthy individual. The performance of stress tests, nevertheless, has revealed a slightly impaired ventilatory and cardiac performance to exercise, with a fast recovery.

## References

1. Field CE. Pulmonary agenesis and hypoplasia. *Arch Dis Child.* 1946;21:61–75.
2. Cherian SV, Kumar A, Ocazonez D, Estrada-Y-Martin RM, Restrepo CS. Developmental lung anomalies in adults: a pictorial review. *Respir Med.* 2019;155:86–96.

\* Corresponding author.

E-mail address: [manuel.vinuales@hotmail.com](mailto:manuel.vinuales@hotmail.com) (M.D. Viñuales-Aranda).