



## Case Report

## Digenic Inheritance in a Case of Pulmonary Arterial Hypertension Associated with Two Incidental Septal Defects and Multiple Thoracic Collaterals


 Alejandro Cruz-Utrilla<sup>a,\*</sup>, María Pilar Escribano Subias<sup>a,b</sup>, Jair Antonio Tenorio Castaño<sup>c,d,e</sup>,  
 María Jesús del Cerro Marín<sup>f,g</sup>
<sup>a</sup> Pulmonary Hypertension Unit, Cardiology Department, Hospital Universitario 12 de Octubre, Madrid, Spain

<sup>b</sup> Centro de Investigación Biomédica en Red en Investigación Cardiovascular (CIBERCV), Instituto de Salud Carlos III, Madrid, Spain

<sup>c</sup> Instituto de Genética Médica y Molecular (INGEMM), Hospital Universitario La Paz, Madrid, Spain

<sup>d</sup> CIBERER, Centro de Investigación en Red de Enfermedades Raras, Instituto de Salud Carlos III, Madrid, Spain

<sup>e</sup> ITHACA, European Reference Network on Rare Congenital Malformations and Rare Intellectual Disability, Brussels, Belgium

<sup>f</sup> Pediatric Cardiology Department, Ramón y Cajal University Hospital, Madrid, Spain

<sup>g</sup> Instituto Ramón y Cajal de Investigación Sanitaria (IRYCIS), Madrid, Spain

A 10-year-old male with progressive dyspnea was diagnosed of Pulmonary Arterial Hypertension (PAH) related to a small atrial septal defect (ASD) (Fig. 1, panel A) and a restrictive perimembranous ventricular septal defect (Fig. 1, panel B). The initial right heart catheterization demonstrated suprasystemic pulmonary artery pressure (138% of systemic pressures), right to left shunting (Qp/Qs 0.4), indexed pulmonary vascular resistance of 39 Wood Units/m<sup>2</sup>, and a transpulmonary gradient of 76 mmHg. On triple sequential therapy with Tadalafil, Macitentan and subcutaneous Treprostinil, a Lenus implantable pump for intravenous Treprostinil was implanted at his 26 years. At that time, oral anticoagulation was also introduced. Despite progressive dilatation of the right chambers and persistent suprasystemic pulmonary pressures, the patient remained in functional class II until 28, when he was admitted due to an episode of life-threatening hemoptysis. After stabilization, a pulmonary angiography and an angio-CT were done, in which multiple thoracic collaterals were noticed (Fig. 1, panels C and D). One bronchopulmonary collateral was actively bleeding, and an embolization was then performed. The patient responded favorably and was discharged, withdrawing Acenocoumarin. On maximum vasodilator therapy, without new hemoptysis episodes, the patient has remained at high-risk stratum. Nevertheless, considering the presence of multiple collaterals in the mediastinum and the pleura, the patient has recently been considered not candidate for bilateral lung transplantation or heart-lung transplantation at his 29 years of age.

Shortly after diagnosis, the index-case parents consented his inclusion in the Spanish Registry for pediatric pulmonary hypertension (REHIPED).<sup>1</sup> A genetic test was performed when he was 28,

as part of a research study in patients in that registry, revealing two significant variants among candidate genes related with the development of PAH (*SMAD1* and *ABCC8*). Both variants were classified as likely pathogenic initially by the *in vitro* analysis.<sup>2</sup> The evaluation of first-degree relatives revealed the presence of the *SMAD1* variant in the 30-year-old asymptomatic sister and the father of the index case. This last individual underwent an ASD closure at the age of 30 due to right chambers dilatation. After the segregation studies, the variant was maintained as likely pathogenic. The *ABCC8* was a rare *de novo* variant, not previously described in the literature, and not present in other first-degree relatives, which permitted in this case the reclassification of the variant as pathogenic (Fig. 1, panel E).

Genetic testing for PAH-associated candidate genes can be considered for patients with CHD and “out of proportion” PAH.<sup>3</sup> The genetic background of such cases, in which the size of the defect unlikely explains the severity of vascular disease, should be taken into account, not only when shunt closure is considered or for genetic counseling, but also in the evaluation for lung transplantation. Certain mutations are associated with widespread collateral vessels.<sup>4</sup> Specifically, *SOX17* variants have been related with PAH-CHD, with high prevalence of thoracic collaterals.<sup>5</sup> Although genetics have not demonstrated a prognostic value in PAH, the presence of gene variants could be associated with specific phenotypes and management implications, as demonstrated in this rare case with a digenic inheritance.

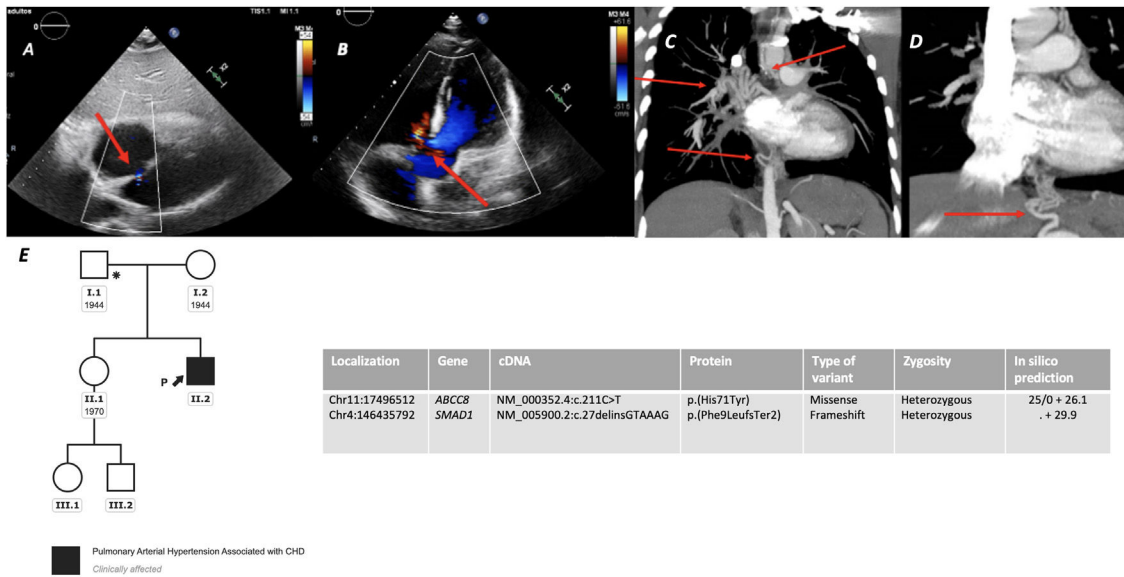
### Author contribution

Substantial contributions to the conception or design of the work; or the acquisition, analysis, or interpretation of data for the work: ACU, PES, JTC, MJC.

Drafting the work or revising it critically for important intellectual content: ACU, PES, JTC, MJC.

\* Corresponding author.

E-mail address: [acruzutrilla@gmail.com](mailto:acruzutrilla@gmail.com) (A. Cruz-Utrilla).



**Fig. 1.** Panel A. Incidental atrial septal defect detected in TTE, showing right-to-left shunting (red arrow); Panel B. Small perimembranous ventricular septal defect (VSD) with Left-to-right shunting during systole (red arrow); Panels C and D. Reconstruction of some of the thoracic collaterals noticed in the mediastinum in the angiographic computed tomography (red arrows); Panel E. Genetic analysis and segregation study of first-degree relatives.

Final approval of the version to be published: ACU, PES, JTC, MJC. Agreement to be accountable for all aspects of the work in ensuring that questions related to the accuracy or integrity of any part of the work are appropriately investigated and resolved: ACU, PES, JTC, MJC.

**Funding**

This project was funded by project “Bases Genético-Moleculares de la Medicina de Precisión en la Hipertensión Arterial Pulmonar” and “Moving toward to a omic classification for pulmonary arterial hypertension”. Instituto de Salud Carlos III, Ministerio de Economía y Competitividad, Gobierno de España. Co-funded by “Fondo Europeo de Desarrollo Regional, Programa Operativo Crecimiento Inteligente 2014–2020” (<https://www.isciii.es/Paginas/Inicio.aspx>). Award number: PI 18/01233, PI21-01593, and PI21-01690. A.C.U. holds a research-training contract “Rio Hortega” (CM20/00164) from the Spanish Ministry of Science and Innovation (Instituto de Salud Carlos III).

**References**

1. Del Cerro Marín MJ, Sabaté Rotés A, Rodríguez Ogando A, Mendoza Soto A, Quero Jiménez M, Gavilán Camacho JL, et al. Assessing pulmonary hypertensive vascular disease in childhood. Data from the Spanish registry. *Am J Respir Crit Care Med.* 2014;190:1421–9.
2. Lago-Docampo M, Tenorio J, Hernández-González I, Pérez-Olivares C, Escribano-Subías P, Pousada G, et al. Characterization of rare ABCC8 variants identified in Spanish pulmonary arterial hypertension patients. *Sci Rep.* 2020;10:15135, <http://dx.doi.org/10.1038/s41598-020-72089-1>.
3. Pattathu J, Gorenflo M, Hilgendorff A, Koskenvuo JW, Apitz C, Hansmann G, et al. Genetic testing and blood biomarkers in paediatric pulmonary hypertension. Expert consensus statement on the diagnosis and treatment of paediatric pulmonary hypertension. The European Paediatric Pulmonary Vascular Disease Network, endorsed by ISHLT and DGPK. *Heart.* 2016;102 Suppl 2:ii36–41.
4. Cruz-Utrilla A, Gallego N, Segura de la Cal T, Tenorio-Castaño J, Arribas-Ynsaurriaga F, Escribano Subias P. The role of genetics in pulmonary arterial hypertension associated with congenital heart disease. *Rev Esp Cardiol (Engl Ed).* 2021;74:884–6.
5. Montani D, Lechartier B, Girerd B, Eyries M, Ghigna MR, Savale L, et al. An emerging phenotype of pulmonaryarterial hypertension patients carrying SOX17 variants. *Eur Respir J.* 2022, <http://dx.doi.org/10.1183/13993003.00656-2022>.