

Case Report

Thoracic Mazabraud's Syndrome: Unusual Location

Carmen María Rodríguez Gómez*, Roser Saumench Perramon, Xavier Baldó Padró

Department of Thoracic Surgery, Hospital Universitario Dr. J Trueta de Girona, Spain



Mazabraud's syndrome (MS) is a rare benign disorder characterized by the association of single or multiple intramuscular myxomas (IM) with fibrous dysplasia (FD), which can develop in a single bone (monostotic) or in multiple bones (polyostotic).¹

In general, the onset of FD predates the appearance of the IM, and the soft-tissue lesions become apparent many years later, usually in the fifth or sixth decade of life. The disease is more frequent in women and patients are often asymptomatic. However, complications such as skeletal deformities, fractures and pain can occur.²

We present a case of a 60-year-old woman who underwent a right thoracotomy at the age of 35 and resection of the posterior arches of several right ribs (6th–8th and 11th) for bone deformation in the chest assessed by CT scan performed for pain after a car accident. The affected segments were resected and defect was repaired with a Marlex's prosthesis. The anatomopathological result was FD ribs.

25 years later, two lesions dependent on soft tissues, appear in the same area of the previous resected ribs. Magnetic resonance imaging (MRI) reports the presence of two intramuscular soft tissue expansive lesions at the level of D11 (upper lesion 44 mm × 26 mm and lower lesion 50 mm × 36 mm), hypointense on T1 and hyperintense on T2 with an edematous perilesional component due to expansion (Fig. 1). A complete resection of these lesions was carried out. The histological result was IM. The postoperative course was uneventful. After 2 years of follow-up, the patient remains disease-free.

The first case of MS was described by Henschen in 1926.² The etiology is unknown, but is believed to be caused by point mutations in the GNAS-1 gene.³ Fewer than 100 cases have been reported in recent literature.⁴ MS typically manifests as a polyostotic FD with multiple IM appearing close by. MS has a predisposition for females (68%) and often involves the long bones of the lower limbs bilaterally.⁴

In the MRI myxomas demonstrate a sharply defined contour, low signal intensity on T1-weighted images and high signal intensity on T2-weighted images and STIR images. Sometimes there is a ring of perilesional fat and edema in the adjacent muscles. CT scans typically display a homogeneous, well-circumscribed mass

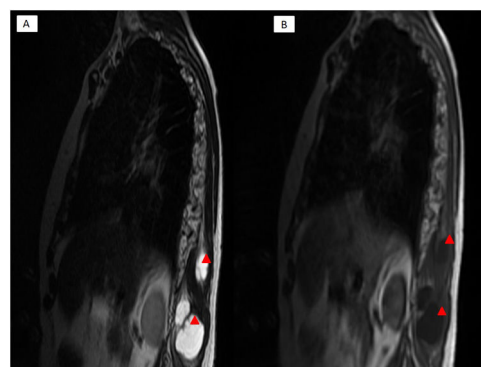


Figure 1. MRI reports the presence of two intramuscular myxomas (IM) hypointense on T1 (B) and hyperintense on T2 (A).

with low attenuation.⁵ The image findings in our patient were in agreement with previously described.

Myxomas are benign soft-tissue tumors. There have been no reported cases of malignant transformation of myxomas so that conservative management is indicated. Myxomas should be excised if pain or pressure symptoms develop. Simple local excision is sufficient in most cases. FD progresses slowly but surgical intervention is also indicated for severe and progressive disease with persistent pain, skeletal deformity or pathological fracture.¹ The presence of IM does not influence the severity or progression of FD.

Postoperative follow-up of MS should be undertaken to detect other myxomas that may not yet be clinically detectable or local recurrences of IM after incomplete resection.

Therefore, our case is considered of special interest due to the low prevalence of MS and costal location to emphasize the importance of recognizing in the diagnosis and appropriate management of the patient.

Funding

No external financing has been needed for this study.

Conflict of interests

No conflict of interests for this specific case report.

* Corresponding author.
E-mail address: mia.2612@hotmail.com (C.M. Rodríguez Gómez).

References

1. Van der Wal WA, Unal H, de Rooy JW, Flucke U, Veth RP. Fibrous dysplasia of bone associated with soft-tissue myxomas as well as an intra-osseous myxoma in a woman with mazabraud's syndrome: a case report. *J Med Case Rep.* 2011; 5:239.
2. Henschen F. Fall von ostitis fibrosa mit multiplen tumoren in der umgebenden muskulatur. *Verh Dtsch Ges Pathol.* 1926;21:93–7.
3. Okamoto S, Hisaoka M, Ushijima M, Nakahara S, Toyoshima S, Hashimoto H. Activating gs(alpha) mutation in intramuscular myxomas with and without fibrous dysplasia of bone. *Virchows Arch.* 2000;437:133–7.
4. Multani I, Popovic S, Parasu N, Ghert M. Case reports in orthopedics, vol 2019, Article ID 2638478, 5 pp.
5. Iwasko N, Steinbach LS, Disler D, Pathria M, Hottya GA, Kattapuram S, et al. Imaging findings in mazabraud's syndrome: seven new cases. *Skeletal Radiol.* 2002;31:81–7.