

Clinical Image

[Translated article] Lung Cancer With Thoracic Wall Involvement

Masa pulmonar con extensión a pared torácica

Irene Nieto-Codesido*, Carmen Diego Roza

Servicio de Neumología, Complejo Hospitalario Universitario de Ferrol, Ferrol, A Coruña, Spain

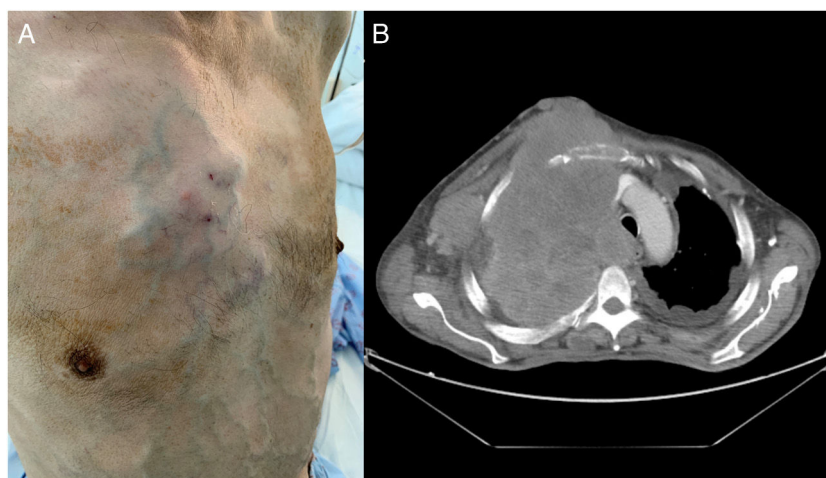


Fig. 1. (A) Frontolateral view of the chest with tumor caused by lung mass, showing secondary collateral circulation. (B) Thoracic CT slice with extensive infiltrating mass.

Our patient was a 61-year-old man, active smoker with a history of occupational exposure to asbestos, who consulted for a 3-month history of constitutional symptoms, progressive increase in dyspnea, and growth of a painful mass in the anterior chest wall. Physical examination revealed the presence of a right parasternal tumor of a stony consistency and significant collateral circulation over the chest and abdomen (Fig. 1A).

Chest CT revealed the presence of a mass that occupied almost all the right lung, with extrathoracic invasion and growth, as well as bilateral pleural involvement, bilateral pulmonary nodules, and pathological lymphadenopathies. The mass was compressing the tracheal, esophageal, and mediastinal vasculature, causing thrombosis of the superior vena cava from its origin to its entrance into the right atrium, causing collateral circulation in the chest wall (Fig. 1B). Fine needle puncture and aspiration of the

cervical lymphadenopathic conglomerate and thoracic mass confirmed the diagnosis of pleomorphic carcinoma. This neoplasm is a type of poorly differentiated non-small cell lung cancer that is contained within sarcomatoid lung tumors, and accounts for less than 1% of all malignant lung tumors. It usually occurs in male smokers and is characteristic for its large size and chest wall involvement in more than 25% of cases. The prognosis is bleak, with a 5-year survival of approximately 20%.

Further reading

1. Kim TH, Kim SJ, Ryu YH, Lee HJ, Goo JM, Im JG, et al. Pleomorphic carcinoma of lung: Comparison of CT features and pathologic findings. *Radiology*. 2004;232:554–9.
2. Travis WD. Sarcomatoid neoplasms of the lung and pleura. *Arch Pathol Lab Med*. 2010;134:1645–58. <http://dx.doi.org/10.5858/2010-0086-RAR.1>.

DOI of original article: <https://doi.org/10.1016/j.arbres.2022.01.008>

* Corresponding author.

E-mail address: irene.nieto.codesido@gmail.com (I. Nieto-Codesido).

<https://doi.org/10.1016/j.arbres.2022.01.024>

0300-2896/© 2022 SEPAR. Published by Elsevier España, S.L.U. All rights reserved.