



Case Report

Acute Eosinophilic Pneumonia Following mRNA COVID-19 Vaccination: A Case Report



Neumonía eosinofílica aguda tras la administración de la segunda dosis de una vacuna de tipo ARNm contra la COVID-19: a propósito de un caso

Miguel Barrio Piqueras^a, Ana Ezponda^a, Carmen Felgueroso^b, Cesar Urtasun^a,
Isberling Madeleine Di Frisco^b, Javier Carlos Larrache^a, Gorka Bastarrika^{a,*}, Ana Belén Alcaide^{b,*}

^a Department of Radiology, Clínica Universidad de Navarra, Pamplona, Spain

^b Department of Pulmonary Medicine, Clínica Universidad de Navarra, Pamplona, Spain

A previously healthy 37-year-old male was admitted to hospital after two days of mild fever, dyspnea, wheezing, oppressive chest pain, dry cough, palpitations and arthromyalgia that started just 8–10 h after the second dose of Pfizer-BioNTech COVID-19 vaccine. The chest X-ray showed multilobar and coalescent alveolar opacities. Serial negative nasopharyngeal swab reverse transcriptase-polymerase chain reaction (RT-PCR) tests ruled out SARS-CoV-2 infection. Unenhanced chest CT performed a few hours after admission revealed bilateral ground glass opacities (GGO) and consolidation with interlobular septal thickening, peribronchial cuffing, and mild bilateral pleural effusion (Fig. 1). The analysis of bronchoalveolar lavage (BAL) allowed to rule out infection and showed differential cell count of 60.3% eosinophils. These findings suggested an acute eosinophilic pneumonia (AEP). Blood eosinophils gradually increased during the hospitalization ($0.7\text{--}4.13 \times 10^9/\text{L}$). Due to the spontaneous clinical improvement, the patient was discharged five days after admission.

AEP is an eosinophilic lung disease characterized by the sudden onset of respiratory symptoms that often occur in healthy young individuals.^{1,2} The characteristic histopathological finding of AEP is eosinophilic infiltration in the alveolar and interstitial spaces. The mechanism for the overproduction and accumulation of eosinophils is unknown, although cytokines (interleukin 5), may play an important role.

AEP can be diagnosed with the modified Pilit criteria⁴: (1) acute respiratory illness ≤ 1 month of duration; (2) typical radiological features; (3) pulmonary eosinophilia of more than 25% eosinophils in BAL fluid (increased percentages of lymphocytes and neutrophils could be found) or eosinophilic pneumonia

on lung biopsy and (4) absence of other specific pulmonary eosinophilic diseases. Imaging findings include patchy or diffuse pulmonary opacities with interlobular septal thickening and mild to moderate pleural effusion.³ Lung biopsy is not usually required. Individuals with AEP can present neutrophilic leukocytosis without eosinophilia in peripheral blood in early stages of the disease. In many cases, the eosinophil count in peripheral blood increases during the following days.² Treatment of AEP consists of systemic corticosteroids after ruling out an infectious cause of pulmonary eosinophilia. In some cases, AEP can improve spontaneously.¹

In our patient, the diagnosis of AEP was established based on the radiological findings, the absence of a concurrent infection, and the increased eosinophil count in the BAL fluid. Given the sudden and rapid onset of patient's symptoms within hours of the second dose of the vaccine, we believe that mRNA-based COVID-19 vaccine triggered the eosinophilic response, similar to some other viral infections or drugs.

Previous studies have reported AEP following the administration of vaccines, including influenza vaccination⁵ and the 23-valent-pneumococcal-polysaccharide vaccine.⁶ A recently published case report describes AEP following COVID-19 vaccination with adenovirus vaccine AZD1222.⁷ Interstitial lung diseases associated to COVID-19 mRNA vaccination have also been reported.⁸ Here, we report the first case of AEP following mRNA COVID-19 vaccination confirmed by BAL. Definitive proof of the direct link between this condition and the mRNA based COVID-19 vaccine is still uncertain and further investigation is needed to prove causation.

* Corresponding authors.

E-mail addresses: bastarrika@unav.es (G. Bastarrika), abalcaide@unav.es (A.B. Alcaide Ocaña).

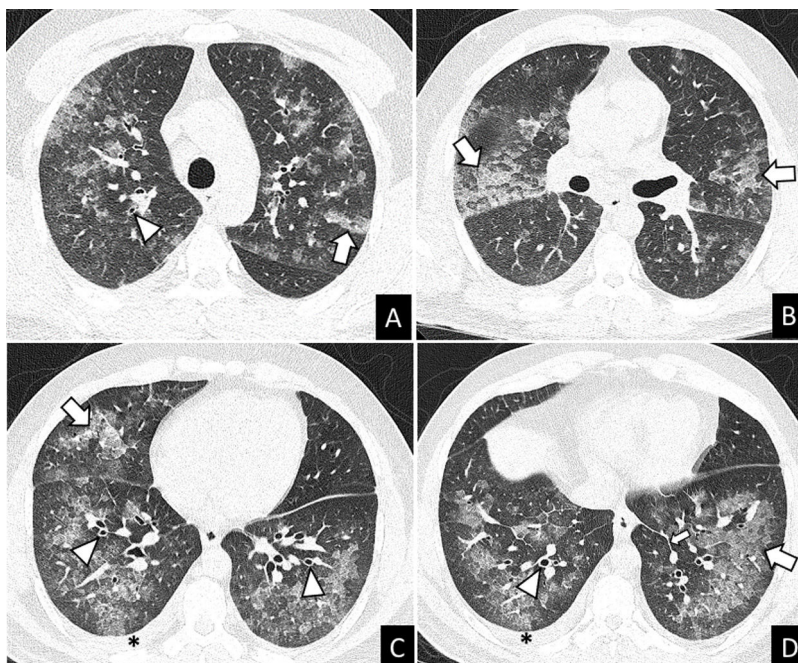


Fig. 1. Unenhanced chest-CT. (A–D) Axial views. The CT scan showed bilateral ground glass opacities (GGO) and consolidation with smooth interlobular septal thickening (arrows), peribronchovascular thickening (arrowheads), and mild bilateral pleural effusion (asterisks).

Authors' contribution

The above listed authors attest that they made substantial contributions to the (1) conception and design, acquisition of data, or analysis and interpretation of data; (2) drafting the article or revising it critically for important intellectual content; and (3) final approval of the version to be submitted for revision. All authors had full access to all the data in the study and accept responsibility for the submission of this work.

Acknowledgements

None.

References

- De Giacomi F, Vassallo R, Yi ES, Ryu JH. Acute eosinophilic pneumonia. Causes diagnosis, and management. *Am J Respir Crit Care Med.* 2018;197:728–36, <http://dx.doi.org/10.1164/rccm.201710-1967CI>.
- Bernheim A, McLoud T. A review of clinical and imaging findings in eosinophilic lung diseases. *AJR Am J Roentgenol.* 2017;208:1002–10, <http://dx.doi.org/10.2214/AJR.16.17315>.
- Daimon T, Johkoh T, Sumikawa H, Honda O, Fujimoto K, Koga T, et al. Acute eosinophilic pneumonia: thin-section CT findings in 29 patients. *Eur J Radiol.* 2008;65:462–7, <http://dx.doi.org/10.1016/j.ejrad.2007.04.012>.
- Rhee CK, Min KH, Yim NY, Lee JE, Lee NR, Chung MP, et al. Clinical characteristics and corticosteroid treatment of acute eosinophilic pneumonia. *Eur Respir J.* 2013;41:402–9, <http://dx.doi.org/10.1183/09031936.00221811>.
- Pornsuriyasak P, Suwatanapongched T, Klaewsongkram J, Buranapraditkun S, Rotjanapan P. Acute respiratory failure secondary to eosinophilic pneumonia following influenza vaccination in an elderly man with chronic obstructive pulmonary disease. *Int J Infect Dis.* 2014;26:14–6, <http://dx.doi.org/10.1016/j.ijid.2014.04.019>.
- Kikuchi R, Iwai Y, Watanabe Y, Nakamura H, Aoshiba K. Acute respiratory failure due to eosinophilic pneumonia following pneumococcal vaccination. *Hum Vaccin Immunother.* 2019;15:2914–6, <http://dx.doi.org/10.1080/21645515.2019.1631134>.
- Miqdadi A, Herrag M. Acute eosinophilic pneumonia associated with the anti-COVID-19 vaccine AZD1222. *Cureus.* 2021;13:e18959, <http://dx.doi.org/10.7759/cureus.18959>.
- Park JY, Kim JH, Lee IJ, Kim HI, Park S, Hwang YI, et al. COVID-19 vaccine-related interstitial lung disease: a case study. *Thorax.* 2021, <http://dx.doi.org/10.1136/thoraxjnl-2021-217609>.