

Clinical Image

Pneumothorax: A Rare Complication of Septic Pulmonary Embolism Due to Muscular Abscesses

Neumotórax: una complicación infrecuente del embolismo pulmonar séptico debido a abscesos musculares

Veysel Ayyildiz^a, Yasemin Ogul^b, Hayri Ogul^{c,d,*}

^a Department of Radiology, Medical Faculty, Suleyman Demirel University, Isparta, Turkey

^b Department of Biochemistry, Erzurum Training and Research Hospital, Erzurum, Turkey

^c Anesthesiology, Clinical Research Office, Ataturk University, Erzurum, Turkey

^d Department of Radiology, Medical Faculty, Ataturk University, Erzurum, Turkey

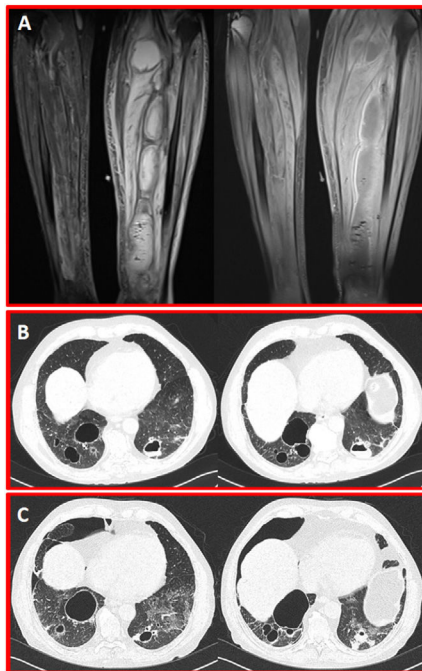


Fig. 1. (A) Coronal proton density and postcontrast T1-weighted MR images show giant intramuscular abscesses in the posterior of the left cruris. (B) Axial CT scans in parenchyma window show multiple cavitary septic embolisms in both lungs. (C) Control CT scans five days after from the presentation scan reveal the right pneumothorax secondary to septic embolism.

A 74-year-old man with membranous glomerulonephritis was admitted to our hospital with left calf pain and swelling. The patient had no immunosuppressive treatment. His body temperature was 39.5 °C, and blood pressure was 75/55 mmHg. Laboratory tests

revealed the following: white blood cell count, 23,000 cells/mm³; hemoglobin, 14.7 g/dL; platelet count, 127,000 cells/mm³; creatinine, 1.13 mg/dL; C-reactive protein, 97 mg/dL; and D-dimer, >35 μg/mL. Echocardiography showed no presence of heart valves' vegetations. To examine calf inflammation, magnetic resonance imaging (MRI) was performed. The MRI showed formation of giant intramuscular abscesses in the posterior side of the left cruris (Fig. 1A). Percutaneous drainage was performed for the calf abscess. The cultures of blood and abscess content revealed the presence of methicillin-resistant *Staphylococcus aureus*. Intravenous vancomycin was administered as the antibiotic treatment. That patient began showing productive cough with purulent sputum. Chest computed tomography (CT) showed different images of septic pulmonary embolism in both lungs (Fig. 1B). Shortness of breath appeared five days after the commencement of the treatment. The control CT scan revealed the right pneumothorax (Fig. 1C). The pneumothorax resolved spontaneously within ten days.

Septic pulmonary embolism due to muscular abscesses is a rare condition. However, its incidence has increased in immunocompromised patients. Pneumothorax is an uncommon life-threatening complication of septic pulmonary embolism.¹ Septic pulmonary embolisms in immunocompromised patients have a potential risk for pneumothorax

Conflict of interest

The authors declare that the article content was composed in the absence of any commercial or financial relationships that could be construed as a potential conflict of interest.

Reference

- Okabe M, Kasai K, Yokoo T. Pneumothorax secondary to septic pulmonary emboli in a long-term hemodialysis patient with psoas abscess. *Intern Med.* 2017;56:3243–7.

* Corresponding author.

E-mail address: drhogul@gmail.com (H. Ogul).