

respiratory infection which in turn can lead to Acute Respiratory Discomfort Syndromes (ARDS). In addition to a diffuse alveolar damage with severe inflammatory exudation, patients with COVID-19 can present immunosuppression with decreased CD4+T and CD8+ T cells.⁶ This clinical scenario opens the door for the development of coinfections by opportunistic microorganisms. Within this context, different published reports have shown the importance of assistant doctors and laboratory specialists in verifying the occurrence of potential coinfections, such as aspergillosis, candidiasis, mucormycosis, or cryptococcosis that could lead to co-morbidities in patients with COVID-19.⁷

The incidence of invasive infections caused by opportunistic fungal species has increased in recent decades. These fungi are normally difficult to diagnose, resistant to many antifungals, and are associated with high mortality rates.⁸ In the 1980s, the invasive *Trichosporon* infection was considered the second most common cause of fungemia among immunosuppressed patients who also suffered from hematological diseases, hemochromatosis, end-stage renal disease, or who were on a long-term corticosteroid treatment. Depending on the age, underlying conditions, presence of neutropenia, and clinical treatments, the mortality rates of patients suffering from an invasive trichosporonosis infection can range from 30% to 90%.^{9–11} Until now, our case is the first report that shows a *Trichosporon* infection in a COVID-19 patient.

In conclusion, we report a case of a triple pulmonary coinfection in an immunocompetent patient with severe SARS-CoV-2 pneumonia. As the pandemic continues to spread around the world, other reports to assess the frequency of emergent and reemerging highly resistant bacterial and fungal coinfections in individuals suffering from COVID-19 are needed. These coinfections impose severe complications in COVID-19 patients that might lead to death due to the aggravation in the primary viral condition.

Ethics declarations

The present study was approved by the Ethics Committee of the Fundación Jiménez Díaz Health Research Institute (EO102-20-HRJC). Due to the pandemic situation, informed consent was not requested from the patients. Personal information and data obtained from the subjects were kept confidential.

Conflict of interest

The authors declare that they have no known competing financial interests or personal relationships that could have appeared to influence the work reported in this paper.

Acknowledgements

We acknowledge Dr. Barbara Hissa for critical reading and scientific editing of the manuscript. This work was supported by the

Brazilian agencies Conselho Nacional de Desenvolvimento Científico e Tecnológico (CNPq), Coordenação de Aperfeiçoamento de Pessoal de Nível Superior (CAPES) – Finance Code 001 and Fundação Carlos Chagas Filho de Amparo à Pesquisa do Estado do Rio de Janeiro (FAPERJ).

Bibliografía

1. Calabrese F, Pezzuto F, Fortarezza F, Hofman P, Kern I, Panizo A, et al. Pulmonary pathology and COVID-19: lessons from autopsy. The experience of European Pulmonary Pathologists. *Virchows Arch*. 2020.
2. Lai CC, Shih TP, Ko WC, Tang HJ, Hsueh PR. Severe acute respiratory syndrome coronavirus 2 (SARS-CoV-2) and coronavirus disease-2019 (COVID-19): the epidemic and the challenges. *Elsevier B.V.*; 2020.
3. Chen N, Zhou M, Dong X, Qu J, Gong F, Han Y, et al. Epidemiological and clinical characteristics of 99 cases of 2019 novel coronavirus pneumonia in Wuhan, China: a descriptive study. *Lancet*. 2020;395:507–13.
4. Rodriguez-Tudela JL, Alastruey-Izquierdo A, Gago S, Cuenca-Estrella M, León C, Miro JM, et al. Burden of serious fungal infections in Spain. *Clin Microbiol Infect*. 2015;21:183–9.
5. de Almeida JN, Hennequin C. Invasive trichosporon infection: a systematic review on a re-emerging fungal pathogen. *Frontiers Media S.A.*; 2016.
6. Lu Q-B, Jiang W-L, Zhang X, Li H-J, Zhang X-A, Zeng H-L, et al. Comorbidities for fatal outcome among the COVID-19 patients: a hospital-based case-control study. *J Infect*. 2020:1–4.
7. Song G, Liang G, Liu W. Fungal co-infections associated with global COVID-19 pandemic: a clinical and diagnostic perspective from china. *Mycopathologia*. 2020;185:599–606.
8. Chagas-Neto TC, Chaves GM, Colombo AL. Update on the genus trichosporon. *Mycopathologia*. 2008;166:121–32.
9. Walsh TJ, Groll A, Hiemenz J, Fleming R, Roilides E, Anaissie E. Infections due to emerging and uncommon medically important fungal pathogens. *Clin Microbiol Infect*. 2004;10:48–66.
10. Kontoyiannis DP, Torres HA, Chagua M, Hachem R, Tarrand JJ, Bodey GP, et al. Trichosporonosis in a tertiary care cancer center: risk factors, changing spectrum and determinants of outcome. *Scand J Infect Dis*. 2004;36:564–9.
11. Liao Y, Lu X, Yang S, Luo Y, Chen Q, Yang R. Epidemiology and outcome of Trichosporon Fungemia: a review of 185 reported cases from 1975 to 2014. *Open Forum Infect Dis*. 2015;2:10.

Gonzalo Segrelles-Calvo^{a,b}, Glauber R. De S. Araújo^c, Estefanía Llopis-Pastor^a, Susana Frases^{c,*}

^a Servicio de Neumología, Hospital Universitario Rey Juan Carlos, Madrid, Spain

^b Instituto de Investigación Biomédica, Fundación Jiménez Díaz, Madrid, Spain

^c Laboratório de Biofísica de Fungos, Instituto de Biofísica Carlos Chagas Filho, Universidade Federal do Rio de Janeiro, Rio de Janeiro, RJ, Brazil

Corresponding author.

E-mail address: susanafrases@biof.ufrj.br (S. Frases).

<https://doi.org/10.1016/j.arbres.2020.11.007>

0300-2896/© 2020 SEPAR. Published by Elsevier España, S.L.U. All rights reserved.

Costocondritis y espondilitis diferidas por *Candida* en paciente post-COVID-19 tratado previamente con corticoides, antibióticos y tocilizumab



Delayed Candida Costochondritis and Spondylitis in a Post-COVID-19 Patient Previously Treated With Corticosteroids, Antibiotics, and Tocilizumab

Estimado Director:

Una proporción significativa de los pacientes con formas moderadas o graves de la infección por SARS-CoV-2 requieren ingreso

en Unidades de Cuidados Intensivos (UCI)^{1,2}. Los ingresos prolongados en las UCI son un factor de riesgo conocido para el desarrollo de infecciones nosocomiales por *Candida* spp.^{3,4} Aunque no está del todo demostrado si los pacientes con COVID-19 tienen una incidencia de infecciones por *Candida* spp. mayor que otros pacientes, algunos trabajos recientes sugieren que presentan un riesgo mayor de candidemia que otras cohortes retrospectivas no-COVID-19⁵. Además de los factores de riesgo conocidos para el desarrollo de una candidemia en pacientes ingresados en una UCI, debe tenerse en cuenta que la frecuente combinación de fármacos inmunosupresores (corticoides), antibióticos de amplio espectro y de inhibidores del receptor de la interleucina-6 (IL-6), en pacientes

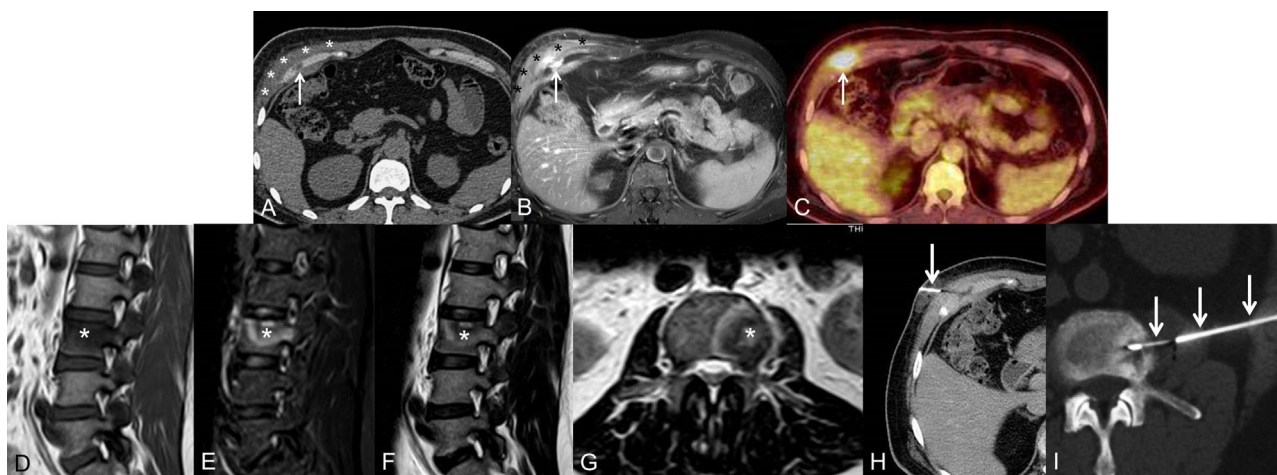


Figura 1. A) y B) Imágenes axiales de TC (A) y de RM (B), que muestran una lesión focal que afecta al cartilago del séptimo arco costal anterior derecho (flecha) y un aumento de partes blandas perilesional (asteriscos). C) Imagen axial de PET/TC en la que se observa un foco hipermetabólico en el cartilago del séptimo arco costal anterior derecho (flecha). D) a G) Imágenes sagitales potenciadas en T1 (D), STIR (E) y T2 (F) y axial potenciada en T2 (G) de RM de columna vertebral lumbar, en las que se identifica una lesión focal ósea en el platillo vertebral superior izquierdo del tercer cuerpo vertebral lumbar (asterisco). H) Biopsia con aguja gruesa (flecha), con control radiológico de la lesión focal del cartilago del séptimo arco costal anterior derecho con control radiológico. I) Biopsia con aguja gruesa (flechas), con control radiológico de la lesión focal ósea del tercer cuerpo vertebral lumbar.

con infecciones graves por SARS-CoV-2 puede aumentar el riesgo de infecciones nosocomiales por *Candida* spp.⁶⁻⁸ Presentamos el caso de un paciente post-COVID-19 que desarrolló, cuatro meses después de un ingreso en UCI por una infección grave por SARS-CoV-2, dos focos infecciosos por *Candida albicans* de forma diferida en el sistema musculoesquelético, los cuales fueron tratados de forma conservadora.

Se trata de un varón de 53 años que consultó en Urgencias de nuestro hospital por dolor torácico y lumbar, y en quien se detectó, en la exploración física, una masa dolorosa palpable en hemitórax anterior derecho. El paciente había estado ingresado cuatro meses antes por una infección respiratoria grave por SARS-CoV-2, que requirió ingreso en la UCI con ventilación mecánica durante 10 días. Por lo demás, no tenía antecedentes médicos significativos. Durante el ingreso en la UCI, el paciente fue tratado, entre otros fármacos, con antibióticos (azitromicina y ceftriaxona), corticoides (80 mg/24 h durante la estancia en UCI) y tocilizumab (dos dosis de 600 mg), y desarrolló una candidemia asociada al uso de catéter intravenoso, que fue tratada con retirada del catéter y antifúngicos. Dados estos antecedentes, se decidió ingresar al paciente desde Urgencias. Las radiografías de tórax y de columna lumbar no mostraron alteraciones significativas, pero en varias pruebas de imagen (TC, RM y PET/TC), se detectó un aumento de partes blandas rodeando el séptimo cartilago costal anterior y una lesión focal ósea en el cuerpo de la tercera vértebra lumbar (fig. 1A-G). Una biopsia con aguja gruesa de ambas lesiones descartó la posibilidad de una neoplasia y confirmó una infección (costocondritis y espondilitis) por *Candida albicans* polisensible (fig. 1H-I). El paciente está siendo tratado con antifúngicos (fluconazol 800 mg/24 h durante seis meses) y analgésicos, sin requerir tratamiento quirúrgico, por el momento, de los dos focos infecciosos.

No está clara si la incidencia de candidemia en pacientes con COVID-19 es mayor que en otros grupos de pacientes, aunque algunos trabajos recientes sugieren que en pacientes con COVID-19, la candidemia es más frecuente que en cohortes históricas no-COVID-19⁵. Los pacientes con infección grave por SARS-CoV-2 ingresados en la UCI presentan muchos de los factores de riesgo asociados para desarrollar una candidemia, pero se desconoce si su incidencia es mayor o menor que en otros grupos de pacientes⁹. A los factores de riesgo conocidos para desarrollar una candidemia en pacientes ingresados (como un score de la clasificación *Acute Physiology and Chronic Health Evaluation* [APACHE] elevado en la UCI, dia-

betes, insuficiencia renal, utilización de antibioterapia de amplio espectro y/o de terapia inmunosupresora [como los corticoides], nutrición parenteral, presencia de catéteres vasculares centrales, y la ventilación mecánica invasiva) hay que añadir el uso de los inhibidores del receptor de IL-6, como el tocilizumab, en el tratamiento de los pacientes con COVID-19, que parece aumentar el riesgo de infecciones por *Candida* spp.⁶⁻⁸ Si bien hemos encontrado varios trabajos recientes que describen candidemias durante el ingreso en UCI, nuestro paciente presentó además, como complicación diferida cuatro meses después del ingreso en UCI, una costocondritis y una espondilitis fúngica (ambas confirmadas microbiológicamente, tras obtención de muestras tisulares percutáneas con control radiológico), que fueron detectadas con diferentes técnicas de imagen y exitosamente tratadas (por el momento) con tratamiento antifúngico. No hemos encontrado ningún caso de infección diferida por *Candida* spp. del sistema musculoesquelético en pacientes post-COVID-19 (la mayor parte de los casos publicados únicamente presentaron candidemia, salvo un paciente que desarrolló una endoftalmítis y otro una endocarditis⁶). Igualmente, no hemos encontrado ningún caso en la literatura en la que una costocondritis por *Candida* spp. se haya manejado sin tratamiento quirúrgico¹⁰⁻¹³.

Creemos que este caso refleja una complicación fúngica diferida multifocal, no descrita previamente en un paciente post-COVID-19 que presentaba factores de riesgo para candidemia. El diagnóstico microbiológico precoz de esta complicación permitió un manejo terapéutico conservador óptimo. Asimismo, el caso presentado nos recuerda que los pacientes post-COVID-19 pueden presentar complicaciones diferidas relacionadas con los tratamientos administrados en la fase aguda de la enfermedad, más allá de las secuelas pulmonares que empiezan a detectarse en los pacientes supervivientes.

Conflicto de intereses

Los autores declaran no tener ningún conflicto de intereses.

Bibliografía

1. Abate SM, Ahmed Ali S, Mantfardo B, Basu B. Rate of Intensive Care Unit admission and outcomes among patients with coronavirus: A systematic review and Meta-analysis. PLoS One. 2020;15:e0235653. <http://dx.doi.org/10.1371/journal.pone.0235653>.

2. Armstrong RA, Kane AD, Cook TM. Outcomes from intensive care in patients with COVID-19: a systematic review and meta-analysis of observational studies. *Anaesthesia*. 2020;75:1340–9.
3. Bassetti M, Giacobbe DR, Vena A, Wolff M. Diagnosis and Treatment of Candidemia in the Intensive Care Unit. *Semin Respir Crit Care Med*. 2019;40:524–39.
4. Epelbaum O, Chasan R. Candidemia in the Intensive Care Unit. *Clin Chest Med*. 2017;38:493–509.
5. Mastrangelo A, Germinario BN, Ferrante M, Frangi C, Li Voti R, Muccini C, et al. Candidemia in COVID-19 patients: incidence and characteristics in a prospective cohort compared to historical non-COVID-19 controls. *Clin Infect Dis*. 2020. <http://dx.doi.org/10.1093/cid/ciaa1594>, ciaa1594.
6. Antinori S, Bonazzetti C, Gubertini G, Capetti A, Pagani C, Morena V, et al. Tocilizumab for cytokine storm syndrome in COVID-19 pneumonia: an increased risk for candidemia? *Autoimmun Rev*. 2020;19:102564. <http://dx.doi.org/10.1016/j.autrev.2020.102564>.
7. Schoot TS, Kerckhoffs APM, Hilbrands LB, van Marum RJ. Immunosuppressive Drugs and COVID-19: A Review. *Front Pharmacol*. 2020;11:1333. <http://dx.doi.org/10.3389/fphar.2020.01333>.
8. Arastehfar A, Carvalho A, Nguyen MH, Hedayat MT, Netea MG, Perlin DS, et al. COVID-19-Associated Candidiasis (CAC): An Underestimated Complication in the Absence of Immunological Predispositions? *J Fungi (Basel)*. 2020;6:211. <http://dx.doi.org/10.3390/jof6040211>.
9. Bishburg E, Okoh A, Nagarakanti SR, Lindner M, Migliore C, Patel P. Fungemia in COVID -19 ICU Patients, a Single Medical Center Experience. *J Med Virol*. 2020. <http://dx.doi.org/10.1002/jmv.26633>.
10. Nowicki JL, Dean NR, Watson DI. A Case Report of Candida albicans Costochondritis after a Complicated Esophagectomy. *Plast Reconstr Surg Glob Open*. 2016;4:e608. <http://dx.doi.org/10.1097/GOX.0000000000000599>.
11. Crawford SJ, Swan CD, Boutlis CS, Reid AB. Candida costochondritis associated with recent intravenous drug use. *IDCases*. 2016;4:59–61.
12. Zapatero J, López Longo J, Monteagudo I, Carreño L. Costal chondritis in heroin addicts: a comparative study with postsurgical chondritis. *Br J Dis Chest*. 1988;82:341–6.
13. Yang SC, Shao PL, Hsueh PR, Lin KH, Huang LM. Successful treatment of Candida tropicalis arthritis, osteomyelitis and costochondritis with caspofungin and fluconazole in a recipient of bone marrow transplantation. *Acta Paediatr*. 2006;95:629–30.

Luis Gorospe-Sarasúa^{a,*}, José Ignacio Gallego-Rivera^a, Gemma María Muñoz-Molina^b, Rosa Mariela Mirambeaux-Villalona^c, Odile Ajuria-Illarramendi^d, Andrés González-García^e e Ignacio Barbolla-Díaz^e

^a Servicio de Radiodiagnóstico, Hospital Universitario Ramón y Cajal, Madrid, España

^b Servicio de Cirugía Torácica, Hospital Universitario Ramón y Cajal, Madrid, España

^c Servicio de Neumología, Hospital Universitario Ramón y Cajal, Madrid, España

^d Servicio de Medicina Nuclear, Hospital Universitario Ramón y Cajal, Madrid, España

^e Servicio de Medicina Interna, Hospital Universitario Ramón y Cajal, Madrid, España

* Autor para correspondencia.

Correo electrónico: luisgorospe@yahoo.com (L. Gorospe-Sarasúa).

<https://doi.org/10.1016/j.arbres.2020.12.002>

0300-2896/ © 2020 SEPAR. Publicado por Elsevier España, S.L.U. Todos los derechos reservados.

Acute Eosinophilic Pneumonia Associated With SARS-CoV-2 Infection



Neumonía eosinofílica aguda asociada con la infección por SARS-CoV-2

Dear Editor,

Acute eosinophilic pneumonia (AEP) is a rare condition characterized by an eosinophil infiltration of pulmonary parenchyma, which leads to an acute respiratory illness. It can be idiopathic or secondary to various agents, including infectious diseases.¹ We describe a case of AEP related to SARS-CoV-2 infection, expressed as a recurrence of respiratory symptoms after initial recovery from Covid-19 pneumonia.

A 61-year-old man without relevant medical history arrived at the emergency room with dyspnea, having started with fever and cough 2 weeks before. He did not smoke and denied other toxic use. A chest x-ray showed bilateral peripheral opacities and a nasal-oropharynx PCR for SARS-CoV-2 was positive. Mild elevation of ferritin, CRP and IL-6 was observed. The patient was admitted to the hospital with the diagnosis of Covid-19 pneumonia and treatment began with hydroxychloroquine, azithromycin and lopinavir/ritonavir (following the current hospital protocol at that moment), plus oxygen therapy at an initial FiO₂ of 28%. Patient's clinical and respiratory condition progressively improved and he was discharged after 5 days.

He came back to the hospital after one week because of recurrence of dyspnea and mild fever. New bilateral consolidations were observed in the chest X-ray, with no major changes in inflammatory parameters compared to previous admission. Slight elevation of neutrophils was observed, with normal eosinophil count (200 cells/ml). The PCR for SARS-CoV-2 at this time was negative. With the suspicion of infectious vs inflammatory complication, ceftriaxone and iv methylprednisolone 60 mg

per day were started, and the patient was readmitted to the hospital.

The CT scan showed bilateral subpleural ground glass opacities with areas of consolidation, with an air bronchogram sign and associated bronchiectasis (Fig. 1a). A bronchoscopy for bronchoalveolar lavage (BAL) and transbronchial biopsy was performed on the fifth day after admission. Bacterial cultures and bacilloscopy of BAL, bronchial aspirate and biopsy were negative. SARS-CoV-2 PCR was positive in bronchial aspirate but negative in BAL. The differential cell count in BAL fluid had 50% macrophages, 30% lymphocytes, and 20% polymorphonuclears (including 5% eosinophils). The biopsy showed a prominent mixed infiltrate in interstitium and alveoli with numerous eosinophils, compatible with partially treated AEP (Fig. 1b).

The patient completed one week of hospitalization, with both clinical and radiological improvement, and he was discharged continuing prednisone at a dose of 30 mg per day. During follow up in outpatient consultation the study was completed with HIV and *Strongyloides stercoralis* serology, as well as ANA and ANCA antibodies, which were all negative. A CT scan was repeated after one month, showing resolution of consolidation areas with persistence of minimum ground glass infiltrates. At this time, complete functional recovery was objectified with a forced vital capacity of 141% with no obstructive spirometric pattern, a carbon monoxide diffusion capacity of 84%, and absence of oxygen desaturation in the six minute walking test.

AEP presents as an acute respiratory illness, whose symptoms appear within days or weeks. Severity can go from mild disease to acute respiratory distress syndrome, with potential progression to death. It can be idiopathic or secondary to inhalational toxics, drugs or infections.¹

Diagnosis is challenging, especially during the current pandemic situation, since the clinical picture might resemble COVID-19 disease.² Diagnosis is based on clinical and laboratory criteria, with a leading role of cytological analysis of BAL fluid, where eosinop-