

disease. CT findings of this condition include multiple thin-walled, air-filled cystic structures (Fig. 1C). The line-and-dot pattern has been considered as a specific sign of PIPE.<sup>5,9</sup>

The therapeutic strategy to be followed in the case of PIPE is not clearly defined, especially in diffuse cases, and it will depend on the severity of respiratory symptoms and the stability of the patient.<sup>1-3</sup>

The conservative treatment of diffused cases includes mechanical ventilation in lateral decubitus position and selective bronchial intubation,<sup>1,10,11</sup> high frequency oscillation ventilation, liquid ventilation and extracorporeal membrane oxygenation.<sup>12-14</sup>

In refractory cases there is the possibility of LVRS. Localized lesions are more frequently diagnosed and surgically resected. There are only some exceptional cases described in the literature about diffuse PIPE treated by lobectomy or pneumonectomy with favorable evolution.<sup>1,3</sup> We consider that surgical treatment favoring the re-expansion of the adjacent pulmonary parenchyma must be taken into account in these patients despite all the existing conservative therapeutic measures, since they may fail in this disorder. However, more studies would be needed, in order to establish the precise indications and the most appropriate time for surgery in both, located and diffuse cases and the fully monitoring of the evolution after it.

The patient presented in this article had a respiratory situation at the age of 5 months of difficult management with conservative measures and a vital risk due to the great pulmonary and hemodynamic compromise. The radiological findings were compatible with PIPE, so that performing a lobectomy to reduce the emphysematous area was decided. The pathological findings of the resected piece confirmed the diagnosis.

Thirty months after surgery, the evolution has been satisfactory with home intermittent oxygen therapy.

## Bibliografía

- Matta R, Matta J, Hage P, Nassif Y, Mansour N, Diab N. Diffuse persistent interstitial pulmonary emphysema treated by lobectomy. *Ann Thorac Surg.* 2011;92:e73–5.
- de Laffolie J, Hirschburger M, Bauer J, Berthold LD, Faas D, Heckmann M. Lung volume reduction surgery in preterm infants with bronchopulmonary dysplasia. A case report. *Clin Case Rep.* 2013;1:96–9.
- Belcher E, Abbasi MA, Hansell DM, Ffolkes L, Nicholson AG, Goldstraw P. Persistent interstitial pulmonary emphysema requiring pneumonectomy. *J Thorac Cardiovasc Surg.* 2009;138:237–9.
- Oh MH, Kim MY, Shim WS, Oh SS, Shin BK, Cho SJ, et al. A case of localized persistent interstitial pulmonary emphysema. *J Korean Med Sci.* 2001;16:225–8.
- Jassal MS, Benson JE, Mogayzel PJ Jr. Spontaneous resolution of diffuse persistent pulmonary interstitial emphysema. *Pediatr Pulmonol.* 2008;43:615–9.

- Macklin MTMC. Malignant interstitial emphysema of the lungs and mediastinum as an important occult complication in many respiratory diseases and other conditions: an interpretation of clinical literature in the light of laboratory experiment. *Medicine.* 1944;23:281–358.
- Sacks GD, Chung K, Jamil K, Garg M, Dunn JC, DeUgarte DA. Surgical salvage of acquired lung lesions in extremely premature infants. *Pediatr Surg Int.* 2014;30:573–6.
- Siaplaouras J, Heckmann M, Reiss I, Schaible T, Waag KL, Gortner L. Lung volume reduction surgery in bronchopulmonary dysplasia. *Acta Paediatr.* 2003;92:754–6.
- Donnelly LF, Frush DP. Localized radiolucent chest lesions in neonates: causes and differentiation. *AJR Am J Roentgenol.* 1999;172:1651–8.
- Jakob A, Bender C, Henschen M, Saueressig U, Uhl M, Kruger M, et al. Selective unilateral lung ventilation in preterm infants with acquired bullous emphysema: a series of nine cases. *Pediatr Pulmonol.* 2013;48:14–9.
- Cohen RS, Smith DW, Stevenson DK, Moskowitz PS, Graham CB. Lateral decubitus position as therapy for persistent focal pulmonary interstitial emphysema in neonates: a preliminary report. *J Pediatr.* 1984;104:441–3.
- Squires KA, De Paoli AG, Williams C, Dargaville PA. High-frequency oscillatory ventilation with low oscillatory frequency in pulmonary interstitial emphysema. *Neonatology.* 2013;104:243–9.
- Toledo Del Castillo B, Gordillo I, Rubio García E, Fernandez Lafever SN, Gonzalez Cortes R, Urbano Villaescusa J, et al. Diffuse persistent pulmonary interstitial emphysema secondary to mechanical ventilation in bronchiolitis. *BMC Pulm Med.* 2016;16:139.
- Dani C, Reali MF, Bertini G, Martelli E, Rubaltelli FF. Liquid ventilation in an infant with persistent interstitial pulmonary emphysema. *J Perinat Med.* 2001;29:158–62.

Ana Isabel Garrido Ocaña<sup>a,\*</sup>,  
 Marta González Fernández-Palacios<sup>a</sup>,  
 José Antonio Matute de Cárdenas<sup>b</sup>,  
 María Luisa Rosso González<sup>a</sup>, Elena Merchante García<sup>c</sup>,  
 José Alberto García Bolaños<sup>d</sup>, María José Moreno Valera<sup>e</sup>

<sup>a</sup> Neonatal Intensive Care Unit, Virgen del Rocio University Hospital, Spain

<sup>b</sup> Pediatric Airway Surgical Unit, Virgen del Rocio University Hospital, Spain

<sup>c</sup> Department of Pediatric Radiology, Virgen del Rocio University Hospital, Spain

<sup>d</sup> Department of Pathology, Virgen del Rocio University Hospital, Spain

<sup>e</sup> Pediatric Pulmonology Unit, Virgen del Rocio University Hospital, Spain

\* Corresponding author.

E-mail address: [anabel.garrido@gmail.com](mailto:anabel.garrido@gmail.com) (A.I. Garrido Ocaña).

<https://doi.org/10.1016/j.arbres.2019.10.029>

0300-2896/ © 2020 SEPAR. Published by Elsevier España, S.L.U. All rights reserved.

## Measles-Associated Pneumonia



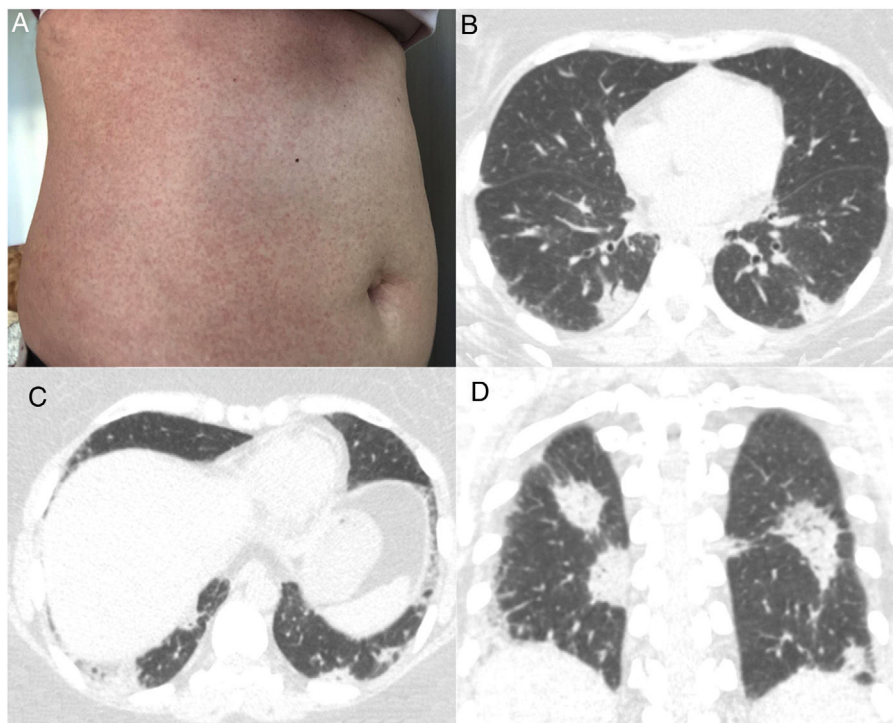
### Neumonía asociada al sarampión

Dear Editor:

A 43-year-old immunocompetent woman presented to the emergency department with a history of 5 days of high fever (39 °C), headache and diarrhea, evolving with a confluent maculopapular rash on her trunk (Fig. 1A). The patient was a resident of São Paulo, Brazil, in which an outbreak of measles was occurring. She had no history of measles vaccination. The diagnosis of measles was confirmed by serological positivity for serum measles immunoglobulin M (IgM) antibodies. No Koplik's spots were observed. One week after the onset of clinical symptoms, the

patient began to present respiratory symptoms, with dry cough, dyspnea, chest pain and sore throat. Laboratory tests showed leukopenia with lymphocytosis. Blood cultures were negative. Chest computed tomography (CT) demonstrated multiple peripheral consolidations, mainly in the lower lobes (Fig. 1B–D). Pulmonary embolism was excluded. Bronchoscopy was performed, and microscopic examination of the bronchoalveolar lavage fluid and cultures showed negativity for bacteria and fungi. The patient was managed solely with supportive therapy. Her condition and respiratory distress improved, and she was discharged 7 days after admission.

Measles is one of the world's most contagious viral diseases. Its re-emergence throughout Europe and North America has recently been reported.<sup>1-3</sup> The disease has a prodromal phase of fever, cough, coryza, and conjunctivitis, similar to any upper respira-



**Fig. 1.** (A) Photograph showing a confluent maculopapular rash on the trunk. (B and C) Axial and (D) coronal computed tomography images demonstrating multiple peripheral consolidations, mainly in both lungs.

tory tract infection. The characteristic measles rash appears a few days after the onset of fever. Koplik's spots, a pathognomonic sign, appear on the buccal mucosa as small white papules. Recovery typically occurs within 1 week of rash onset in people with uncomplicated measles.<sup>1,2,4–6</sup>

The clinical diagnosis of measles may be challenging in patients who present before the onset of rash or whose rashes are less apparent. Therefore, laboratory confirmation of the clinical suspicion of acute measles infection is highly recommended. The laboratory method used most commonly to confirm the diagnosis of measles is the detection of measles virus-specific IgM antibodies in serum or plasma. A real-time polymerase chain reaction assay for measles virus RNA in urine, blood, oral fluid or nasopharyngeal specimens can identify infection before measles IgM antibodies are detectable.<sup>2,5,6</sup>

Most measles-related deaths are caused by complications. The respiratory tract is a frequent site of complication, with pneumonia accounting for most measles-associated morbidity and mortality. Pneumonia can be caused by the measles virus, or by secondary viral or bacterial pathogens.<sup>3</sup> These conditions can be difficult to differentiate based on imaging features, as the imaging findings of measles pneumonia are nonspecific. The most common CT findings are ground-glass opacities and consolidations with lobular or segmental distribution, nodules, interlobular septal thickening and bronchial or bronchiolar wall thickening. Other CT findings are bronchiolitis, hyperinsufflation, mosaic attenuation, pleural effusion and lymphadenopathy.<sup>1,4</sup> Vaccinated individuals infected with measles can develop nodular pneumonia. These cases can be misdiagnosed due to the absence of specific IgM and typical symptoms.<sup>7</sup> Vaccination is the best way to prevent measles, but the live-attenuated virus vaccine is contraindicated in immunocompromised patients.<sup>2,6</sup> The management of patients with measles consists of supportive therapy to correct or prevent dehydration and, in some cases, to treat nutritional deficiencies, as well as early detection and treatment of secondary bacterial infections, such as pneumonia and otitis media. High doses of vitamin A have

been shown to decrease mortality and the risk of complications. No specific antiviral therapy for measles exists, although ribavirin, interferon alfa, and other antiviral drugs have been used to treat severe cases.<sup>2,6</sup>

### Bibliografía

- Melenotte C, Cassir N, Tessonier L, Brouqui P. Atypical measles syndrome in adults: still around. *BMJ Case Rep.* 2015;23:2015, <http://dx.doi.org/10.1136/bcr-2015-211054>.
- Strebel PM, Orenstein WA. Measles. *N Engl J Med.* 2019;381:349–57, <http://dx.doi.org/10.1056/NEJMcp1905181>.
- Yu D, Zhang G, Gao L, Xu W, Cao B. High ratio of measles-specific IgG/IgM associated with nodular pneumonia in vaccinated individuals. *Int J Infect Dis.* 2018;76:38–44, <http://dx.doi.org/10.1016/j.ijid.2018.08.015>.
- Albarelo F, Cristofaro M, BusiRizzi E, Giancola ML, Nicastrì E, Schininà V. Pulmonary measles disease: old and new imaging tools. *Radiol Med.* 2018;123:935–43, <http://dx.doi.org/10.1007/s11547-018-0919-y>.
- Suter C, Buergi U, Eigenmann K, Franzen D. Severe acute measles pneumonitis: virus isolation in bronchoalveolar lavage fluid. *BMJ Case Rep.* 2015;27:2015, <http://dx.doi.org/10.1136/bcr-2015-210826>.
- Moss WJ. Measles. *Lancet.* 2017;390(10111):2490–502, [http://dx.doi.org/10.1016/S0140-6736\(17\)31463-0](http://dx.doi.org/10.1016/S0140-6736(17)31463-0).
- Kakoullis L, Sampsonas F, Giannopoulou E, Kalogeropoulou C, Papachristodoulou E, Tsiamita M, et al. Measles-associated pneumonia and hepatitis during the measles outbreak of 2018. *Int J Clin Pract.* 2019:e13430, <http://dx.doi.org/10.1111/ijcp.13430>.

Pablo Rydz Pinheiro Santana<sup>a</sup>, Glenda Fanstone Planard<sup>a</sup>, Gláucia Zanetti<sup>b</sup>, Edson Marchiori<sup>b,\*</sup>

<sup>a</sup> *Medimagem, Hospital Beneficência Portuguesa de São Paulo, São Paulo, Brazil*

<sup>b</sup> *Universidade Federal do Rio de Janeiro, Rio de Janeiro, Brazil*

\* Corresponding author.

E-mail address: [edmarchiori@gmail.com](mailto:edmarchiori@gmail.com) (E. Marchiori).

<https://doi.org/10.1016/j.arbres.2020.01.003>

0300-2896/ © 2020 SEPAR. Published by Elsevier España, S.L.U. All rights reserved.