

2. Ojanguren I, Morell F, Ramón MA, Villar A, Romero C, Cruz MJ, et al. Long-term outcomes in chronic hypersensitivity pneumonitis. *Allergy*. 2019;74:944–52.
3. De Sadeleer LJ, Hermans F, De Dycker E, Yserbyt J, Verschakelen JA, Verbeken EK, et al. Effects of corticosteroid treatment and antigen avoidance in a large hypersensitivity pneumonitis cohort: a single-centre cohort study. *J Clin Med*. 2018;8:14.
4. Jordan S, Distler JHW, Maurer B, Huscher D, van Laar JM, Allanore Y, et al. Effects and safety of rituximab in systemic sclerosis: an analysis from the European Scleroderma Trial and Research (EUSTAR) group. *Ann Rheum Dis*. 2015;74:1188–94.
5. Mohammed AGA, Alshihre A, Al-Homood IA. Rituximab treatment in patients with systemic sclerosis and interstitial lung disease. *Ann Thorac Med*. 2017;12:294–7.
6. Lota HK, Keir GJ, Hansell DM, Nicholson AG, Maher TM, Wells AU, et al. Novel use of rituximab in hypersensitivity pneumonitis refractory to conventional treatment. *Thorax*. 2013;68:780–1.
7. Keir GJ, Maher TM, Ming D, Abdullah R, de Lauretis A, Wickremasinghe M, et al. Rituximab in severe, treatment-refractory interstitial lung disease. *Respirology*. 2014;19:353–9.
8. Schuyler M, Cormier Y. The diagnosis of hypersensitivity pneumonitis. *Chest*. 1997;111:534–6.
9. Vasakova M, Morell F, Walsh S, Leslie K, Raghu G. Hypersensitivity pneumonitis: perspectives in diagnosis and management. *Am J Respir Crit Care Med*. 2017;196:680–9.
10. du Bois RM, Albera C, Bradford WZ, Costabel U, Leff JA, Noble PW, et al. 6-Minute walk distance is an independent predictor of mortality in patients with idiopathic pulmonary fibrosis. *Eur Respir J*. 2014;43:1421–9.
11. Barrera L, Mendoza F, Zuñiga J, Estrada A, Zamora AC, Melendro EI, et al. Functional diversity of T-cell subpopulations in subacute and chronic hypersensitivity pneumonitis. *Am J Respir Crit Care Med*. 2008;177:44–55.

Ferran Morell<sup>a,b</sup>, Iñigo Ojanguren<sup>a,b,c,\*</sup>, Ana Villar<sup>a,b,c</sup>,  
María Antonia Ramon<sup>a,b</sup>, Xavier Muñoz<sup>a,b,c</sup>, María Jesús Cruz<sup>a,b</sup>

<sup>a</sup> Vall d'Hebron Institut de Recerca (VHIR), Barcelona, Spain

<sup>b</sup> CIBER de Enfermedades Respiratorias (CIBERES), Barcelona, Spain

<sup>c</sup> Servei de Pneumologia, Hospital Universitari Vall d'Hebron, Departament de Medicina, Universitat Autònoma de Barcelona (UAB), Barcelona, Spain

\* Corresponding author.

E-mail address: iojangur@vhebron.net (I. Ojanguren).

<https://doi.org/10.1016/j.arbres.2019.07.013>

0300-2896/ © 2019 SEPAR. Published by Elsevier España, S.L.U. All rights reserved.

## Allergic Bronchopulmonary Aspergillosis With Elevated CEA Is Infrequent



### La aspergilosis broncopulmonar alérgica con niveles elevados de antígeno carcinoembrionario (CEA) es infrecuente

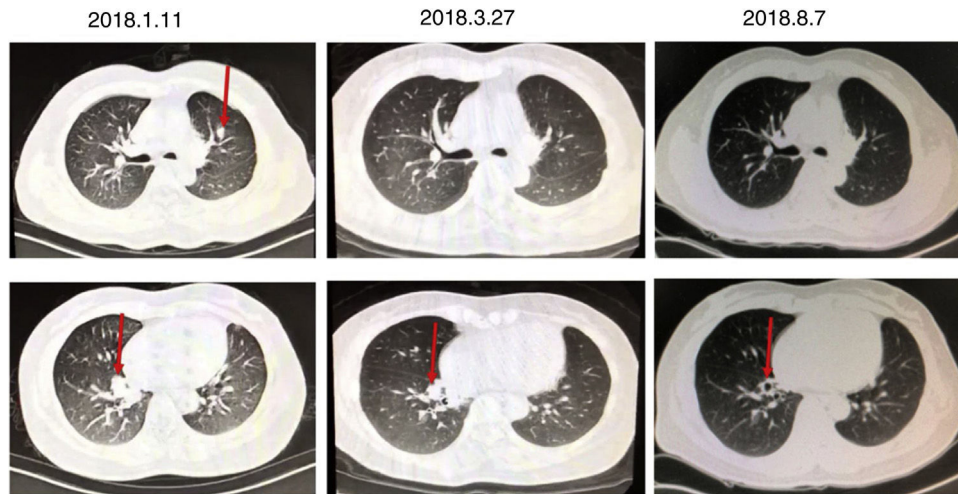
Dear Editor:

Allergic bronchopulmonary aspergillosis (ABPA) is a complex hypersensitivity reaction in response to colonization of the airways with *Aspergillus fumigatus*.<sup>1</sup> It occurs primarily in patients with asthma or cystic fibrosis (CF).<sup>2,3</sup> We report a case of this disease without asthma or CF, but with an elevated carcinoembryonic antigen (CEA) instead.

A 46-year-old woman, non-smoker, with no history of asthma or recurrent lung disease was admitted to the hospital for paroxysmal cough for two months. She denied expectoration, shortness of breath, chest pain, hemoptysis, fevers or chills. During the course of her illness, the patient lost 2.5 kg of weight with poor appetite. She has a surgical history of lingular segment of the left upper pulmonary lobe resection in 2015, and the histopathological report showed bronchiectasis, acute infections and abscesses. Laboratory data revealed a markedly elevated blood eosinophil count and percentage ( $1.2 \times 10^9/L$ , 15.1%) and total serum level of immunoglobulin E (1412 kU/L). Chest CT revealed shadow in the medial basal segment of the right lower lobe and the upper left lung, right lung bronchiectasis and infection on 11th January 2018 (Fig. 1). In considering of her surgical history and chest CT, we tested several tumor markers to rule out primary and metastatic tumors. The serum CEA (24.2 ng/mL) was remarkable elevated, while serum CA19-9 level was normal. A subsequent PET scan showed no focal increase in fluorodeoxyglucose activity. Bronchoscopy showed inflamed bronchial mucosa and cytological examination of bronchoalveolar lavage fluid showed no cancer cells nor heterotypic cells. Pulmonary function test results showed a vital capacity of 2.87 L (75.3% of predicted), FVC of 4.14 L (80% of predicted), FEV1 of 2.15 L (84.5% of predicted), FEV1/FVC ratio of 74.86%. According to the patient's pulmonary function at that time, when the cumulative dose of acetylcholine reached 2.5 mg (12.8 micromole), FEV1 decreased by 11.0% in the patient. Bronchial histamine provocation test and bronchodilator test were negative. She was limited response to levofloxacin treatment.

Subsequently, the results of *A. fumigatus*-specific IgE 8.26 kUA/L, *A. fumigatus*-specific IgG > 500 AU/mL. One month oral corticosteroid treatment was helpful for improving patient's symptom and radiological abnormality (Fig. 1). Total IgE concentration, which is a key indicator for assessing the treatment response and relapse, was rapidly declined after 3 months treatment associated with symptomatic improvement. The concentration of serum CEA decreased to normal range 6 months later. No relapse has been observed throughout the one-year follow-up (Table 1).

CEA, is known to be one of the most extensively used clinical marker for colorectal carcinoma and lung cancer.<sup>4</sup> It can be produced in the epithelium of the stomach, intestines, bile ducts, and respiratory tract ranging from the trachea to the alveoli and plays a role in the progress of cell adhesion and participate in the innate immune defense.<sup>5</sup> Noguchi et al. measured serum CEA levels in patients with ABPA and found serum CEA levels are elevated in some patients with ABPA, which might be associated with consolidation in the lung.<sup>6</sup> Elevated serum CEA levels decrease as the consolidation decreases after treatment. The elevation of serum CEA might be attributed to the presence of local inflammation in the lung. We found several cases reported asthmatic patients with high level of CEA in serum and bronchoalveolar lavage fluid might be related to the mucoid impaction.<sup>7,8</sup> In our case, we found the level of CEA was not directly related to the mucoid impaction in our follow-up. Tang et al. have discovered that the increase level of CEA was related to the increase number of eosinophil granulocytes, and corticosteroid therapy was effective in improving clinical symptoms and the CEA values decreased in association with the improvement of those manifestations, suggesting a pathophysiological link between the disease activity of hypereosinophilia and the changes in CEA level.<sup>9,10</sup> In our case, we found that the level of CEA decreased along with the decrease of eosinophil granulocytes. The underlying mechanism remains unclear. Besides, there is also a report showing that a 21-year-old man with bronchial asthma who suffered from productive cough had an elevated serum CA19-9 level.<sup>11</sup> In that case, immunohistochemical studies showed no expression of CA19-9 in bronchial biopsy specimens, but the CA19-9 level recovered to normal range after steroid therapy. This indicates that the high serum concentration of CA19-9 was probably due to hypersecretion of mucus glycoprotein, secreted from hypertrophic glands or/and epithelial cells in the bronchioles. These finding suggests that CEA is correlated with the inflammatory activity of ABPA while



**Figure 1.** The results of the patients with multiple CT examinations.

**Table 1**

The course of treatment and dose of prednisone, as well as the data of CEA, IgE, and peripheral blood eosinophils before and after the treatment.

Date	Peripheral blood eosinophils ( $\times 10^9/L$ )	Serum IgE (IU/mL)	CEA (ng/mL)	Prednisone dose
Reference value	0.2–0.52	<358.0	0–6.5	
2017.11.24	1.3			The patient declined
2017.12.02		1412.3		
2017.12.20	0.8	1455.3		
2018.07.13	0.9	1575.6	24.02	30 mg qd, minus 5 mg every two weeks
2018.08.08	0.6	1567.2	21.27	
2018.10.29	0.6	1135.9	4.28	Maintain 5 mg qd
2019.02.20				The patient's symptoms improved, but she stop using prednisone without doctor's advice
2019.04.02	0.7	1591.3	25.7	25 mg qd, minus 5 mg every two weeks
2019.04.25	0.4	1638.8	8.28	
2019.05.28	0.5	1106.4	6.3	Maintain 5 mg qd

the role of CEA elevation remains unclear. Larger numbers of cases should be collected and evaluated.

## Bibliografía

- Agarwal R. Allergic bronchopulmonary aspergillosis. *Chest*. 2009;135:805–26.
- Carsin A, Romain T, Ranque S, Reynaud-Gaubert M, Dubus JC, Mege JL, et al. *Aspergillus fumigatus* in cystic fibrosis: an update on immune interactions and molecular diagnostics in allergic bronchopulmonary aspergillosis. *Allergy*. 2017;72:1632–42.
- Greenberger PA. Allergic bronchopulmonary aspergillosis. *J Allergy Clin Immunol*. 2002;110:685–92.
- Grunnet M, Sorensen JB. Carcinoembryonic antigen (CEA) as tumor marker in lung cancer. *Lung Cancer (Amsterdam, Netherlands)*. 2012;76:138–43.
- Hammarstrom S. The carcinoembryonic antigen (CEA) family: structures, suggested functions and expression in normal and malignant tissues. *Sem Cancer Biol*. 1999;9:67–81.
- Noguchi T, Yamamoto K, Moriyama G, Saito Y, Kyoyama H, Mikami S, et al. Evaluation of serum levels of carcinoembryonic antigen in allergic bronchopulmonary aspergillosis. *J Nippon Med School = Nippon Ika Daigaku zasshi*. 2013;80:404–9.
- Matsuo K, Araki M, Watanabe Y, Hiraki S. A patient with bronchial asthma and mucoid impaction who presented with a high concentration of carcinoembryonic antigen in serum. *Nihon Kyobu Shikkan Gakkai zasshi*. 1997;35:883–7.
- Maeda Y, Hizawa N, Fukui Y, Nagai K, Kikuchi E, Takahashi D, et al. Concentrations of carcinoembryonic antigen in serum and bronchoalveolar lavage fluid of asthmatic patients with mucoid impaction. *Nihon Kogyaku Gakkai zasshi*. 2004;42:988–93.
- Tang TT, Cheng HH, Zhang H, Lin XL, Huang LJ, Zhang W, et al. Hypereosinophilic obliterative bronchiolitis with an elevated level of serum CEA: a case report and a review of the literature. *Eur Rev Med Pharmacol Sci*. 2015;19:2634–40.
- Iwata H, Tsuboi N, Ishii T, Hara Y, Okido I, Takahashi H, et al. Hypereosinophilia associated with increased serum levels of carcinoembryonic antigen. *Intern Med (Tokyo, Japan)*. 2008;47:963–7.
- Hachiya T, Koyama S, Kubo K, Sekiguchi M, Honda T. Elevated serum CA19-9 level and regional lymphadenopathy in a young man with allergic bronchopulmonary aspergillosis. *Intern Med (Tokyo, Japan)*. 1998;37:91–3.

Wei Tang, Shuanglinzi Deng, Lisha Luo, Bailing Luo, Chengping Hu, Ruichao Niu, Juntao Feng\*

Department of Respiratory Medicine, Key Cite of National Clinical Research Center for Respiratory Disease, Xiangya Hospital, Central South University, Changsha, Hunan, China

\* Corresponding author.

E-mail address: jtfeng1976@hotmail.com (J. Feng).

<https://doi.org/10.1016/j.arbres.2019.10.003>

0300-

2896/ © 2019 The Author(s). Published by Elsevier España, S.L.U. on behalf of SEPAR.