

Clinical Image

A Case Report on a Patient With Spontaneous Expulsion of Large Foreign Body (Dental Prosthesis) Without Complications

Un caso de expulsión espontánea de un cuerpo extraño grande (prótesis dental) sin complicaciones

João Pedro Neiva Machado*, José Coutinho Costa, Teresa Costa

Serviço de Pneumologia – Centro Hospitalar e Universitário de Coimbra, Coimbra, Portugal

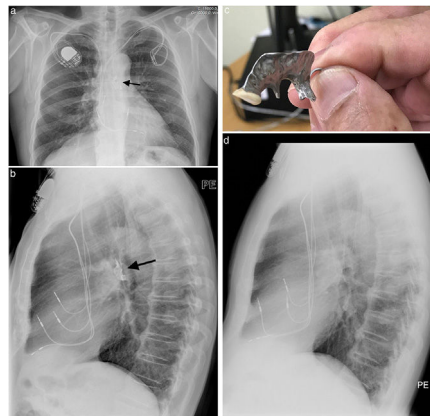


Fig. 1. (a) Postero-anterior view of chest X-ray showing the foreign body (prosthetic teeth – black arrow) in the trachea/left main bronchus. Also, a pacemaker and the pacemaker electrodes are seen. (b) Lateral view of chest X-ray showing the foreign body (prosthetic teeth – black arrow) in the trachea/left main bronchus. Also, a pacemaker and the pacemaker electrodes are seen. (c) Prosthetic teeth hold on hand for scale. (d) Lateral view of chest X-ray showing no foreign body (prosthetic) in the trachea/left main bronchus. Also, a pacemaker and the pacemaker electrodes are seen.

A 71-year-old man presents to the emergency department with a history of progressive worsening of cough and shortness of breath, with onset after an episode of vomiting due to alcohol intoxication, one month before. At the emergency department, multiple tests were ordered including complete blood count and blood chemistry, all within normal range (including C reactive protein) and a chest X-ray (Fig. 1a and b) that showed a foreign body (dental prosthesis) lodged in the trachea/left main bronchus. The foreign body was not observed, the patient got discharged with an association of budesonide (160ug) and formoterol (4.5 µg), twice a day, and sent to a pulmonology consultation for reassessment. One month later, during the pulmonology consultation, the patient describes an episode, 2 weeks before, of violent cough during his sleep, that ended up with him feeling a metal taste and finding the dental prosthesis (Fig. 1c) inside his mouth. Chest X-ray performed on the

day of the consultation confirmed the absence of the foreign body (Fig. 1d). Since then, the patient became asymptomatic and did not need any follow up. A foreign body, especially with sharp edges, is a dangerous and common medical emergency. Spontaneous expulsion of a foreign body of this nature is quite rare. The incidence of spontaneous expulsion is about 2–4%¹ and the endoscopic removal is the mainstay of treatment. Here we present a case that, despite the high risk of severe complications, successfully resolved without medical intervention.

Reference

1. Jaiswal AA, Garg AK. (2014) Spontaneous expulsion of foreign body (sewing machine needle) from right middle lobe bronchus – a rare case report. *J Clin Diagn Res.* 2014;8:KD01–2.

* Corresponding author.
E-mail address: joaoneivamachado@gmail.com (J.P. Neiva Machado).