

laterally and from the diaphragm to the aorta. Epicardiectomy was performed by subtotal decortication of the anterior and lateral faces of the heart. This is the crucial step of the surgery when sometimes the separation of the epicardium from the myocardium is almost impossible. In cases like this, a Waffle procedure can be performed to avoid the risk of accidents.<sup>10</sup> In these series, CP was related to worst outcome with death or palliation in three patients with a mortality rate of almost 20%. The effective treatment with an aggressive surgery as the pericardiectomy on the other hand was responsible for a good response with long survival rate.

This is the first case of CP after a single lung transplantation. Since there was no cardiopulmonary assistance and minimal pericardial manipulation, idiopathic or multifactorial causes should be involved. The most important is the prompt diagnosis to assure ideal surgical treatment to avoid fatal outcome.

## Bibliografía

- Stephens G, Bhagwat K, Marasco S, McGiffin D. Constrictive pericarditis post-lung transplant. *J Card Surg.* 2015;30:651–5.
- Afshar K, Cunningham MJ, Barbers RG, McFadden PM. Pericardial constriction after lung transplantation. *Ann Thorac Surg.* 2010;90:1361–3.
- Welch TD. Constrictive pericarditis: diagnosis, management and clinical outcomes. *Heart.* 2018;104:725–31.
- Karolak W, Cypel M, Chen F, Daniel L, Chaparro C, Keshavjee S. Constrictive pericarditis after lung transplantation: an under-recognized complication. *J Heart Lung Transplant.* 2010;29:578–81.
- Billings ME, Mulligan M, Raghu G, Team UoWLT. Acute constrictive pericarditis after lung transplantation for lymphangioleiomyomatosis. *J Heart Lung Transplant.* 2009;28:110–3.
- Sayah DM, Schwartz BS, Kukreja J, Singer JP, Golden JA, Leard LE. Scedosporium prolificans pericarditis and mycotic aortic aneurysm in a lung transplant recipient receiving voriconazole prophylaxis. *Transpl Infect Dis.* 2013;15:E70–4.
- Billings ME, Mulligan M, Raghu G. Acute constrictive pericarditis after lung transplantation for lymphangioleiomyomatosis. *J Heart Lung Transplant.* 2009;28:110–3.
- Samano MN, Iuamoto LR, Fonseca HV, L.M., L.G., F.B., et al. A simple technique can reduce cardiopulmonary bypass use during lung transplantation. *Clinics (Sao Paulo).* 2016;71:232–4.
- Mookadam F, Jiamsripong P, Raslan SF, Panse PM, Tajik AJ. Constrictive pericarditis and restrictive cardiomyopathy in the modern era. *Future Cardiol.* 2011;7:471–83.
- Matsuura K, Mogi K, Takahara Y. Off-pump waffle procedure using an ultrasonic scalpel for constrictive pericarditis. *Eur J Cardiothorac Surg.* 2015;47:e220–2.

Flavio Pola dos Reis<sup>a</sup>, Ellen Caroline Toledo Nascimento<sup>b</sup>, Paulo Manoel Pego-Fernandes<sup>a</sup>, Marcos Naoyuki Samano<sup>a,\*</sup>

<sup>a</sup> Lung Transplant Group, Instituto do Coração (InCor), Hospital das Clínicas HCFMUSP, Faculdade de Medicina, Universidade de São Paulo, São Paulo, SP, Brazil

<sup>b</sup> Departamento de Patologia, Hospital das Clínicas HCFMUSP, Faculdade de Medicina, Universidade de São Paulo, São Paulo, SP, Brazil

\* Corresponding author.

E-mail address: marcos.samano@incor.usp.br (M.N. Samano).

<https://doi.org/10.1016/j.arbres.2019.02.011>

0300-2896/

© 2019 SEPAR. Published by Elsevier España, S.L.U. All rights reserved.

## Thoracic CT Scan vs PET-TC Imaging in the Diagnosis of Patients Suffering Exudative Pleural Effusions with Suspicion of Malignancy



### TC de tórax vs. PET/TC en el diagnóstico de pacientes que sufren derrame pleural exudativo con sospecha de neoplasia maligna

Dear Editor,

In the evaluation of a patient with pleural effusion (PE), clinical, radiological and pleural fluid data leads to the suspicion of malignancy.<sup>1–4</sup> Following cytological analysis of the pleural fluid, chest computed tomography (CT) and other tests according to clinical criteria, a videothoracoscopy is indicated. This is the most efficient diagnostic method in malignant PE.<sup>5</sup>

Recent meta-analysis precludes routine recommendation of a positron emission Tomography (PET)-CT for discriminating malign from benign PE. PET-CT has proved useful in the study and staging of multiple neoplasms yet its role in patients with PE suspicious of malignancy has not been analysed.<sup>6</sup>

This is a prospective study to analyse the PET-CT in relation to thoracic CT of a consecutive series of patients with unclassified PE from October 2013 to June 2016. We included patients with unclassified effusions after clinical history, biochemical, microbiological and cytological analysis, without pleuropulmonary lesions in the chest-X-ray other than the PE, but in whom clinical suspicion of malignancy (defined by constitutional syndrome, high intensity asbestos-exposure, PE greater than 1/3 of the hemithorax or increasing at follow-up and bloody pleural fluid) was established and for whom thoracoscopy and pleural biopsy were indicated. Previously all patients underwent a thoracic CT and a PET-CT. All patients without diagnosis of malignancy (when malig-

nant cells were detected in biopsy specimens.) were followed up until definite diagnosis was established or by means of clinical examination and imaging at 1, 3, 6 and every 6 months. The institutional ethics committee (CEIC PR(AG)149/2012) approved the study protocol, and the participants signed written informed consent.

Interpretation of chest CT imaging was done by a thoracic radiologist while interpretation of PET-CT imaging was carried out by a Nuclear Medicine Radiologist. They were blinded to the final diagnosis and both evaluated and registered a series of radiological findings and established a qualitative diagnosis of malignancy, benign or inconclusive.

The chi-square test (Fisher's exact test, when necessary) was employed to compare the clinical and radiological characteristics and the findings of the videothoracoscopy. To evaluate the association between the radiological findings from CT and PET-CT images and confirmed malignancy, a logistic regression was performed. Logistic regression was used to identify the best combination of CT and PET-CT findings to establish a better prediction of malignancy.

We included 42 patients with PE under study, 30 men and 12 women with a median age of 68 years old, for whom a diagnosis of malignancy had been established in 18, including 8 mesotheliomas (7 epithelioids and 1 sarcomatoid) and 10 metastatic (1 non-Hodgkin lymphoma, 1 adenocarcinoma of unknown origin and 8 NSCLC). Regarding the 24 benign effusions, 1 tuberculosis, 2 haemothorax and 1 LES were diagnosed.

Regarding CT scan data, the univariate analysis is shown in Table 1. Logistic regression permits to establish a diagnosis in 85.4% of patients due to the combination of nodular pleural thickening below or above 5 mm, the involvement of the mediastinal pleural node and adenopathy in the cardiophrenic angle, permitting correct diagnosis of 15 of the 18 malignant and 21 of the 24 benign

**Table 1**  
CT scan data and PET-TC data according to the definitive diagnosis of the patients.

	Benign (24)	Malign	P
CT Lineal pleural thickening <5 mm	19	18	ns
PET-CT lineal thickening <5 mm and SUV >5.64	1	12	<0.001
CT Lineal pleural thickening >5 mm	9	12	ns
PET-CT lineal thickening >5 mm and SUV >5.64	1	8	0.001
CT Nodular pleural thickening <5 mm	10	16	0.001
PET-CT nodular pleural thickening <5 mm and SUV >5.64	1	11	<0.001
CT Pleural nodule >10 mm:	4	13	<0.001
PET-CT nodule >10 mm and SUV >5.64	1	12	<0.001
CT Pleural mass >30 mm:	1	3	ns
PET-CT pleural mass >30 mm and SUV >5.64	0	5	0.007
CT circumferential pleural thickening:	2	4	ns
PET-CT circumferential thickening and SUV >5.64	1	5	0.03
CT nodular mediastinal pleura:	4	16	<0.001
PET-CT nodular mediastinal pleura and SUV >5.64:	1	12	<0.001
CT nodular fissural pleura:	8	14	0.01
PET-CT nodular fissural pleura and SUV >5.64:	0	4	0.008
CT mediastinal lymph nodes >8 mm	15	8	ns
PET-CT mediastinal lymph nodes (8 mm) or SUV >6.34	0	13	<0.001
CT mammary lymph nodes >8 mm	8	11	ns
PET-CT mammary lymph nodes (8 mm) or SUV >6.34	0	7	0.001
CT cardiophrenic lymph nodes >8 mm	3	10	0.003
PET-CT cardiophrenic lymph nodes (8 mm) or and SUV >6.34	0	7	0.001
CT UH pleural fluid	8.6	10.1	ns
PET-TC SUV pleural fluid	1.5 ± 1	1.5 ± 0.9	ns
CT extrapleural malignancy	0	12	<0.001
PET-CT extrapleural malignancy	0	9	<0.001
CT scan qualitative			
Negative	10	1	
Positive	3	15	<0.01
Indeterminate	11	2	
PET-CT qualitative			
Negative	22	2	
Positive	1	15	<0.001
Inconclusive	1	1	

effusions, with a sensitivity of 83%, specificity of 88%, VPP of 83% and VPN of 88% in the diagnosis of malignancy.

Regarding PET-TC data, the univariate analysis is shown in Table 1. Logistic regression permits to establish a diagnosis in 95.2% of the patients due to the combination of any pleural thickening with SUV level greater than 5.64 and the presence of mammary adenopathy with SUV level above 6.34, which allows a diagnosis to be established for 16 of the 18 malign and the 24 benign effusions with a sensitivity of 89%, specificity of 100%, VPP of 100% and VPN of 92% for diagnosis of malignancy.

In 3 patients with initial anatomopathological study negative a neoplasm was observed in the follow-up. One of the patients with suspicion of malignancy using chest CT and PET-CT repeated pleural biopsy provided a diagnosis of mesothelioma, and has therefore been included in the malignant group for sample analysis. Another patient with chest CT and PET-CT not suggestive of malignancy and with a negative thoracoscopy on two occasions, died of pneumonia during follow-up. The autopsy showed pleural sarcomatoid mesothelioma 2.1 × 2 cm stage T1aN0M0 and included in the malignant group. At two year follow-up another patient presented contralateral lung neoplasm with PE which was not related to the undiagnosed effusion.

Following analysis of the pleural fluid, thoracic CT is often the first diagnostic test performed.<sup>7,8</sup> However, although a chest CT does not inform malignancy, as 35% of patients will have neoplastic PE.<sup>8</sup> Recent meta-analysis also showed moderate accuracy of PET-TC for discriminating malign from benign PE.<sup>6</sup>

Classically, CT findings described as being suggestive of malignancy were nodular thickening or thickening greater than 1 cm, thickening of the mediastinal pleura and circumferential thickening.<sup>9,10</sup> In our patients both nodular pleural thickening and fissural or mediastinal nodular involvement show significant differences, as to do the cardiophrenic lymph nodes and

evidence of extrapleural malignancy and has permitted correct classification of 85.4% of patients with correct diagnosis established for 21 of the 24 benign and 15 of the 18 malignant effusions.

The PET-CT study, allows the identification, location and quantification through the SUV.<sup>6</sup> Multiple regression analysis permits correct diagnosis to be established in 95.2% of the patients due to the combination of any pleural thickening with SUV level greater than 5.64 and the existence of mammary adenopathy with SUV above 6.34, which means correct diagnosis of all the benign effusions and 16 of the 18 malign effusions.

Thus, although recent meta-analysis concluded that there is no data which justify its performance, PET-CT was not analysed in the group of patients with suspicion of malignancy.<sup>6</sup>

While we are aware that a small number of patients were analysed in this study and that therefore, further prospective studies evaluating the role of the PET-CT are needed, we believe our results suggest the PET-CT may play an important role in the study of undiagnosed patients.

## Bibliografía

- Ferrer J, Roldan J, Teixidor J, Pallisa E, Gich I, Morell F. Predictors of pleural malignancy in patients with PE undergoing thoracoscopy. *Chest*. 2005;127:1017–22.
- Porcel JM, Vives M. Etiology and pleural fluid characteristics of large massive effusions. *Chest*. 2003;124:978–83.
- Villena V, Lopez-Encuentra A, Garcia-Lujan R, Echave-Sustaeta J, Martinez CJ. Clinical implications of appearance of pleural fluid at thoracentesis. *Chest*. 2004;125:156–9.
- Alemán C, Sanchez L, Alegre J, Ruiz E, Vazquez A, Soriano T, et al. Differentiating between malignant and idiopathic pleural effusions: the value of diagnostic procedures. *QMJ*. 2007;100:351–9.
- Metintas M, Yildirim H, Kaya T, Ak G, Dundar E, Ozkan R, et al. Medical thoracoscopy vs CT scan-guided Abrams pleural needle biopsy for diagnosis of patients with pleural effusions: a randomized, controlled trial. *Respiration*. 2016;91:156–63.

6. Porcel JM, Hernández P, Martínez-Alonso M, Bielsa S, Salud A. Accuracy of fluorodeoxyglucose-PET imaging for differentiating benign from malignant pleural effusions. A meta-analysis. *Chest*. 2015;147:502–12.
7. Porcel JM, Pardina M, Bielsa S, González A, Light RW. Derivation and validation of a CT scan scoring system for discriminating malignant from benign pleural effusions. *Chest*. 2015;147:513–9.
8. Hallifax RJ, Haris M, Corcoran JP, et al. Role of CT in assessing pleural malignancy prior to thoracoscopy. *Thorax*. 2015;70:192–3.
9. Leung AN, Muller NL, Miller RR. CT in differential diagnosis of diffuse pleural disease. *Am J Roentgenol*. 1990;154:487–92.
10. Arenas J, Alonso S, Sánchez J, Fernández F, Gil S, Lloret M. Evaluation of CT findings for diagnosis of pleural effusions. *Eur Radiol*. 2000;10:681–90.

Marc Simó<sup>a</sup>, Esther Pallisa<sup>b</sup>, Alberto Jaúregui<sup>c</sup>,  
Bruno Montoro<sup>d</sup>, Ana Vázquez<sup>e</sup>, Irene Bello<sup>c</sup>,  
Oscar Persiva<sup>b</sup>, Carmen Alemán<sup>e,\*</sup>

<sup>a</sup> Department of Nuclear Medicine, Hospital Universitari Vall d'Hebron, Barcelona, Spain

<sup>b</sup> Department of Radiology, Hospital Universitari Vall d'Hebron, Barcelona, Spain

<sup>c</sup> Department of Thoracic Surgery, Hospital Universitari Vall d'Hebron, Barcelona, Spain

<sup>d</sup> Department of Pharmacy, Hospital Universitari Vall d'Hebron, Barcelona, Spain

<sup>e</sup> Department of Internal Medicine, Hospital Universitari Vall d'Hebron, Barcelona, Spain

\* Corresponding author.

E-mail address: [caleman@vhebron.net](mailto:caleman@vhebron.net) (C. Alemán).

<https://doi.org/10.1016/j.arbres.2019.02.012>

0300-2896/

© 2019 SEPAR. Published by Elsevier España, S.L.U. All rights reserved.

## Retrieval of a Very Large Foreign Body From the Bronchial Tree in an Intubated Patient



### Recuperación de un cuerpo extraño de gran tamaño del árbol bronquial de un paciente intubado

Dear Editor:

Foreign body (FB) aspiration is a common problem in children and adults, necessitating prompt recognition and early treatment to minimize the potentially serious and sometimes fatal consequences.<sup>1,2</sup> Consequences of an aspirated FB include the possibility of complete or partial airway obstruction, post-obstructive pneumonia, respiratory distress, pneumothorax or hemorrhage. Risk factors for FB aspiration include intellectual disability, neuromuscular diseases, maxillofacial trauma, unconsciousness, intoxication, dementia, and use of sedative drugs and dental medications.<sup>3</sup>

At present, FB removal in adults relies mainly on bronchoscopic techniques, including rigid and flexible bronchoscopy. A rigid bronchoscope provides greater access to the subglottic airways, ensuring correct oxygenation and easy passage of the telescope and grasping forceps during the extraction of a large FB. Furthermore, a rigid bronchoscope allows efficient airway suctioning if a massive bleed occurs.<sup>2,4</sup> Flexible bronchoscopy offers several advantages compared with rigid bronchoscopy: first, it is more cost effective and easily applicable in an outpatient setting. Second, it avoids the need for anesthesia and deep sedation. Finally, it has been shown to be associated with lower mortality compared with rigid bronchoscopy (1% vs 12%), a difference which may be attributable to the avoidance of general anesthesia.<sup>5,6</sup>

It is difficult to extract large FBs from the airway using a flexible bronchoscope, especially FBs such as dental prostheses. The irregular surface and hard composition of dental prostheses make them particularly difficult to grasp and extract using normally effective instruments (e.g. biopsy forceps, Fogarty balloon catheters, alligator forceps, or wire baskets). For this reason, practitioners commonly use a multidisciplinary approach or a combination of instruments. In this case report, we describe the successful removal of a very large dental prosthesis that nearly totally occluded the right main bronchus of a 72-year-old woman following a myocardial infarction.

A 72-year-old female patient was admitted to the hospital due to an anterior wall ST elevation myocardial infarction. She underwent a primary percutaneous coronary intervention with the insertion

of a stent to her left anterior descending coronary artery. She was intubated due to severe pulmonary edema and then safely weaned from mechanical ventilation seven days later. Ten hours after extubation, the patient suddenly developed dyspnea, tachypnea and severe hypoxemia. On physical examination, there were no signs of pulmonary edema, though decreased breathing sounds were noted on her right hemithorax. She underwent an immediate re-intubation, and an emergent chest X-ray revealed a large, fixed 7-unit restoration dental prosthesis nearly totally occluding the right main bronchus (Fig. 1).

Since the prosthesis was much wider than the 7.5-mm diameter of the endotracheal tube, we needed an innovative strategy for its extraction to avoid tracheotomy. A flexible bronchoscope was inserted through the endotracheal tube, after which the prosthesis could be seen in the right main bronchus. After a few attempts, the slippery prosthesis was finally grasped by large alligator forceps and the process of slowly withdrawing the scope began. When the prosthesis reached the distal end of the endotracheal tube, the

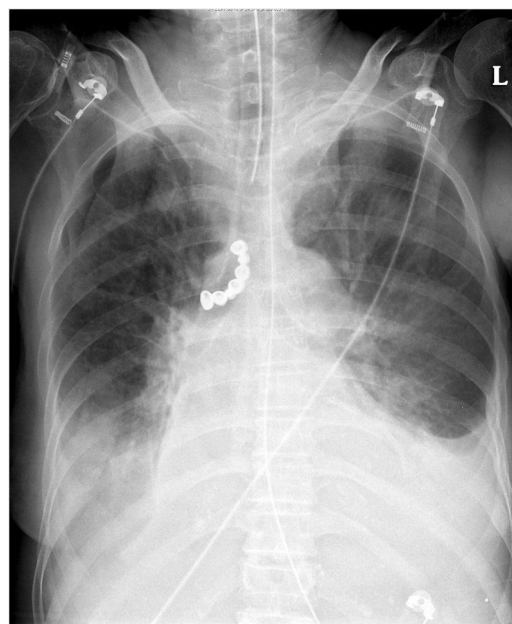


Fig. 1. Anterior–posterior chest X-ray demonstrating the radiopaque 7-unit dental prosthesis (arrow) in the patient's right main bronchus.