

Clinical Image

Yellow Nail Syndrome: A Rare Cause of Pleural Effusion

Síndrome de las uñas amarillas: una causa rara de derrame pleural

Federica De Giacomi^{a,b}, Narat Srivali^{a,b,*}

^a Respiratory Unit, Cardio-Thoracic-Vascular Department (FG), University of Milan-Bicocca, San Gerardo Hospital, Monza, Italy

^b Division of Pulmonary (NS), St. Agnes Hospital, Baltimore, MD, USA

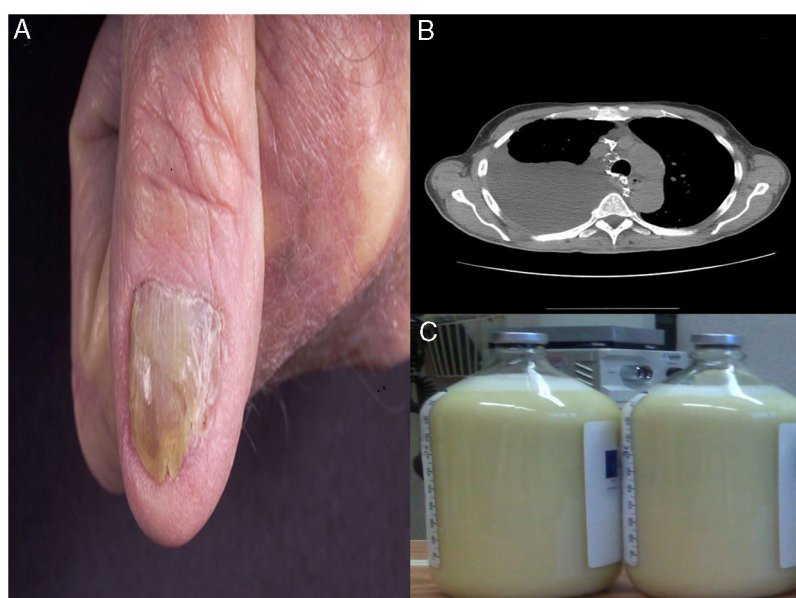


Fig. 1. (A) Yellow dystrophic fingernails. (B) Computed Tomography of the chest demonstrated large right-sided pleural effusion. (C) Milky white “Chylous” pleural fluid.

81-year-old-man presented to our institution with progressive exertional dyspnea over the preceding four months in conjunction with weight loss. Physical examination was remarkable for decrease right sided breath sounds and abnormal fingernails (Fig. 1A). Chest X-ray and Computed Tomography (Fig. 1B) demonstrated large right-sided pleural effusion. Thoracentesis drained 2 l of turbid, milky white appearance pleural fluid (Fig. 1C). The pleural fluid profile was compatible with Chylothorax with triglyceride level at 143 mg/dl. Cytology was no evidence of malignancy. Yellow nail syndrome (YNS) was diagnosed. YNS is a rare disorder characterized by a classical triad of the deformed yellow nail,

primary lymphedema, and recurrent pleural effusion.¹ The three criteria are not usually present at the same time, so the existence of two is satisfactory to establish the diagnosis.² Pleural effusion is persistent and has not been reported to spontaneous resolve.¹ Our patient had recurrent pleural effusion and required multiple thoracenteses. Subsequently, he underwent open thoracotomy with mechanical decortication and pleurodesis.

References

1. Banerjee A, Kanti-Biswas A, Bala S, Ghosh A. Yellow nail syndrome: a rare entity. *Indian Dermatol Online J.* 2014;5:529–31.
2. Nordkild P, Kromann-Andersen H, Struve-Christensen E. Yellow nail syndrome – the triad of yellow nails, lymphedema, and pleural effusions. A review of the literature and a case report. *Acta Med Scand.* 1986;219:221–7.

* Corresponding author.

E-mail address: nsrivali@gmail.com (N. Srivali).