



Clinical Image

Prostatic Brachytherapy Seed Embolization to the Lung

Embolización Pulmonar De Una Semilla De Braquiterapia Prostática

Luis Gorospe Sarasúa*, Nicolás Alejandro Almeida-Aróstegui, Isabel García-Gómez-Muriel

Servicio de Radiodiagnóstico, Hospital Universitario Ramón y Cajal, Madrid, Spain

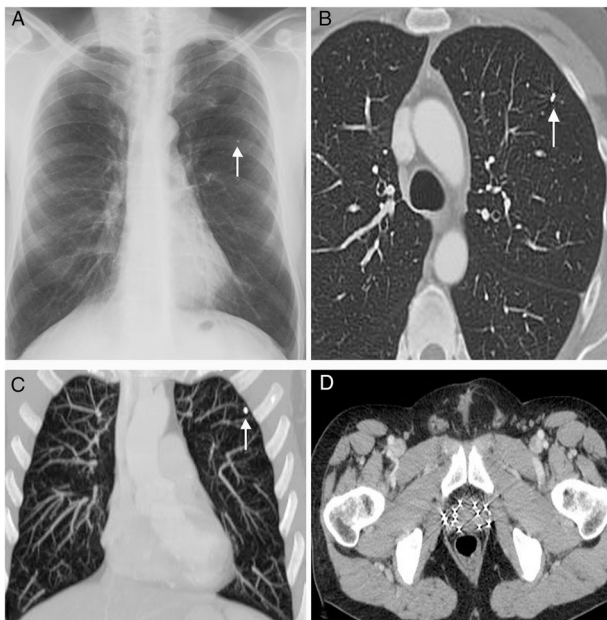


Fig. 1. (A) Posteroanterior chest radiograph shows a small metallic density in the left lung (arrow). (B) and (C) Axial (B) and coronal MIP (maximum intensity projection), (C) CT images (lung window) confirm that the metallic density corresponds to a single migrated brachytherapy seed in the left upper lobe (arrow). (D) Axial CT image at the level of the pelvis shows multiple brachytherapy seeds within the prostate.

We describe the imaging findings of a 64-year-old patient with a past medical history of a moderately differentiated early stage

prostate cancer that was successfully treated 3 years earlier with brachytherapy seeds. The patient, who was a former smoker, complained of cough and dyspnea. A chest radiograph did not show nodules or signs of pneumonia, but incidentally revealed a small intrapulmonary metallic density in the left lung (Fig. 1A). Thoracic computed tomography (CT) confirmed a single migrated brachytherapy seed within a small subsegmental pulmonary artery of the left upper lobe (Fig. 1B and C). Abdominal CT ruled out other migrated brachytherapy seeds (Fig. 1D). The patient's respiratory picture rapidly improved and the decision was to follow up the patient by his primary care provider.

Seed migration (SM) is a well-recognized event that occurs after transperineal interstitial prostate brachytherapy, and it is observed more often with loose seeds than with stranded seeds.¹ The most frequent site of SM is the lung. The incidence of SM to the chest is very variable (up to 0.98% per number of implanted seeds) depending on the types of the seeds (loose or stranded), designs of seeds placement (intra or extraprostatic), and diagnostic imaging protocols (different follow-up timings and chest radiographs projections).² Fortunately, the vast majority of reported cases of brachytherapy SM shows absence of adverse effects to the thorax, with only isolated cases of radiation-induced pneumonitis, lung cancer, or myocardial infarction.

References

1. Calvert AD, Dyer AW, Montgomery VA. Embolization of prostatic brachytherapy seeds to pulmonary arteries: a case study. *Radiol Case Rep.* 2016;12:34–8.
2. Sugawara A, Nakashima J, Kunieda E, Nagata H, Mizuno R, Seki S, et al. Incidence of seed migration to the chest, abdomen, and pelvis after transperineal interstitial prostate brachytherapy with loose (125I) seeds. *Radiat Oncol.* 2011;6: 130.

* Corresponding author.

E-mail address: luisgorospe@yahoo.com (L.G. Sarasúa).