

Jose Carlos Benítez<sup>a</sup>, Romà Bastús<sup>a</sup>, Luis Luizaga<sup>b</sup>, Luis Cirera<sup>a</sup>, Marc Campayo<sup>a,\*</sup>

\* Corresponding author.

E-mail address: [mcampayo@mutuaterrassa.es](mailto:mcampayo@mutuaterrassa.es) (M. Campayo).

<sup>a</sup> Department of Medical Oncology, Hospital Universitari Mutua Terrassa, Terrassa, University of Barcelona, Barcelona, Spain

<sup>b</sup> Department of Pathology, Hospital Universitari Mutua Terrassa, Terrassa, University of Barcelona, Barcelona, Spain

<https://doi.org/10.1016/j.arbres.2018.01.019>  
0300-2896/

© 2018 SEPAR. Published by Elsevier España, S.L.U. All rights reserved.

## Safety of a Modified Protocol of Bronchial Thermoplasty



### Seguridad de un protocolo modificado de termoplastia bronquial

Dear Editor:

Bronchial thermoplasty (BT) is a new endoscopic treatment for severe and uncontrolled asthma patients despite adequate medical treatment.<sup>1</sup> BT applies radiofrequency (RF)-produced heat to the bronchial wall. Clinical trials have observed improvement in quality of life and fewer exacerbation rates.<sup>2</sup> The proposed mechanism for improvement in asthma control is the reduction in the amount of airway smooth muscle (ASM) and consequent reduction in the airway hyperresponsiveness. Reduction of ASM induced by BT has been observed in animal models<sup>3</sup> and small case series.<sup>4–6</sup>

BT treatment requires three different bronchoscopy sessions (right lower lobe (RLL), left lower lobe (LLL) and upper lobes (UL), respectively) separated each other by a minimum of 3 weeks. The catheter is introduced into the working channel of the bronchoscope and placed in visible airways from distal to proximal guided by 5 mm distance marks. The technique description advises not to lose visual contact with the distal extreme of the catheter, where the electrodes are placed (Fig. 1(a)).<sup>7</sup> The amount of bronchial mucosa treated is limited to accessible airways where the tip of the catheter can be observed from bronchoscopic vision.

Considering BT as a locally applied treatment, there is controversy whether the number of activations and the extension of the treated area might have an influence in clinical response. Some authors suggest that the thermoplasty effect might be also related to regional changes induced by neurogenic mechanisms while others found that higher number of activations were related to better response to BT, measured by the Asthma Control Questionnaire Score (ACQ-5).<sup>8</sup>

This article describes a little modification in the published protocol, allowing further introduction of the catheter into smaller airways, losing visual contact with the distal extreme of the catheter but not with the last black mark, placed at 2 cm of the electrode wire (Fig. 1(b)). We hypothesized that this modification might increase the treated bronchial area (at least 2 cm each bronchus) and thus might have a potential benefit in the clinical response without increase in side effects.

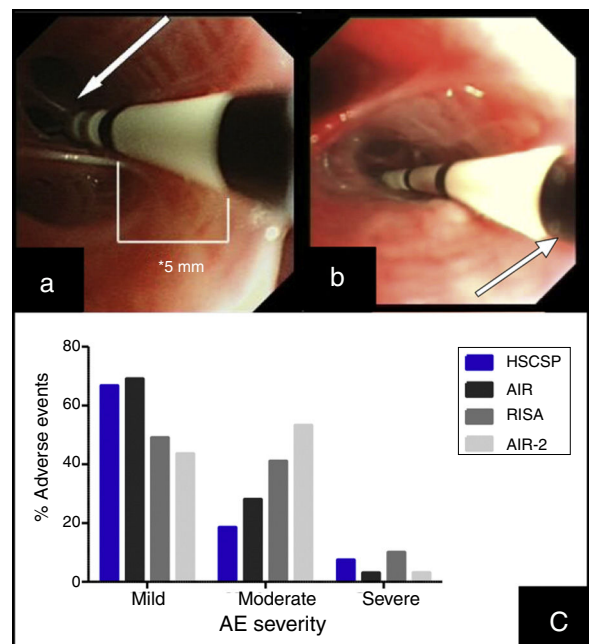
Approval for this study was obtained by the Clinical Research Ethics Committee of our center (approval number: EC/12/103/1388) and patients included signed informed consent. We included all severe and uncontrolled asthma patients<sup>1</sup> accepted for BT by an expert asthma team in our center since September 2012. Other inclusion criteria were: >18 years old, uncontrolled disease (maintained *Asthma Control Test* [ACT] score <19; ≥2 exacerbations in the previous year) and impaired quality of life (maintained shorter version of the *Asthma Quality of Life* [AQLQ] score <6.5). Subjects were excluded if: contraindication for bronchoscopy, allergy to sedative drugs, implantable devices, current smokers, past smoking habit of >15 pack-years, other respiratory diseases such as

emphysema or bronchiectasis, concomitant non-respiratory diseases, such as severe cardiopathies, that could contribute to impaired control of asthma.

BT was performed with the modified procedure in three different sessions. Patients were deeply sedated with remifentanyl and propofol, and intubated (Bronchoflex 7.5 mm, RÜsch, Teleflex Medical, Durham, NC, USA) to achieve a better control of cough.

We collected the length of the procedure, number of activations, adverse events (AE) during each BT session and in the first 24 h after. AE were classified as described previously<sup>10</sup> into: mild (transient symptoms well tolerated not interfering with normal activities, and that did not require treatment except by short-acting bronchodilators; bleeding during bronchoscopy that did not require any specific measure for its resolution); moderate (symptoms that caused interference with patient's usual activities; symptomatic treatment is possible; bleeding during bronchoscopy that requires aspiration during >3 s); and severe (signs or symptoms causing inability to do work or usual activities, requiring medical intervention and/or treatment; bleeding during bronchoscopy that leads to stop the procedure).

We included 9 patients (8 women, 1 male; mean age 50 ± 17.11 years; post-bronchodilator FEV<sub>1</sub> 82 ± 15%). All patients were in step



**Fig. 1.** (a) Insertion of the catheter up to distal airway without losing visual contact with the electrodes (arrow) according to established protocol. (b) Introduction of the catheter with loss of visual contact with the electrodes wire, but not with the last black mark (arrow), located at 2 cm from the electrodes wire. (c) Occurrence of adverse events in different series: our Hospital de la Santa Creu I Sant Pau are the sum of AE observed during the procedure and the 24 h after (percentages are calculated from the 27 modified procedures); AIR: Asthma Intervention Research<sup>9</sup>; RISA: Research in Severe Asthma<sup>10</sup>; AIR-2.<sup>11</sup>

5 of treatment.<sup>1</sup> In order to prevent the AE related to BT, all patients received 50 mg/day prednisone (or equivalent) the 3 days before and the day after the procedure. BT treatment was completed in all patients (27 procedures).

The mean number of activations per procedure was  $76.52 \pm 31.26$  ( $71.66 \pm 19.79$  in RLL,  $64.55 \pm 14.99$  in LLL and  $93.37 \pm 47.45$  in UL) with a mean length of  $65.81 \pm 19.32$  min ( $64.3 \pm 18.58$  in RLL,  $59.2 \pm 14.14$  in LLL and  $73.88 \pm 23.28$  in UL).

During the procedure, 7 patients suffered mild AE (6 bleeding and 1 bronchospasm). In the 24 h post-procedure we observed AE in 18 procedures. Most of them were mild (11/27) and moderate (5/27), consisting in cough and unspecific chest discomfort. Two patients had severe AE: one case of severe bronchospasm and acute respiratory insufficiency, and one case of collapse of the treated lobe with intense hypoxemia due to mucous plug. We did not find significant differences regarding adverse events when comparing our sample with those reported previously in clinical trials (Fig. 1(c)).<sup>10,11</sup> No deaths were occurred, and all severe AE resolved.

This little change in the procedure of BT allowed us to treat an extended bronchial area, as it is shown by the mean number of applications in our patients, which is higher than the average number of applications reported previously.<sup>12</sup> The extended treated bronchial area did not increase adverse effects. Further research is needed to know long-term safety and whether this technical modification might increase the clinical benefits.

This medical research was supported by a grant from the Sociedad Española de Neumología y Cirugía Torácica (SEPAR, 2012), a grant from Asociación Española de Endoscopia Respiratoria (AEER, 2013), and a prize from the Fundació Catalana de Pneumologia (FUCAP, 2014).

## Bibliografía

1. Global Initiative for Asthma guidelines (GINA); 2015. Available from: [www.ginasthma.com](http://www.ginasthma.com) [Online].
2. Torrego A, Solà I, Muñoz AM, Roqué i Figuls M, Yepes-Nuñez JJ, Alonso-Coello P, et al. Bronchial thermoplasty for moderate or severe persistent asthma in adults. *Cochrane Database Syst. Rev.* 2014. <http://dx.doi.org/10.1002/14651858.CD009910.pub2>. Art. No.: CD009910.

3. Daneke CJ, Lombard CM, Dungworth DL, Cox PG, Miller JD, Biggs MJ. Reduction in airway hyperresponsiveness to methacholine by the application of RF energy in dogs. *J Appl Physiol.* 2004;97:1946-53.
4. Pretolani M, Dombret MC, Thabut G, Knap D, Hamidi F, Debray MP, et al. Reduction of airway smooth muscle mass by bronchial thermoplasty in patients with severe asthma. *Am J Respir Crit Care Med.* 2014;190:1452-4.
5. Chakir J, Haj-Salem I, Gras D, Joubert P, Beaudoin ÉL, Biardel S, et al. Effects of bronchial thermoplasty on airway smooth muscle and collagen deposition in asthma. *Ann Am Thorac Soc.* 2015;12:1612-8.
6. Pretolani M, Bergqvist A, Thabut G, Dombret MC, Knapp D, Hamidi F, et al. Effectiveness of bronchial thermoplasty in patients with severe refractory asthma: clinical and histopathologic correlations. *J Allergy Clin Immunol.* 2017;139:1176-85.
7. Mayse M, Laviolette M, Rubin A, Lampron N, Simoff M, Duhamel D, et al. Clinical pearls for bronchial thermoplasty. How I do it. *J Bronchol.* 2007;14:115-23.
8. Langton D, Sha J, Ing A, Fielding D, Thien F, Plummer V. Bronchial thermoplasty: activations predict response. *Respir Res.* 2017;18:134-9.
9. Cox G, Thomson NC, Rubin AS, Niven RM, Corris PA, Siersted HC, et al. AIR Trial Study Group. Asthma control during the year after bronchial thermoplasty. *N Engl J Med.* 2007;356:1327-37.
10. Pavord I, Cox G, Thomson N, Rubin A, Corris P, Niven R, et al. RISA Trial Study Group. Safety and efficacy of bronchial thermoplasty in symptomatic, severe asthma. *Am J Respir Crit Care Med.* 2007;176:1185-91.
11. Castro M, Rubin A, Laviolette M, Fiterman J, De Andrade Lima M, Shah P, et al. AIR2 Trial Study Group. Effectiveness and safety of bronchial thermoplasty in the treatment of severe asthma. A multicenter, randomized, double-blind, sham-controlled clinical trial. *Am J Respir Crit Care Med.* 2010;181:116-24.
12. Wechsler ME, Laviolette M, Rubin AS, Fiterman J, Lapa E, Silva JR, et al. AIR 2 Trial Study Group. Bronchial thermoplasty: long-term safety and effectiveness in patients with severe persistent asthma. *J Allergy Clin Immunol.* 2013;132:1295-302.

Ana María Muñoz-Fernández\*, Ana Rodrigo-Troyano,  
Virginia Pajares, Alfons Torrego

Respiratory Department, Hospital de la Santa Creu i Sant Pau,  
Universitat Autònoma de Barcelona (UAB), Instituto de Recerca  
Biomèdica (IRB) de l'Hospital de la Santa Creu i Sant Pau, Spain

\* Corresponding author.

E-mail address: [amunozf@santpau.cat](mailto:amunozf@santpau.cat) (A.M. Muñoz-Fernández).

<https://doi.org/10.1016/j.arbres.2018.01.021>

0300-2896/

© 2018 SEPAR. Published by Elsevier España, S.L.U. All rights reserved.

## Pembrolizumab-Induced Rhabdomyolysis With Myositis in a Patient With Lung Adenocarcinoma



### Rabdomiolisis con miositis inducida por pembrolizumab en un paciente con adenocarcinoma pulmonar

Dear Editor,

Lung cancer is the leading cause of cancer mortality worldwide. Cytotoxic and platinum-based chemotherapy are the standard first-line treatment for metastatic non-small cell lung cancer (NSCLC) without activating epidermal growth factor receptor (EGFR) and anaplastic lymphoma kinase (ALK) or cytoplasmic c-ros oncogene 1 translocation/re-arrangements.<sup>1</sup> Recently, the deve-

lopment of immune checkpoint inhibitors (ICIs) against modulators including cytotoxic T-lymphocyte-associated protein 4 and programmed cell death protein 1 (PD-1) and its ligand (PD-L1) has created a major paradigm shift in the therapeutic management of metastatic NSCLC.<sup>1</sup> The ICI, pembrolizumab, is a humanized monoclonal antibody against PD-1. The KEYNOTE-024 trial showed that pembrolizumab provided significantly longer progression-free survival and overall survival, with fewer adverse events, than cytotoxic and platinum-based chemotherapy.<sup>2</sup> Compared with cytotoxic or targeted agents, however, ICIs can induce autoimmune-like toxicities known as immune-related adverse events (irAEs) by inducing the infiltration of immune cells in normal tissues<sup>3</sup>; in patients with advanced NSCLC, the common pembrolizumab-induced irAEs are thyroid dysfunction, pneumonitis, and skin reactions.<sup>3,4</sup> Here, we describe a patient with lung adenocarcinoma with rhabdomyolysis and myositis triggered by pembrolizumab treatment, while pembrolizumab rapidly reduced lung tumor size.

The patient is an 83-year-old non-smoking man who was diagnosed with prostate cancer at age 80 years and treated with brachytherapy for 2 years. At age 83 years, he presented with an abnormal chest X-ray (CXR) during routine follow up (Fig. 1A). Chest computed tomography (CT) revealed a 30.5 mm × 30.5 mm mass in the right lower portion of the lung that crossed over into

Abbreviations: AChR, acetylcholine receptor; ALK, anaplastic lymphoma kinase; CK, creatine kinase; CT, computed tomography; CXR, chest X-ray; EGFR, epidermal growth factor receptor; FDG, fluorodeoxyglucose; ICI, immune checkpoint inhibitor; irAE, immune-related adverse event; MG, myasthenia gravis; MRC, medical research council; MuSK, muscle-specific kinase; MRI, magnetic resonance imaging; NSCLC, non-small cell lung cancer; PD-1, programmed cell death protein 1; PD-L1, programmed cell death protein ligand 1.