

Clinical image

Giant Lung Herniation After Minimally Invasive Cardiac Surgery

Hernia pulmonar gigante tras cirugía cardíaca mínimamente invasiva

Blanca Meana*, Daniel Hernandez-Vaquero, Jacobo Silva

Servicio Cirugía Cardíaca, Hospital Universitario Central de Asturias, Oviedo, Asturias, Spain

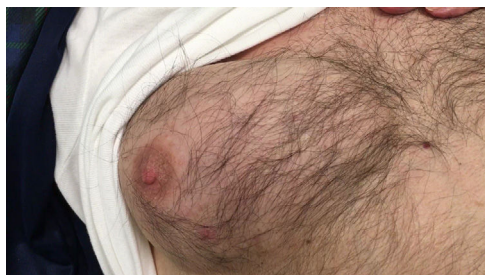


Fig. 1. Giant lung herniation.

Lung hernia is an uncommon entity defined as the protrusion of the pulmonary tissue and pleural membranes beyond the confines of the thoracic cavity through an abnormal opening in the chest wall, diaphragm or mediastinum.^{1,2}

Ten years after undergoing a minimally invasive mitral valve repair through a right minithoracotomy, a 87 year-old man was admitted to the hospital due to an acute exacerbation of his chronic obstructive pulmonary disease. He presented a painless, soft and tender subcutaneous mass over the old surgical scar in the sub-mammmary groove. The mass protruded in a surprising way when

increasing intrathoracic pressure like physical strain or coughing (Fig. 1 and Video).

An inadequate technique to close the thoracic wall is usually the main cause for the presence of post surgical lung hernias. However, this big hernia appeared 10 years after the intervention, which suggests the important role of the constant increase of the intrathoracic pressure due to the patient's pulmonary disease. In this case, the chest wall defect was surgically repaired due to its giant size and respiratory implications. However, the suitable treatment must be considered for each individual case.^{1,2}

Appendix A. Supplementary data, video

Supplementary data associated with this article can be found, in the online version, at [doi:10.1016/j.arbres.2018.01.020](https://doi.org/10.1016/j.arbres.2018.01.020)

References

1. Athanassiadi K, Bagaev E, Simon A, Haverich A. Lung herniation: a rare complication in minimally invasive cardiothoracic surgery. *Eur J Cardiothorac Surg.* 2008;33:774–6.
2. Jiménez Agüero R, Hernández Ortiz C, Izquierdo Elena JM, Cabeza Sánchez R. Hernia pulmonar intercostal espontánea: aportación de un caso. *Arch Bronconeumol.* 2000;36:354–6.

* Corresponding author.

E-mail address: blancameana@gmail.com (B. Meana).