

case. It is important to stress that the first lung function tests were carried out less than a month before surgery and that the patient regained weight after the surgical intervention. Another aspect to be mentioned is that our laboratory uses the ERS Quanjer 1993 lung function reference values⁸ which were validated to patients with a minimum height of 154 cm tall. Since our patient height is only 141 cm tall, her measured values as percent of predicted are globally overestimated and we should focus on the absolute volumes.

This case demonstrates the benefit of surgical reduction of this type of hernia, even in cases of chronic respiratory failure and additional causes for increased surgical risk.

References

1. Gedik E, Tuncer MC, Onat S, Avc AI, Tacy III, Bac B. A review of Morgagni and Bochdalek hernias in adults. *Folia Morphol (Warsz)*. 2011;70:5–12.
2. Arora S, Haji a, Ng P. Adult Morgagni hernia: the need for clinical awareness, early diagnosis and prompt surgical intervention. *Ann R Coll Surg Engl*. 2008;90:694–5.
3. Loong TPF, Kocher HM. Clinical presentation and operative repair of hernia of Morgagni. *Postgrad Med J*. 2005;81:41–4.
4. Bianchi E, Mancini P, De Vito S, Pompili E, Taurone S, Guerrisi I, et al. Congenital asymptomatic diaphragmatic hernias in adults: a case series. *J Med Case Rep*. 2013;7:125.
5. Tone K, Kiryu I, Yoshida M, Tsuboi K, Takagi M, Kuwano K. Morgagni hernia with respiratory failure aggravated by noninvasive positive pressure ventilation: a case report and overview of the literature. *Respir Investig*. 2014;52:203–8.
6. Pfannschmidt J, Hoffmann H, Dienemann H. Morgagni hernia in adults: results in 7 patients. *Scand J Surg*. 2004;93:77–81.
7. Mariela Mirambeaux Villalona R, Barrios Barreto D, Mayoralas Alises S, Díaz-Lobato S. Annals of nursing and practice respiratory failure secondary to long-standing diaphragmatic hernia corrected with noninvasive ventilation. *Ann Nurs Pr*. 2015;2:2–4.
8. Quanjer P, Tasmeling G, Cotes J, Pedersen O, Peslin R, Jernault J-C. Lung volumes and forced ventilatory flows Report Working Party. Standardization of lung function tests. *Eur Respir J*. 1993;6:5–40.

Patrícia Dionísio*, Susana Moreira, Rita Pinto Basto, Paula Pinto

Pulmonology Department, Centro Hospitalar Lisboa Norte, Portugal

* Corresponding author.

E-mail address: patriciadionisio1@gmail.com (P. Dionísio).

<https://doi.org/10.1016/j.arbres.2017.10.001>

0300-2896/

© 2017 SEPAR. Published by Elsevier España, S.L.U. All rights reserved.

Thiamazole-Induced Agranulocytosis Leading to Abscessus Pneumonia-Rare, But Challenging



Agranulocitosis inducida por tiamazol que lleva a absceso pulmonar. Un reto infrecuente

Dear Editor,

The antithyroid agents (carbimazole, methimazole, thiamazole, propylthiouracil and benzylthiouracil) are the drug class that is associated with a high risk of agranulocytosis. Isolated severe neutropenia or agranulocytosis, defined as an absolute neutrophil count of less than $0.5 \times 10^9/L$ occurring in a subject treated with antithyroid agents should be considered as a drug-induced agranulocytosis, until proven otherwise. Agranulocytosis is rare and may develop in 0.2–0.5% patients using antithyroid drug therapy.¹ The clinical evidence of infectious complications associated with antithyroid-drug-induced (ATD) agranulocytosis is usually symptomatology in fever (92%) and sore throat (85%), pharyngitis (46%), acute tonsillitis (38%), pneumonia (15%) and urinary tract infection (8%).²

A 61-year-old, Caucasian female was admitted to the emergency department with complaints with fever up to 39 °C, chills and cough and general weaknesses which started a day after discharge from other hospital (hematology department) where she was treated for gastric pain and neutropenia (leukocyte was $1.2 \times 10^9/L$, neutrophils $0.03 \times 10^9/L$) induced by thiamazole. She was afebrile. Chest X ray was normal. She recovered successfully after 10th days with granulocyte colony-stimulating factor and discharged from hospital. Previously, she has been with hyperthyroidism for 21 years, six month ago before hospital admission her therapy was changed to thiamazole.

On admission to our hospital, her vital signs were within normal limits, except for a temperature of 38.8 °C and respiratory rate 22/min. Physical examination revealed atonic bilateral equal air entry with no added rhonchi or wheezing. Cardiovascular and neurological examinations revealed no abnormalities. The abdomen was soft and non-tender, without palpable visceromegaly. Her initial chest X-ray showed a multifocal abscessing pneumonia (Fig. 1A). CT was immediately performed which confirmed multifocal abscessus in lungs (Fig. 1B). Admission labs revealed hemoglobin 12.5 gm/dL, white count $8.8 \times 10^9/L$, neu-

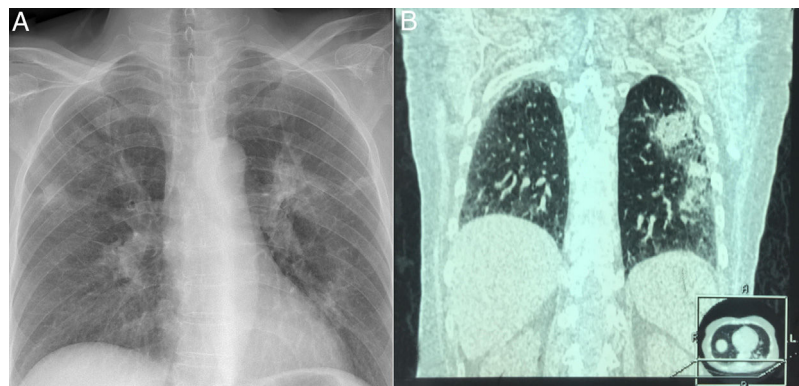


Fig. 1. Chest X ray showing abscessus pneumonia (A); HRCT demonstrated extensive pulmonary abscessus over both the lungs (B).

trophil 5.59×10^9 , platelets count $197 \times 10^9/L$. Her serum sodium levels were 138 mEq/dL, and the blood urea nitrogen (BUN) and creatinine values were 20 mg/dL and 0.9 mg/dL respectively. C reactive protein (CRP) was 252 ng/ml, while procalcitonin was 78.7 $\mu\text{g/L}$. Arterial blood gas showed a pH of 7.30 and PaO_2 of 60 mmHg, PCO_2 46 mmHg, SaO_2 90%.

Initially, the patient was started empirically with broad-spectrum antibiotics: Vancomycin 1 g/12 h, Amikacin 1 g/12 g and Orvaryl 500 mg/8 h. Blood culture, throat culture, blood fungal culture, acid-fast bacillus blood culture, and urine culture were all negative. Despite antibiotics therapy, patient was febrile up to 38°C , and in the absence of adequate laboratory as well as radiologically answer, therapy was changed into Meropenem 1 g/12 h and Orvaryl 500 mg/8 h. On third day, patient was afebrile and feeling better. Her CRP was 9.7 ng/ml, white count $11.2 \times 10^9/L$, platelets $210 \times 10^9/L$. During the following days, the patient's condition, and laboratory parameters improved in parallel with the neutrophil count. She received above mentioned therapy for fourteen days after she was discharged in good condition and radiological finding. She was released from the hospital with recommended Propylthiouracil 50 mg twice daily. She was regularly checked up by endocrinologist and pulmonologist with no relapse of disease.

Antithyroid drugs, especially thioamides—including propylthiouracil, methimazole and carbimazole—have adverse hematological effects, ranging from mild leukopenia to agranulocytosis and aplastic anemia. Agranulocytosis, defined as a marked decrease in the number of granulocytes, frequently $<500/\mu\text{L}$, is a rare complication. Fever and sore throat are common symptoms of antithyroid drug induced agranulocytosis.³ Patients with an absolute neutrophil count $<100/\mu\text{L}$ tend to have a greater risk of infectious and fatal complications than do patients with a neutrophil count $>100/\mu\text{L}$. The mortality rate is greater in patients aged ≥ 65 years than in those aged <65 years.⁴

The lungs are the most common organ to be infected in febrile neutropenic patients. The chest radiograph is the standard initial investigation to look for pulmonary changes, but its sensitivity has been shown to be very low. High resolution computed tomography (HRCT) chest can detect the abnormality with a high degree of accuracy, as well as differentiate between different types of infections.⁵ It is extremely useful in early detection or exclusion of a focus of infection and characterization of the focus. Exact etiological diagnosis is not possible in most of the cases, but identification of broad category of infective causes itself is very important for the appropriate therapy. Previous studies have proven that the most common cause of febrile condition is *Pseudomonas aeruginosa*.⁵

Our case was different from previous described in literature, in its beginning, but similar in good prognosis after granulocyte colony-stimulating factor and empirical antibiotic therapy. However, the recovery time in our cases was slightly longer than in previous cases (14 vs. 6.8 days).⁶ Nowadays, more people are undergoing surgical treatment as a permanent solution.⁷

In conclusion, ATD-induced agranulocytosis is rare, but the severity of this possibly life-threatening condition means its management is essential to a good prognosis. Our case suggests that patients with antithyroid drug-induced agranulocytosis who present with severe infections should be treated empirically with broad-spectrum antibiotics with antipseudomonal activity.

Alternative way in patients with hyperthyroidisms is surgery or radioactive iodine which seem to be effective options to restore an euthyroid state. In fact, radioactive iodine was demonstrated as a successful option, with 88.8% of patients experiencing euthyroidism after treatment.

References

- Vicente N, Cardoso L, Barros L, Carrilho F. Antithyroid drug-induced agranulocytosis: state of the art on diagnosis and management. *Drugs RD*. 2017;17:91–6.
- Li KL, Huang HS, Wang PW, Lin JD, Juang JH, Liu RT, et al. Agranulocytosis associated with anti-thyroid drugs in patients with Graves' thyrotoxicosis: report of 11 patients. *Chang Gung Med J*. 1991;14:168–73.
- Cooper DS. Antithyroid drugs. *N Engl J Med*. 1984;311:1353–62.
- Pearce SH. Spontaneous reporting of adverse reactions to carbimazole and propylthiouracil in the UK. *Clin Endocrinol (Oxf)*. 2004;61:589–94.
- Andersohn F, Konzen C, Garbe E. Systematic review: agranulocytosis induced by nonchemotherapy drugs. *Ann Intern Med*. 2007;146:657–65.
- Tamai H, Mukuta T, Matsubayashi S, Fukata S, Komaki G, Kuma K, et al. Treatment of methimazole-induced agranulocytosis using recombinant human granulocyte colony stimulating factor (rhG-CSF). *J Clin Endocrinol Metab*. 1993;77:1356–60.
- Jukić T, Stančić J, Petric V, Kusić Z. Radioiodine versus surgery in the treatment of Graves' hyperthyroidism. *Lijec Vjesn*. 2010;132:355–60.

Biljana Lazovic^{a,c,*}, Vuk Andrejevic^a, Aleksandar Ivanovic^a, Vladimir Zucic^{b,c}

^a University Clinical Center "Zemun", Belgrade, Serbia

^b Clinic for Lung Diseases, Clinical Center of SERBIA, Belgrade, Serbia

^c School of Medicine, University of Belgrade, Serbia

* Corresponding author.

E-mail address: lazovic.biljana@gmail.com (B. Lazovic).

<https://doi.org/10.1016/j.arbres.2017.10.005>

0300-2896/

© 2017 SEPAR. Published by Elsevier España, S.L.U. All rights reserved.

Expresión de PD-L1 en muestras de cáncer pulmonar no microcítico obtenidas por EBUS-TBNA



PD-L1 Expression in a Non-Small Cell Lung Cancer Specimen Obtained by EBUS-TBNA

Estimado Director:

El cáncer pulmonar es la primera causa de muerte por cáncer en el mundo, tanto en hombres como mujeres, dando cuenta de 1,6

millones de muertes anualmente, y en Chile representa la segunda causa de muerte por cáncer^{1,2}. El cáncer pulmonar no microcítico (CPNM) corresponde al 85% de los cánceres pulmonares y desafortunadamente en hasta el 80% de los casos se diagnostica en etapas avanzadas, requiriendo terapia sistémica³. El tratamiento de estos pacientes ha tenido avances significativos en las últimas décadas con la aparición de terapias dirigidas contra mutaciones específicas de las células tumorales (conocidas como *targeted therapies*) y más recientemente con la inmunoterapia.

Una de las inmunoterapias más utilizadas son los anticuerpos monoclonales contra PD-1 o PD-L1. Su acción se basa en la capaci-