

Clinical Image

Upper Airway Small Cell Carcinoma

Carcinoma de células pequeñas en vías respiratorias superiores

Chia-Chun Liu^a, Chang-Che Wu^b, Bor-Hwang Kang^{a,c,*}

^a Department of Otorhinolaryngology, Kaohsiung Veterans General Hospital, Kaohsiung, Taiwan

^b Department of Pathology and Lab Medicine, Kaohsiung Veterans General Hospital, Kaohsiung, Taiwan

^c Department of Otorhinolaryngology, Tri-Service General Hospital, National Defense Medical Center, Taipei, Taiwan

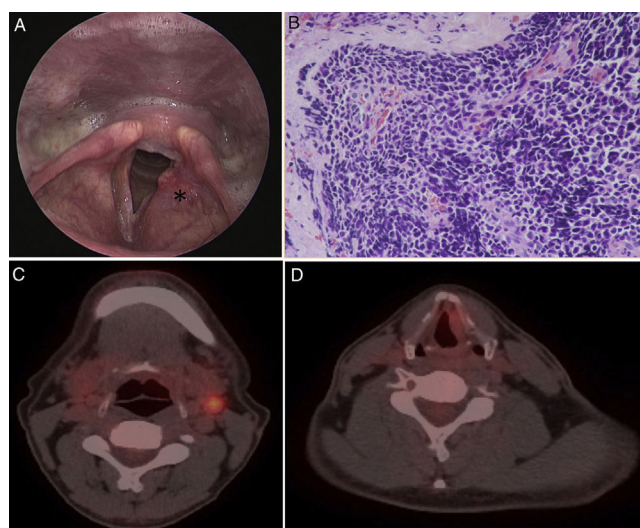


Fig. 1. Indirect laryngoscopy (A) shows submucosal bulging mass (asterisk) over the left false cord. Photomicrograph (H&E, $\times 400$) (B) shows small cells with hyperchromatic nuclei and scant cytoplasm. Nuclear moulding and crush artefact are present. PET/CT (C, D) showed increased 18F-FDG uptake in the left supraglottis (SUVmax = 2.3) and left neck lymph nodes (SUVmax = 4.0).

A 50-year-old man, a known heavy smoker for more than 20 years, presented to our clinic with hoarseness for the last 2 months. Indirect laryngoscopy showed a bulging mass over the left false cord (Fig. 1A) without vocal cord immobility. Biopsy of the mass was performed and the pathology diagnosis was small cell neuroendocrine carcinoma (SCNC) (Fig. 1B). Chest CT scan, abdomen sonography, and whole body bone scan disclosed no distant metastasis. However, head and neck CT scan suggested an equivocal node over left level II neck, which was confirmed to be metastatic node by PET scan (Fig. 1C, D) and sono-guided fine needle aspiration.

SCNC is aggressive malignancy which occurs mostly in the lung. Extrapulmonary SCNC is relatively rare and encompasses 2.5%–5% of the all SCNCs.¹ Neuroendocrine neoplasms are the most common non-squamous malignancies of the larynx with a predilection for the supraglottis. The survival rate of laryngeal SCNC is similar to pulmonary SCNC, which remains dismal. The extent of the disease rather than tumour size is the independent prognostic factor for survival. Definitive chemoradiotherapy is currently the best form of treatment.² Surgery is only reserved for loco-regional recurrence without evidence of distant metastasis.

References

1. Renner G. Small cell carcinoma of the head and neck: a review. *Semin Oncol.* 2007;34:3–14.
2. van der Laan TP, Plaat BE, van der Laan BF, Halmos GB. Clinical recommendations on the treatment of neuroendocrine carcinoma of the larynx: a meta-analysis of 436 reported cases. *Head Neck.* 2015;37:707–15.

* Corresponding author.

E-mail address: bhkang@vghks.gov.tw (B.-H. Kang).