

histopathological examination revealed a small-round cell tumor (Fig. 1C). The immunohistochemistry study was positive to CD99 (Fig. 1D), synaptophysin and vimentine, favoring the diagnosis of Askin's tumor.

The patient had a hospital-acquired respiratory infection with associated respiratory failure and died, without starting any anti-neoplastic therapy.

Askin's tumors are rare tumors that develops in the soft tissue of the thoracic wall and mainly occurs in children, adolescents and young Caucasian adults. Reported cases in patients over 60 years are extremely rare.¹

Our patient presented some clinical signs and symptoms commonly seen in Askin's tumors, as dyspnea, cough, chest pain, chest wall mass and anorexia. Fever and superficial lymph nodes are other clinical findings reported.^{2–4} Typical radiographic findings include a large chest mass that can be associated with pleural effusion. Rib destruction is frequent. Pulmonary parenchymal involvement, hilar and mediastinal adenopathies are other associated findings.^{2,5}

If Askin's tumor is suspected, diagnostic confirmation is obtained by histological and immunohistochemical analysis, as was performed in our case. Histological features include small round malignant cells that contain scant cytoplasm. Like the other Ewing's family tumors, Askin's tumor may express neural markers as CD99, neuron-specific enolase, vimentin and Leu7 (CD57). Tumor cells may also be positive for synaptophysin. Diagnostic confirmation can be alternatively made by detection of the typical cytogenetic mutation, a reciprocal translocation between chromosomes 11 and 22 (t[11;22](q24;q12)).⁵

The ideal treatment of Askin's tumor should be multimodal, and included a combination of neoadjuvant chemotherapy, radical surgical resection and adjuvant chemotherapy and radiotherapy,^{3,4} however, metastases are frequently seen at the time of diagnosis, making impossible the optimal treatment. Local recurrences after treatment are also frequently seen, reason why Askin's tumor is generally associated with poor prognosis and short survival.

Adverse prognostic factors reported include metastatic disease at diagnosis, larger tumor volume, presence of pleural effusion and

poor response to neoadjuvant chemotherapy.^{4,6} Some studies showed older age to be associated with poorer outcome but other studies showed no association between age and survival.⁶ Our patient presented several adverse prognostic factors, as metastatic disease and large tumor volume, and we believe that his advanced age had an important contribution to the rapidly fatal evolution after the diagnosis. Early clinical suspicion is crucial, and Askin's tumor must be kept in mind in the differential diagnosis of small round cell malignant tumors of the thorax, even in elderly.

Bibliografía

- Gedik GK, Sari O, Altinok T, Tavli L, Kaya B, Kara PO. Askin's Tumor in an adult: case report and findings on 18F-FDG PET/CT. *Case Rep Med.* 2009;2009:517329.
- Askin FB, Rosai J, Sibley RK, Dehner LP, McAlister WH. Malignant small cell tumor of the thoracopulmonary region in childhood: a distinctive clinicopathologic entity of uncertain histogenesis. *Cancer.* 1979;43:2438–51.
- Zhang KE, Lu R, Zhang P, Shen S, Li X. Askin's tumor: 11 cases and a review of the literature. *Oncol Lett.* 2016;11:253–6.
- Laskar S, Nair C, Mallik S, Bahl G, Pai S, Shet T, et al. Prognostic factors and outcome in Askin-Rosai tumor: a review of 104 patients. *Int J Radiat Oncol Biol Phys.* 2011;79:202–7.
- Murphey MD, Senchak LT, Mambalam PK, Logie CI, Klassen-Fischer MK, Kransdorf MJ. From the radiologic pathology archives, Ewing sarcoma family of tumors: radiologic-pathologic correlation. *Radiographics.* 2013;33:803–31.
- Scurr M, Judson I. How to treat the Ewing's family of sarcomas in adult patients. *Oncologist.* 2006;11:65–72.

Liliana Ribeiro^{a,*}, Dulce Apolinário^a, Joana Cunha^b,
Fernando Guimarães^b

^a Department of Pulmonology, Centro Hospitalar de Trás-os-Montes e Alto Douro, Vila Real, Portugal

^b Department of Internal Medicine, Centro Hospitalar de Trás-os-Montes e Alto Douro, Vila Real, Portugal

* Corresponding author.

E-mail address: liliana.sc.ribeiro@hotmail.com (L. Ribeiro).

<http://dx.doi.org/10.1016/j.arbres.2017.03.024>
0300-2896/

© 2017 SEPAR. Published by Elsevier España, S.L.U. All rights reserved.

Kaposi Sarcoma and Lung Transplant: Two Case Reports



Sarcoma de Kaposi y trasplante pulmonar: dos casos clínicos

Dear Editor,

Solid organ transplant recipients have an increased risk of developing malignancies, particularly lung transplant recipients, being one of the leading causes of morbidity and mortality.^{1,2} Certain viral infections are related with the development of tumours, both in immunocompetent and immunosuppressed patients.^{1,4} In the latter, the permanent state of immunosuppression, makes them more susceptible to new infections or reactivations^{1,3} such as by human herpesvirus 8 (HHV-8), which is associated with Kaposi Sarcoma (KS) and can manifest in very different ways,^{3,4} as it will be described.

The first case refers to a 63 years old male patient, former smoker, submitted to bilateral pulmonary transplant (BPT) when he was 61 years old. Eleven months after transplant, on a routine visit, two small purpuric skin lesions in the patient's chest were identified. He was referred to the Dermatology outpatient department and clinical

vigilance was decided. Five months later, due to progression of the skin lesions, (Fig. 1a), he was submitted to cutaneous biopsy whose pathology revealed morphological features and HHV-8 positive cells, compatible with KS, and its digestive tract involvement was excluded. Meanwhile, he showed functional decline and the diagnosis of bronchiolitis obliterans was made, leading to changes in his immunosuppression from mycophenolate mofetil 1250 mg bid to everolimus 0.5 mg bid. Afterwards, he presented clinical worsening with dyspnoea, bilateral pulmonary infiltrates and respiratory failure without response to non-invasive ventilation, all portrayed as a possible pulmonary involvement by KS, associated with transplant rejection (Fig. 1b). The patient died two days after these symptoms began, without having started specific therapy for KS.

The second case describes a 35 years old male patient with bronchiectasis of unknown aetiology, submitted to BPT at the age of 30. Regarding post-transplant complications, the authors emphasise acute rejection with progression to bronchiolitis obliterans with functional stability without respiratory failure. He begun immunosuppression with everolimus 0.5 mg bid and tacrolimus 4.5 mg bid. Fifty months after transplant, he was hospitalized for both prostatitis and acute cholecystitis. During that period the patient presented

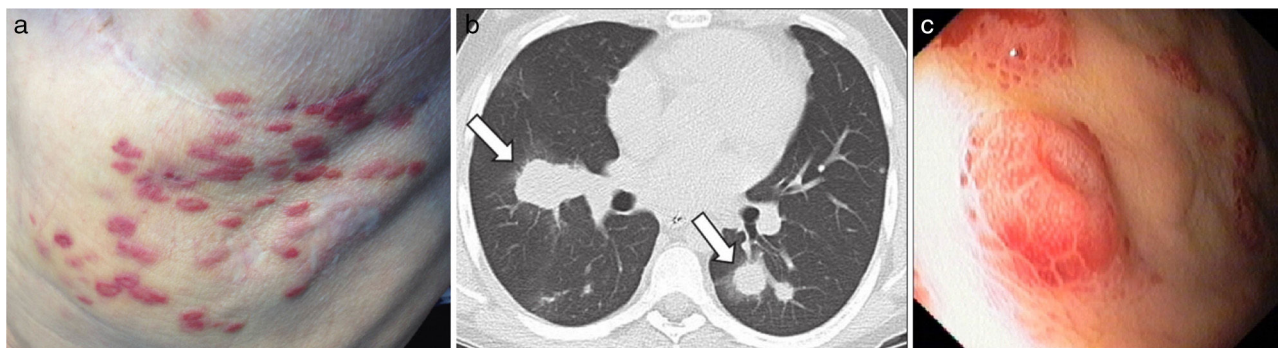


Fig. 1. (a) KS skin lesions, (b) pulmonary involvement by KS and (c) KS lesions dispersed in the patient's stomach.

severe anaemia (haemoglobin 6.8 g/dL) and he underwent endoscopic study which revealed multiple, vascular, round and elevated lesions dispersed in the stomach, suggestive of KS (Fig. 1c). The histological examination confirmed this suspicion after the identification of positive cells to HHV-8 and its serology was negative. Few days later, the patient died after the onset intra-abdominal sepsis.

KS in lung transplant patients has been rarely described in literature, contrary to other solid organ recipients.^{2,4} Different clinical expressions and severity can occur, but usually they are aggressive, commonly involve skin and visceral organs^{3,4} and time from transplantation to diagnosis can vary widely (3–124 months).³ KS related to immunosuppression usually disappears with mTOR inhibitors⁵ or with modification, reduction or cessation of immunosuppressive drugs, which in lung transplant patients is not recommendable due to loss of the graft,³ making their therapeutic approach a challenge. Unfortunately, clinical deterioration in both patients did not allow us to start specific therapy for KS.

Funding

None to declare.

Conflict of Interests

The authors declare that there is no conflict of interests directly or indirectly related to the contents of the manuscript.

Acknowledgements

The authors are grateful to the staff of the pulmonology department and all physicians at Centro Hospitalar São João involved in these two cases.

Bibliografía

1. Krynitz B, Edgren G, Lindelof B, Baecklund E, Brattstrom C, Wilczek H, et al. Risk of skin cancer and other malignancies in kidney, liver, heart and lung transplant recipients 1970 to 2008 – a Swedish population-based study. *Int J Cancer*. 2013;132:1429–38.
2. Martinu T, Haden DW, Reidy MF, Palmer SM. Disseminated kaposi sarcoma in a lung transplant recipient with pulmonary, pleural, and cutaneous involvement. *Chest*. 2006; 130(4.MeetingAbstracts):332S-a-332S.
3. Antman K, Chang Y. Kaposi's sarcoma. *N Engl J Med*. 2000;342:1027–38.
4. Sathy SJ, Martinu T, Youens K, Lawrence CM, Howell DN, Palmer SM, et al. Symptomatic pulmonary allograft Kaposi's sarcoma in two lung transplant recipients. *Am J Transpl*. 2008, September;8:1951–6.
5. Lund MB, Paulsen V, Aukrust P. Intestinal Kaposi sarcoma in a lung transplant recipient: therapy with mammalian target of rapamycin inhibitor and immunosuppression reduction. *J Heart Lung Transpl*. 2013;32:376–7.

Leonor Meira*, Carla Damas

Serviço de Pneumologia, Centro Hospitalar São João, Oporto, Portugal

* Corresponding author.

E-mail address: lo.meira@gmail.com (L. Meira).

<http://dx.doi.org/10.1016/j.arbres.2017.04.001>
0300-2896/

© 2017 SEPAR. Published by Elsevier España, S.L.U. All rights reserved.

Síndrome de Richter con extensa afectación extranodal pleural aislada: importancia de la PET/TC



Richter Syndrome With Extensive Isolated Pleural Extranodal Involvement: The Importance of PET/CT Imaging

Estimado Director:

El síndrome de Richter (SR) consiste en una transformación de una leucemia linfática crónica (LLC) en un agresivo linfoma difuso de células B grandes (LDCBG), una variedad de linfoma no Hodgkin de rápido crecimiento y mal pronóstico. El SR complica la evolución de un 5-10% de pacientes con LCC y clínicamente suele mani-

festarse en forma de adenopatías, esplenomegalia y aparición o empeoramiento de síntomas «B» (fiebre, sudoración nocturna, pérdida de peso)¹. La tomografía por emisión de positrones/tomografía computarizada (PET/TC) es una potente herramienta diagnóstica híbrida muy útil en el estudio de los pacientes con SR, al facilitar la planificación y la obtención con otras técnicas de muestras histológicas de las lesiones que presentan mayor metabolismo^{2,3}.

Presentamos el caso de una mujer de 74 años diagnosticada de una LLC en 2009 que consultó en Urgencias de nuestro hospital por disnea progresiva, molestias torácicas y febrícula de dos semanas de evolución. La radiografía de tórax reveló un abundante derrame pleural derecho que condicionaba un desplazamiento del mediastino hacia el lado contralateral y una atelectasia secun-